

# Embryology and Anatomy of the Ophthalmic Artery

Masaki Komiyama, M.D.

Osaka City General Hospital

Osaka, Japan

COI: nothing to declare

ABC-WIN seminar at Val d'Isère, January 13, 2019

# Contents of Today's Talk

---

Embryology of the ophthalmic artery

its origin, courses, and variations

Anatomy of the ophthalmic artery

Especially, anastomoses between ophthalmic artery and ECA branches

# Embryology of the ophthalmic artery

**Misconception** among neuroradiological fields

2019 © ABC - WIN Seminar. All rights reserved - Any reproduction even in part is prohibited.

2019 © ABC - WIN Seminar. All rights reserved - Any reproduction even in part is prohibited.

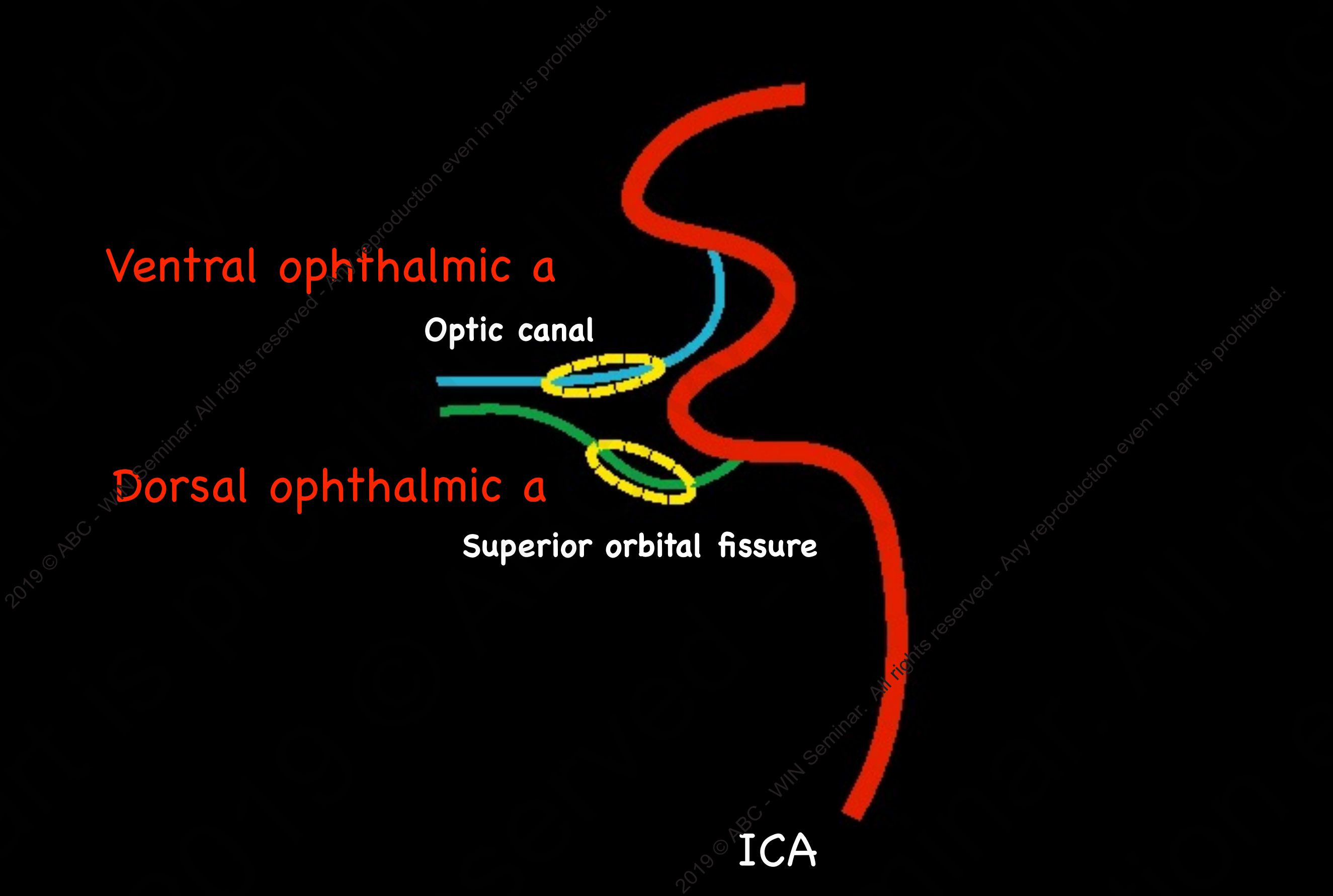
Ventral ophthalmic a

Optic canal

Dorsal ophthalmic a

Superior orbital fissure

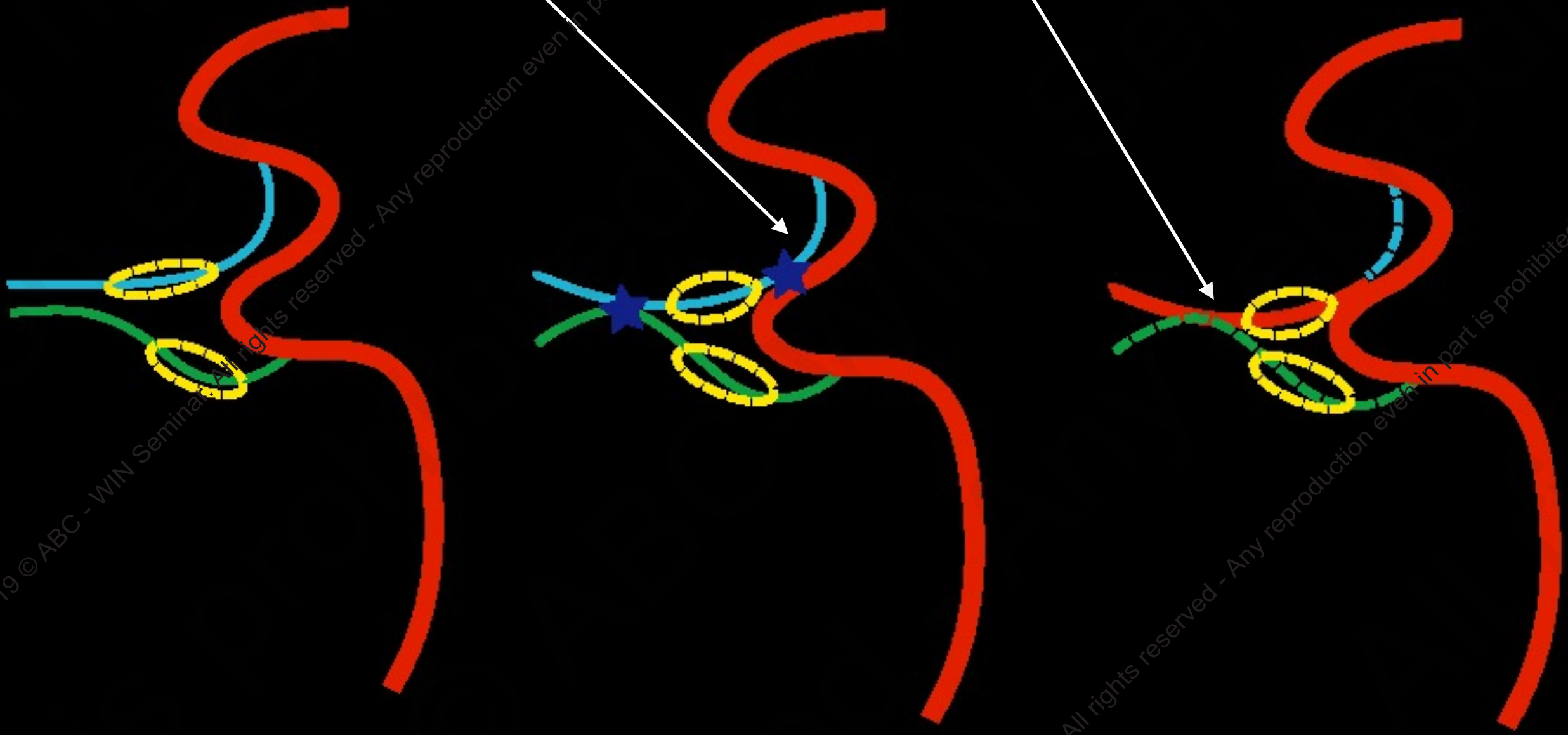
ICA





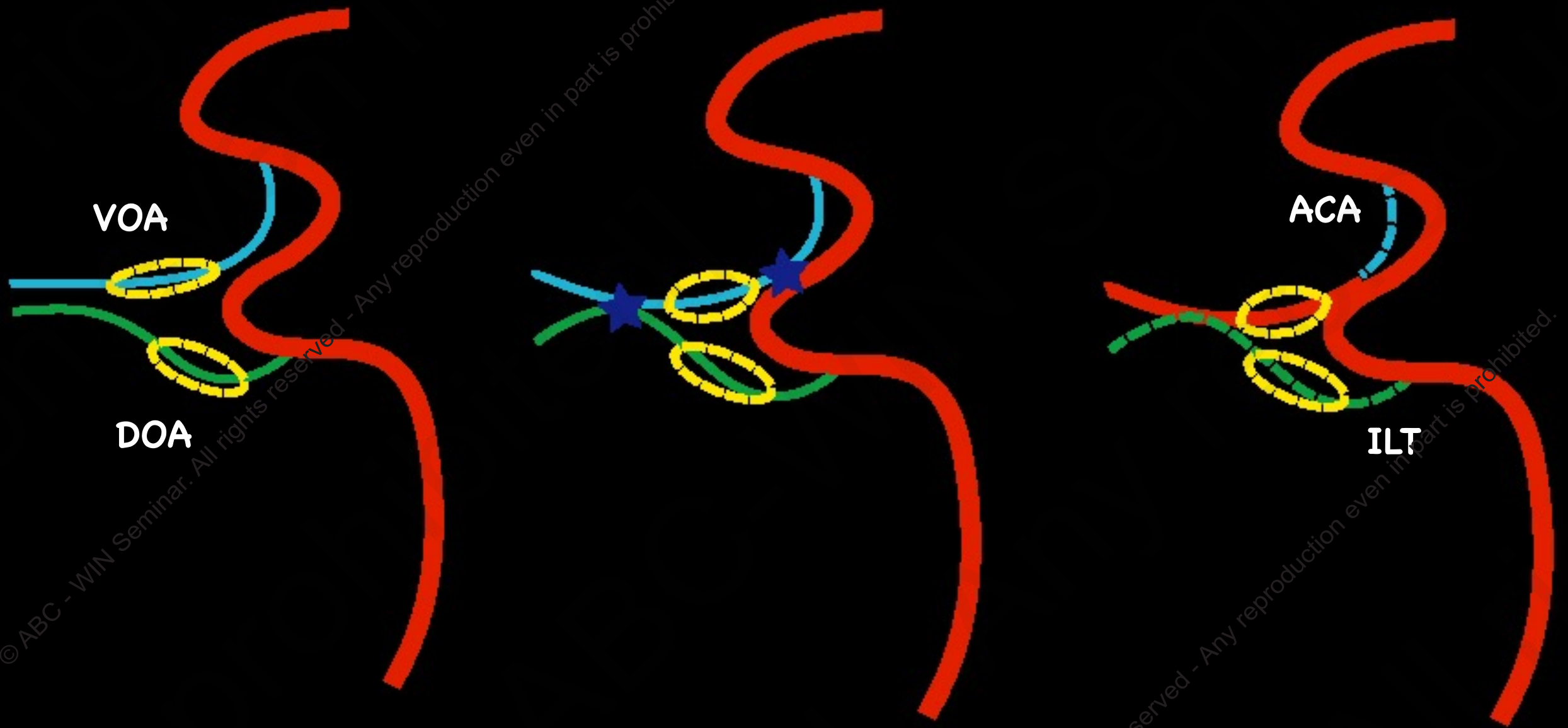
caudal migration

primitive ophthalmic artery



2019 © ABC - WIN Seminar. All rights reserved - Any reproduction even in part is prohibited.

2019 © ABC - WIN Seminar. All rights reserved - Any reproduction even in part is prohibited.

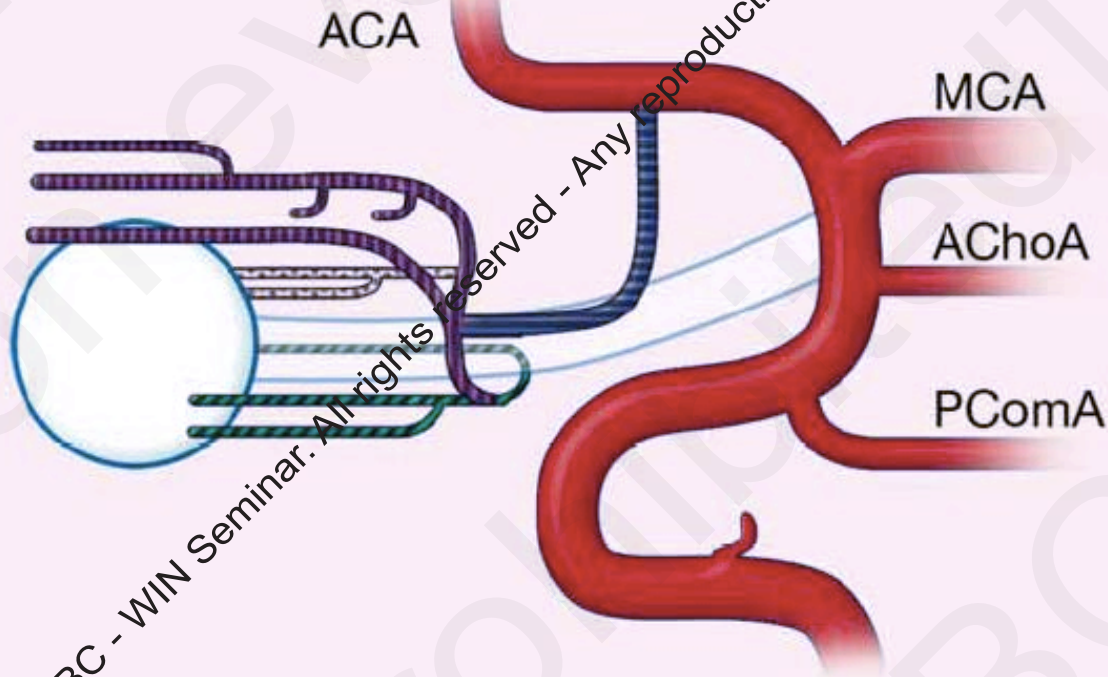


Lasjaunias P: 1977

ACA (A1) origin ophthalmic a is a remnant of ventral ophthalmic a while ILT origin ophthalmic a is a remnant of dorsal ophthalmic a.

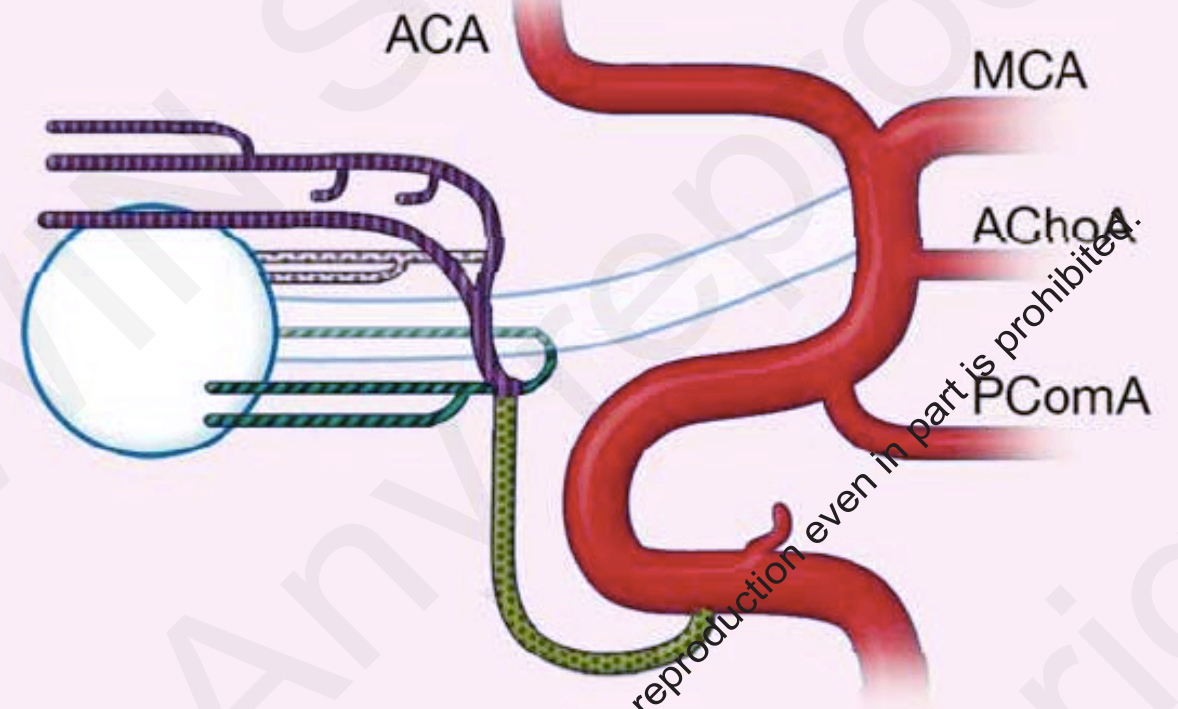
**H**

OA from ACA



**G**

OA from cavernous ICA



Gregg L, 2016 (Johns Hopkins Group)

- ACA origin Oph a → recurrent branch of primitive olfactory artery
- ILT origin Oph a → lateral branch of primitive maxillary artery

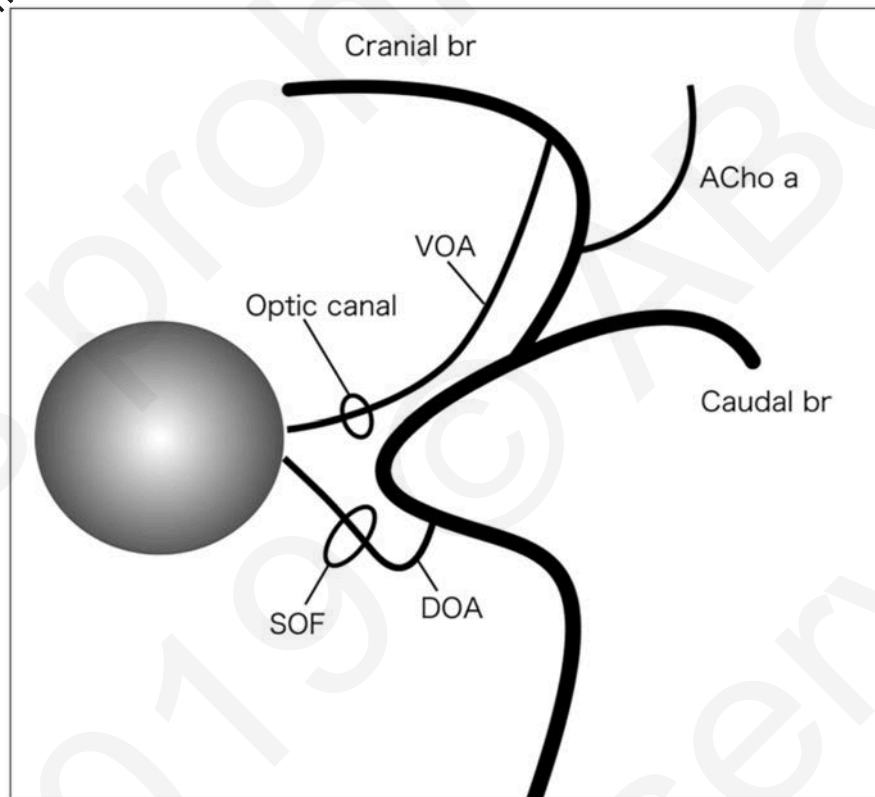


Letter to the Editor

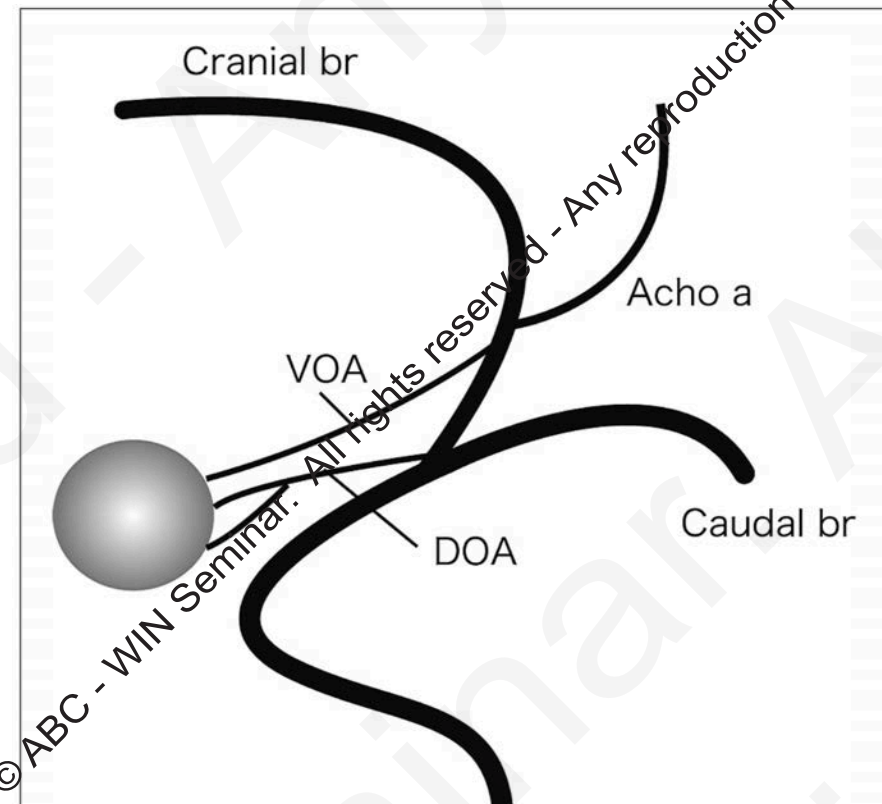
# Embryology of the Ophthalmic Artery: a Revived Concept

M. KOMIYAMA

Department of Neurosurgery, Osaka City General Hospital; Osaka Japan




Lasjaunias P



Padgett DH

2019 © ABC - WIN Seminar. All rights reserved - Any reproduction even in part is prohibited.

2019 © ABC - WIN Seminar. All rights reserved - Any reproduction even in part is prohibited.



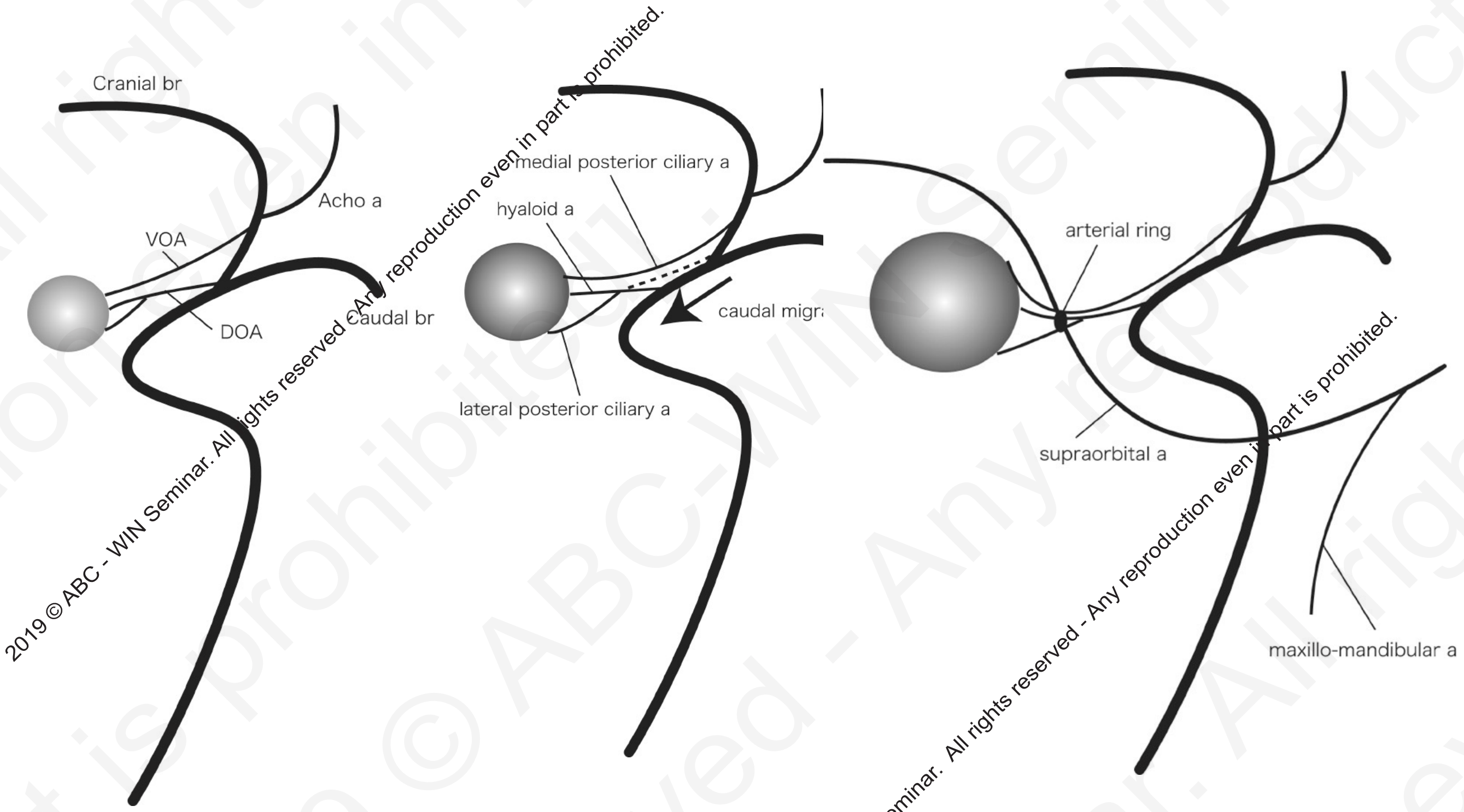
Dorcas Hager Padgett (1906-1973)

VOA: ventral ophthalmic artery  
 DOA: dorsal ophthalmic artery

Padgett DH, 1948

2019 © ABC - WIN Seminar. All rights reserved. Any reproduction even in part is prohibited.

2019 © ABC - WIN Seminar. All rights reserved. Any reproduction even in part is prohibited.



Cranial br  
 Acho a  
 VOA  
 DOA  
 Caudal br

medial posterior ciliary a  
 hyaloid a  
 caudal migr  
 lateral posterior ciliary a

arterial ring  
 supraorbital a  
 maxillo-mandibular a

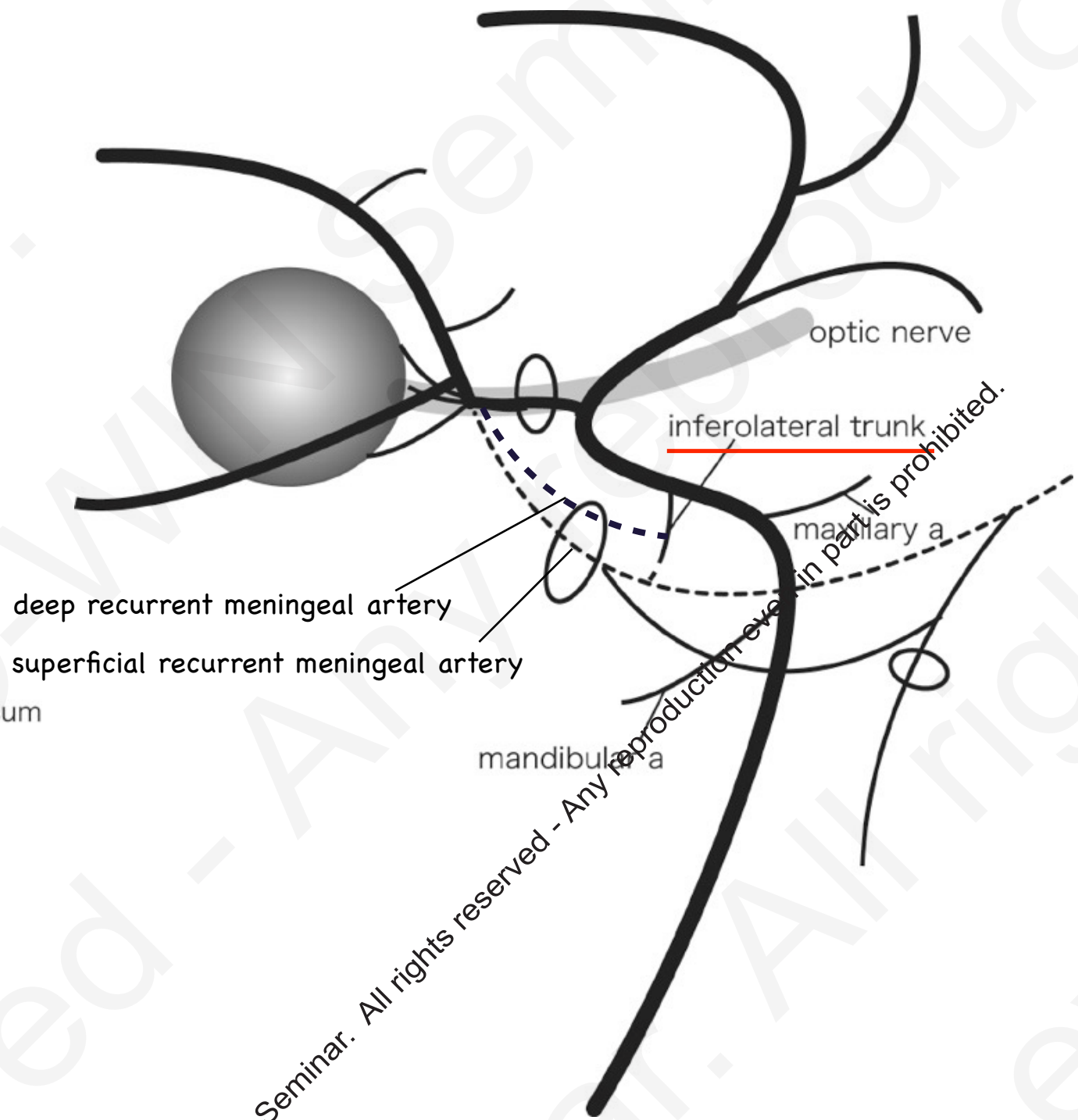
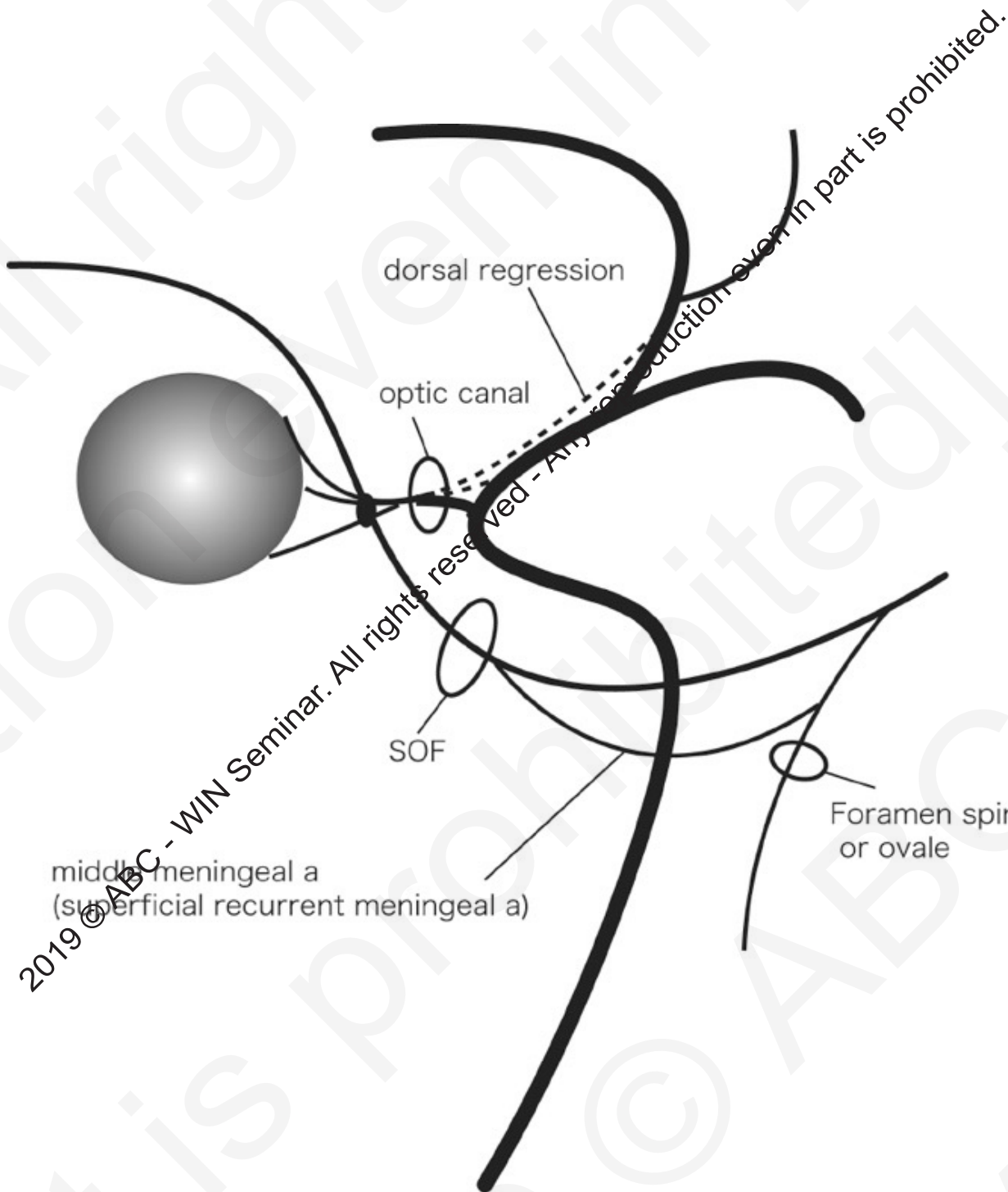
**VOA: ventral ophthalmic artery**  
**DOA: dorsal ophthalmic artery**

Padget DH, 1948

Komiyama M: letter. Interventional Neuroradiol 2009

2019 © ABC - WIN Seminar. All rights reserved. Any reproduction even in part is prohibited.





**Inferolateral trunk (ILT) is not the dorsal ophthalmic artery.**

# Why are there conflicting explanations on the development of the ophthalmic artery?

Few embryonic studies of the ophthalmic artery in human

Uncertain role of primitive maxillary artery (Sabin)

No animal embryological data on ventral/dorsal ophthalmic arteries

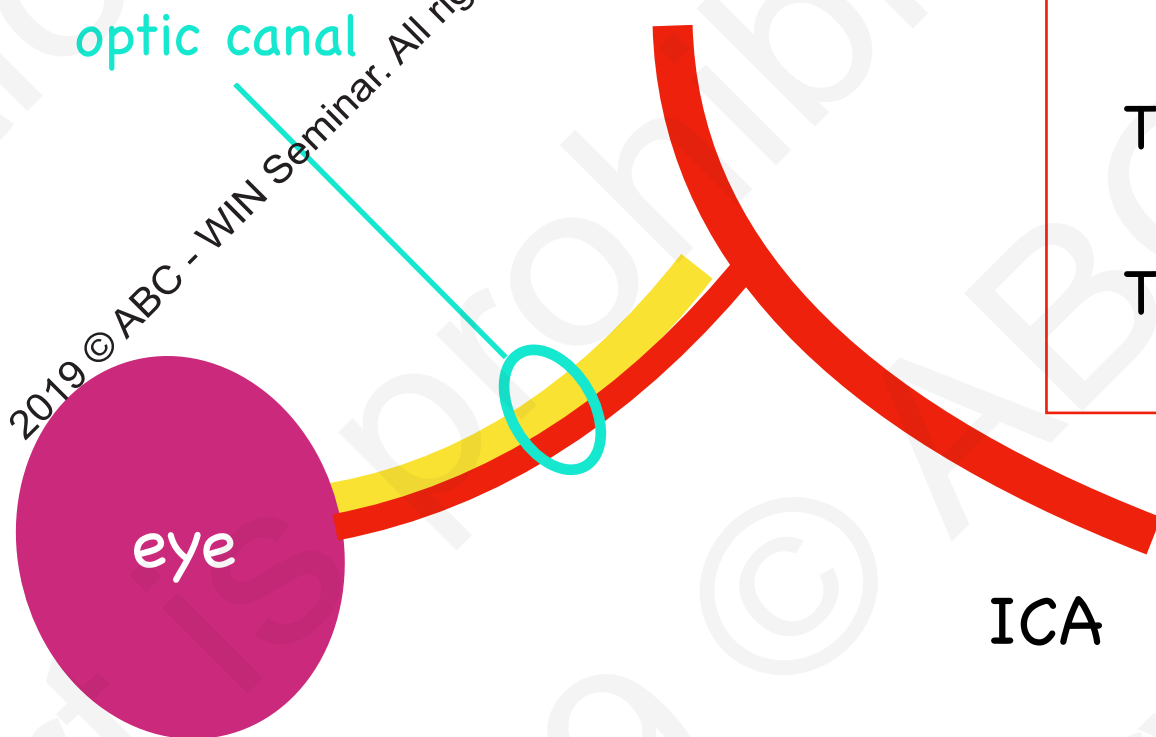
Is embryology of the animals' and humans' eyes the same? **yes, same!**

---

We have to speculate the embryology of the ophthalmic artery with these limited data



# Embryology of Blood Supply to the Eye



At the beginning of development, **all vertebrates have primitive Oph a of ICA origin.**

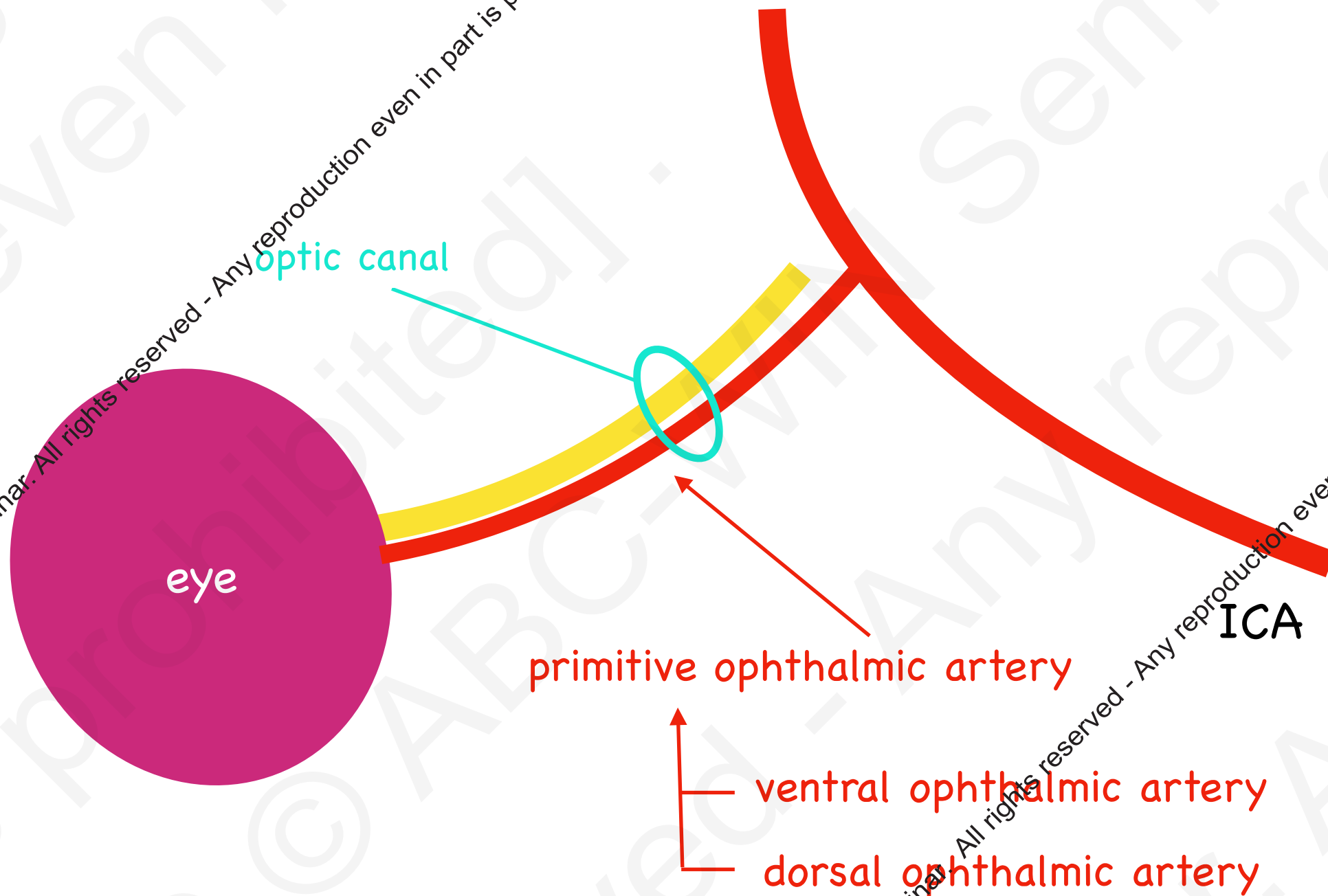
Primitive Oph a runs through the **optic canal.**

Then, **regression** of some segments follows.

This induces (coincides with) **collateral formation.**

Basic arterial supply to the eye

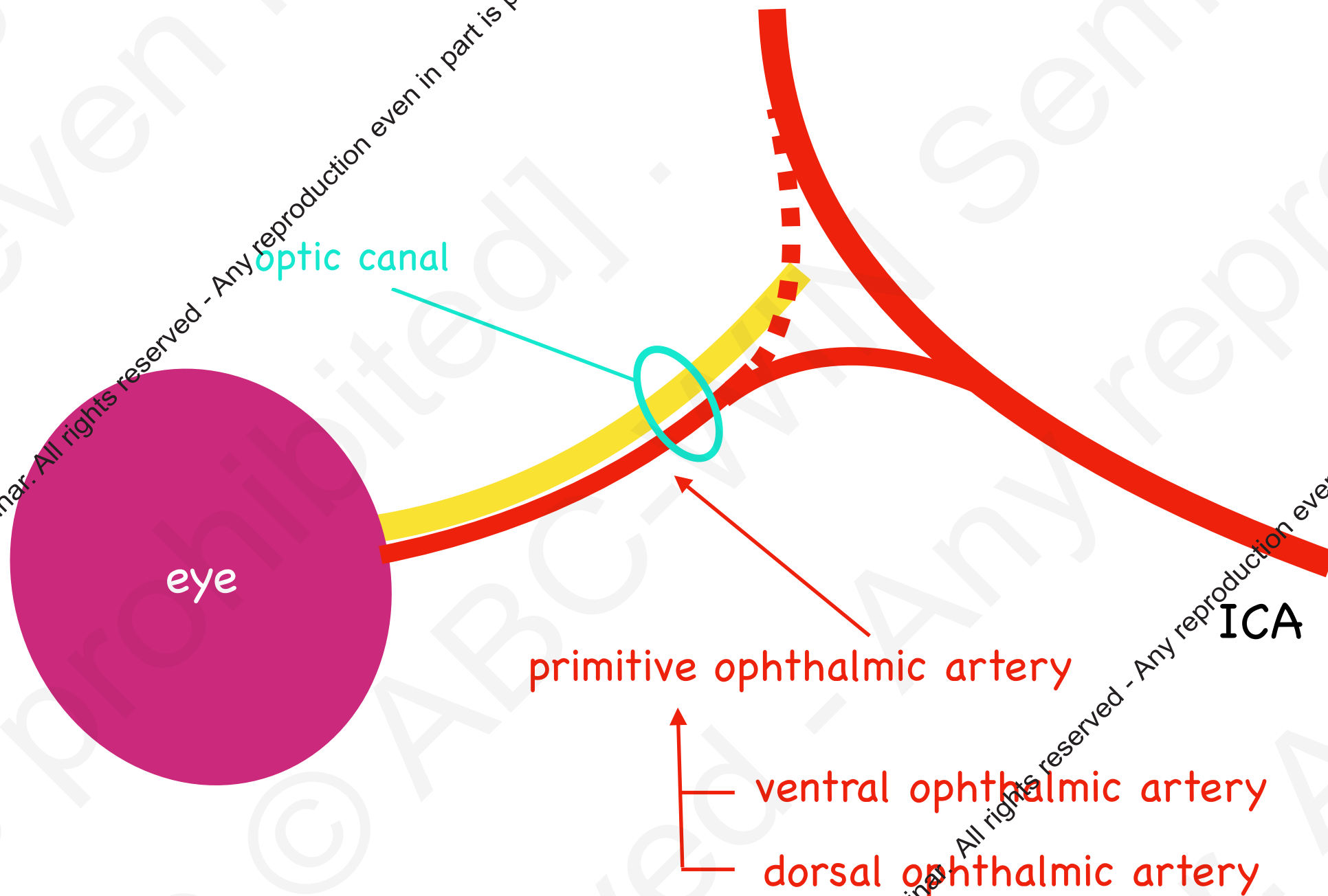
# Embryology of Blood Supply to the Eye



2019 © ABC - WIN Seminar. All rights reserved - Any reproduction even in part is prohibited.

2019 © ABC - WIN Seminar. All rights reserved - Any reproduction even in part is prohibited.

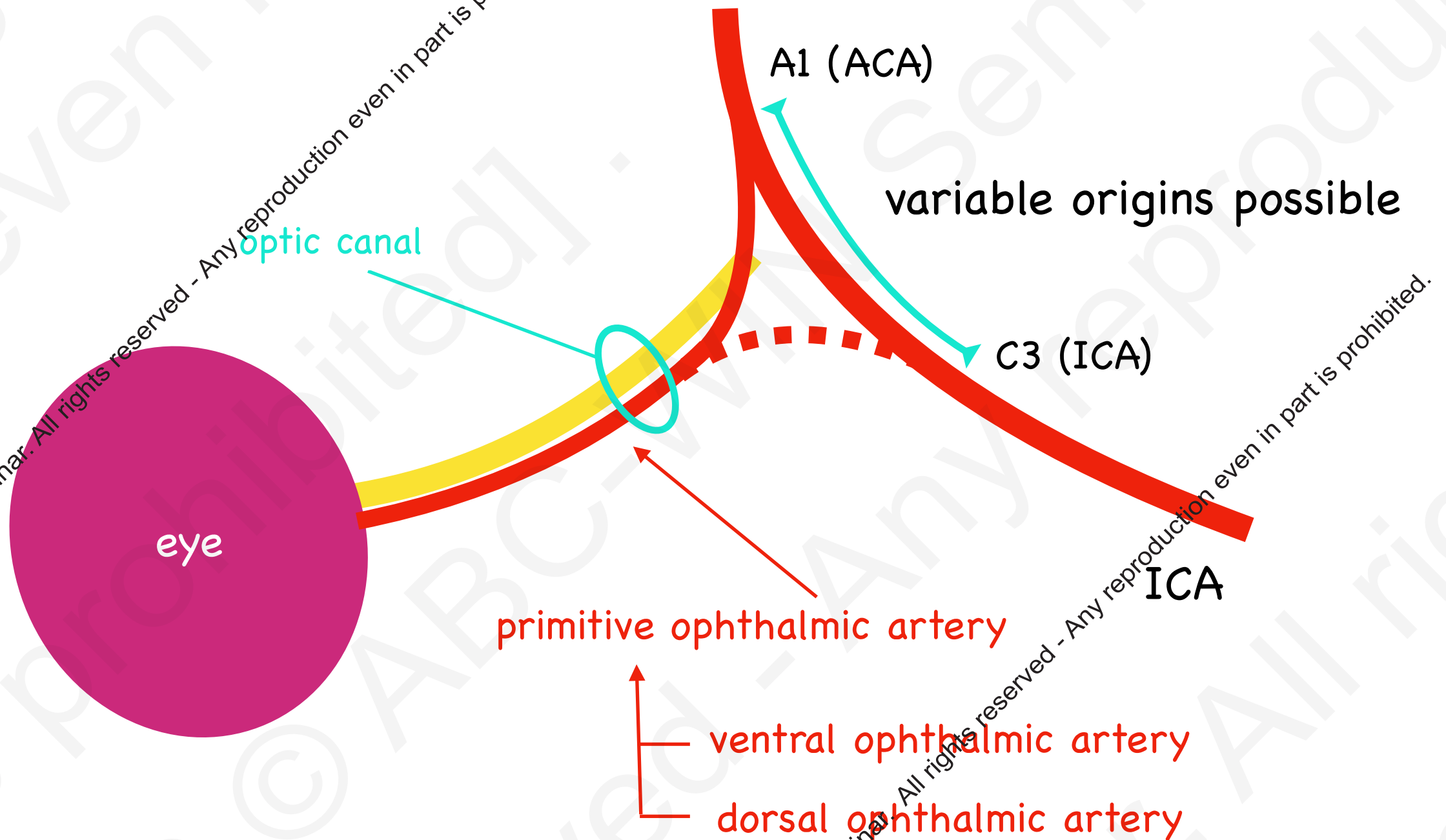
# Embryology of Blood Supply to the Eye



2019 © ABC - WIN Seminar. All rights reserved - Any reproduction even in part is prohibited.

2019 © ABC - WIN Seminar. All rights reserved - Any reproduction even in part is prohibited.

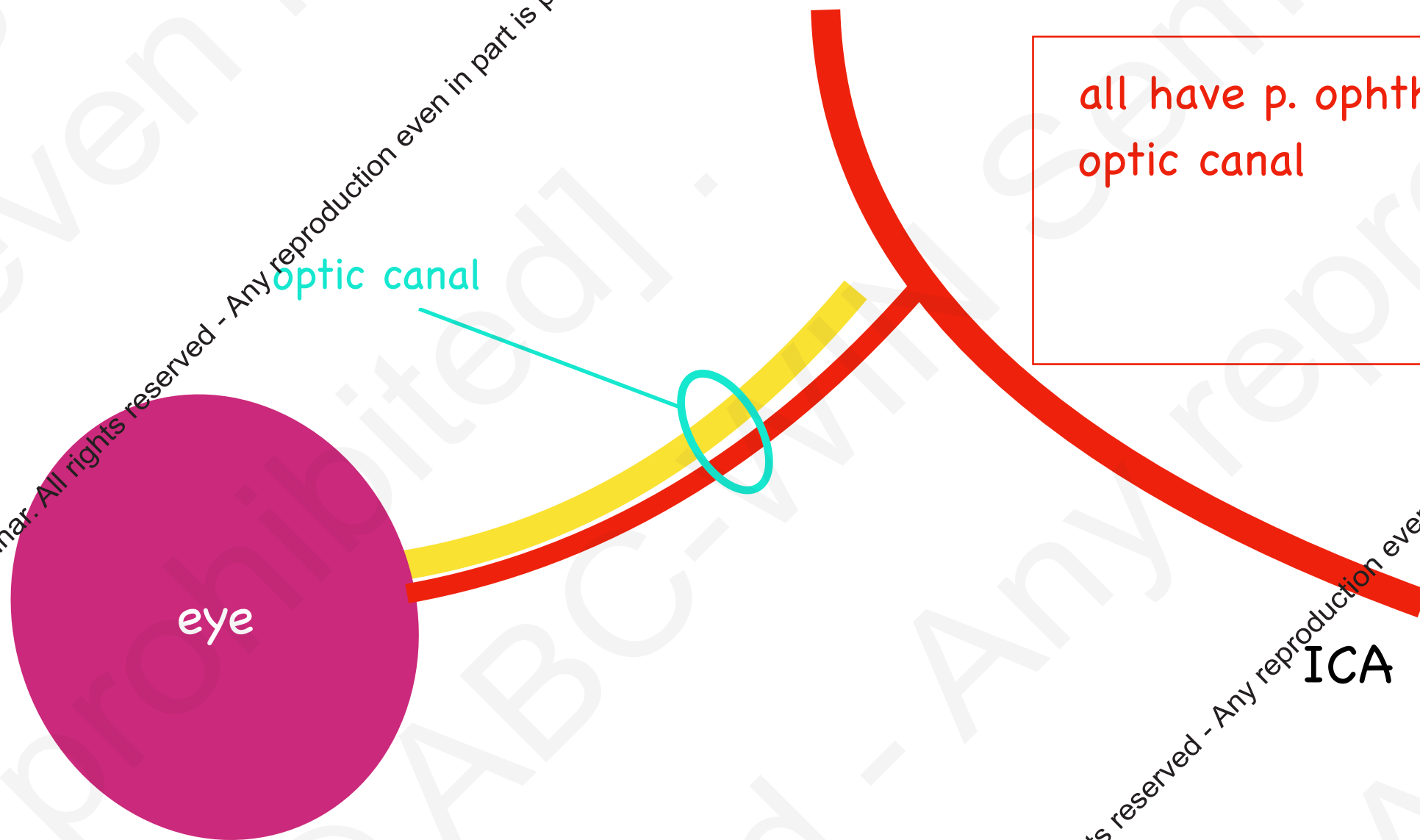
# Embryology of Blood Supply to the Eye



2019 © ABC - WIN Seminar. All rights reserved - Any reproduction even in part is prohibited.

2019 © ABC - WIN Seminar. All rights reserved - Any reproduction even in part is prohibited.

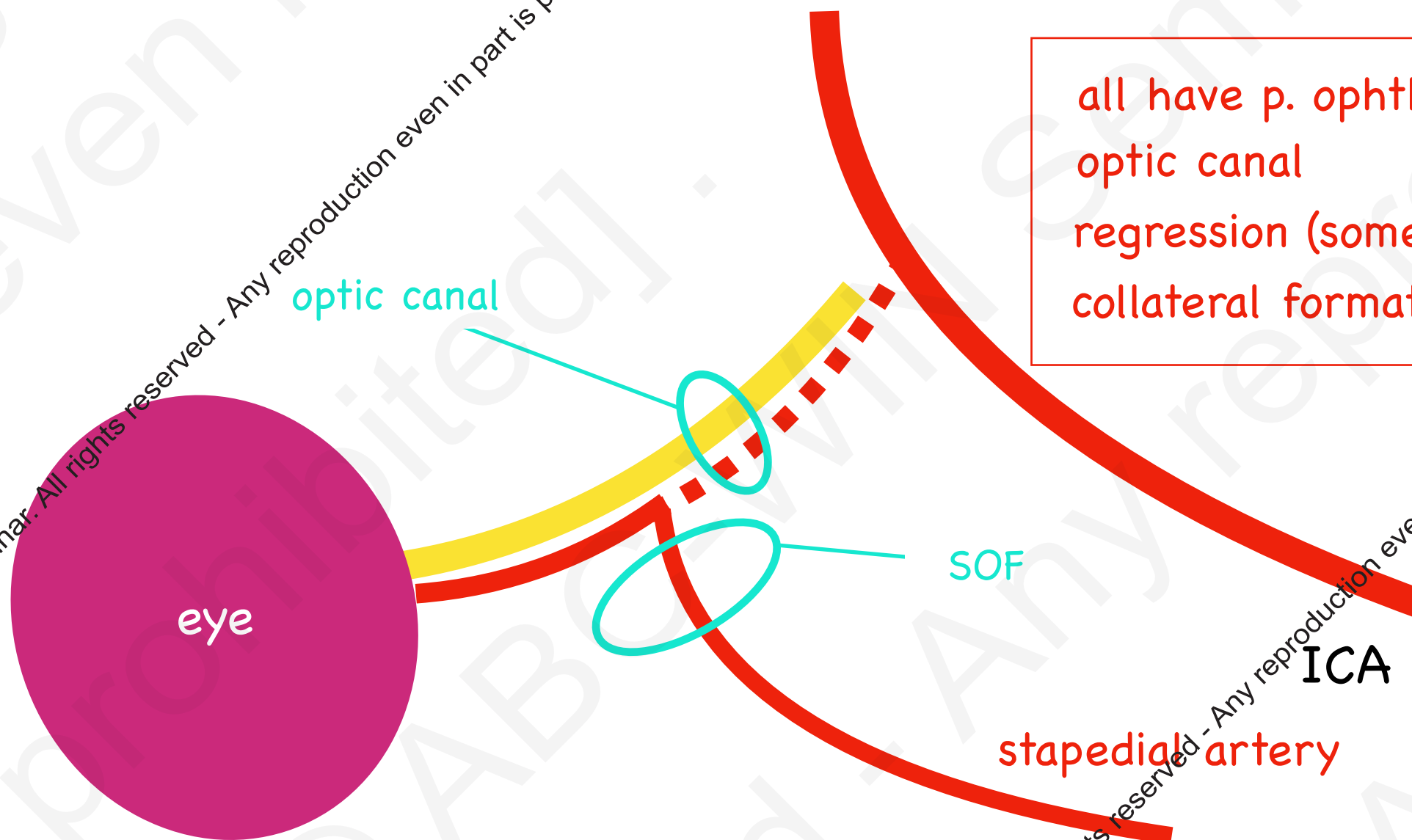
# Embryology of Blood Supply to the Eye



2019 © ABC - WIN Seminar. All rights reserved - Any reproduction even in part is prohibited.

2019 © ABC - WIN Seminar. All rights reserved - Any reproduction even in part is prohibited.

# Embryology of Blood Supply to the Eye



## Regression

Pr. maxillary (pre-mandibular) a  
Pr. ventral ophthalmic a  
Pr. dorsal ophthalmic a

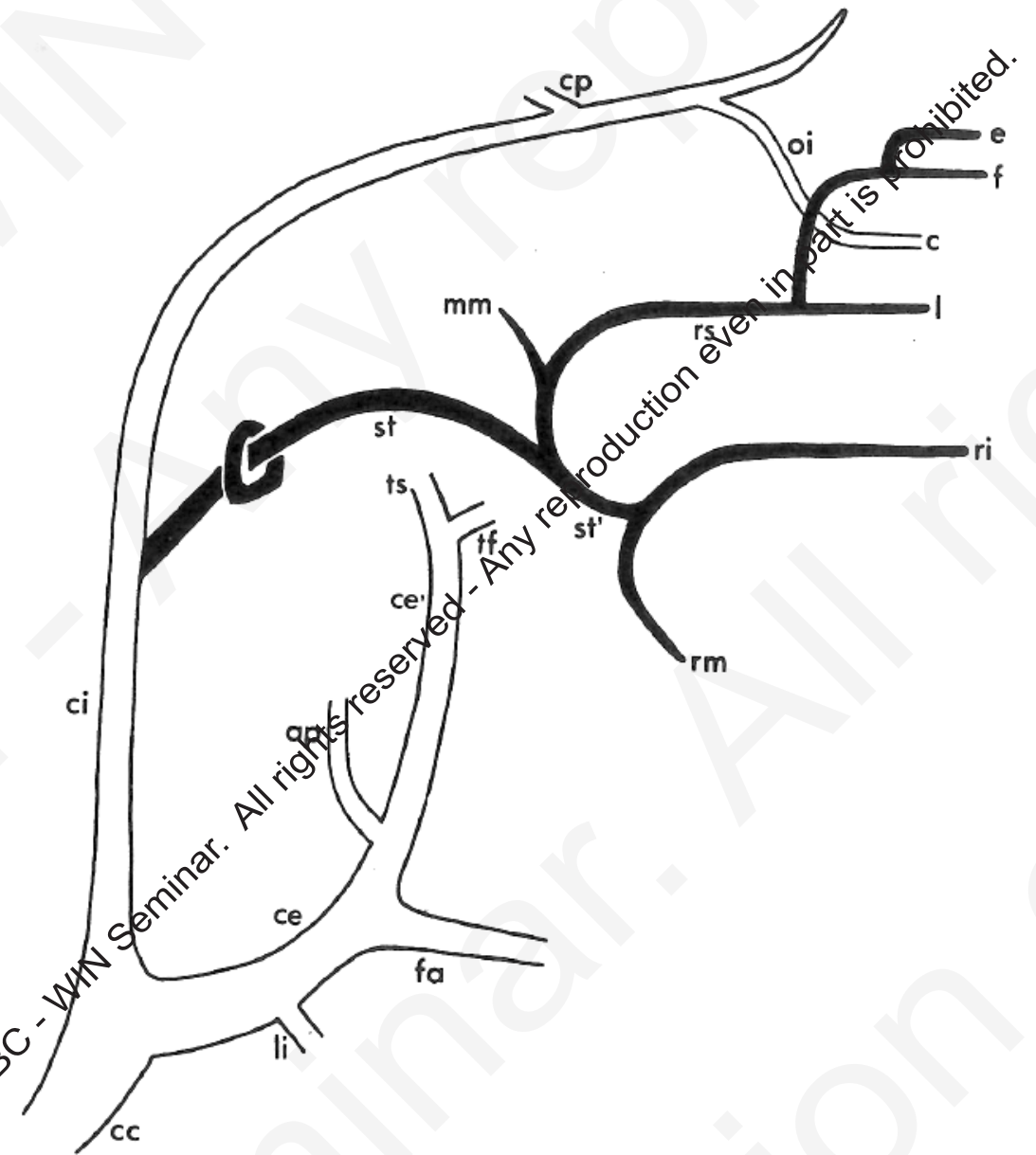
Collaterals are all of stapedial artery origin.  
Probably, not of the p. maxillary artery origin.

# The Cephalic Arterial System in Insectivores, Primates, Rodents and Lagomorphs, with Special Reference to the Systematic Classification

J. BUGGE

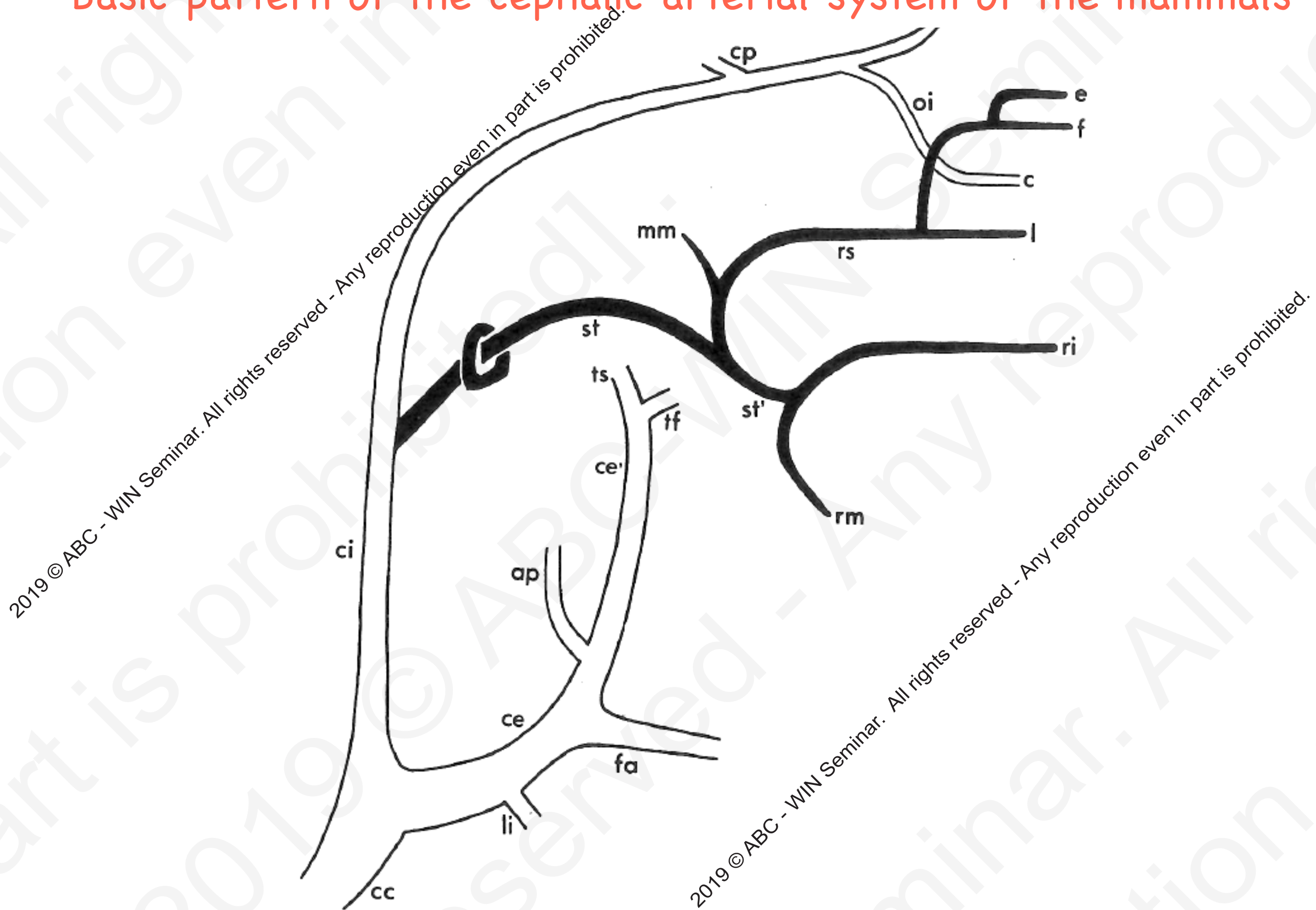
Department of Anatomy, The Royal Dental College,  
Aarhus (Denmark)

1974



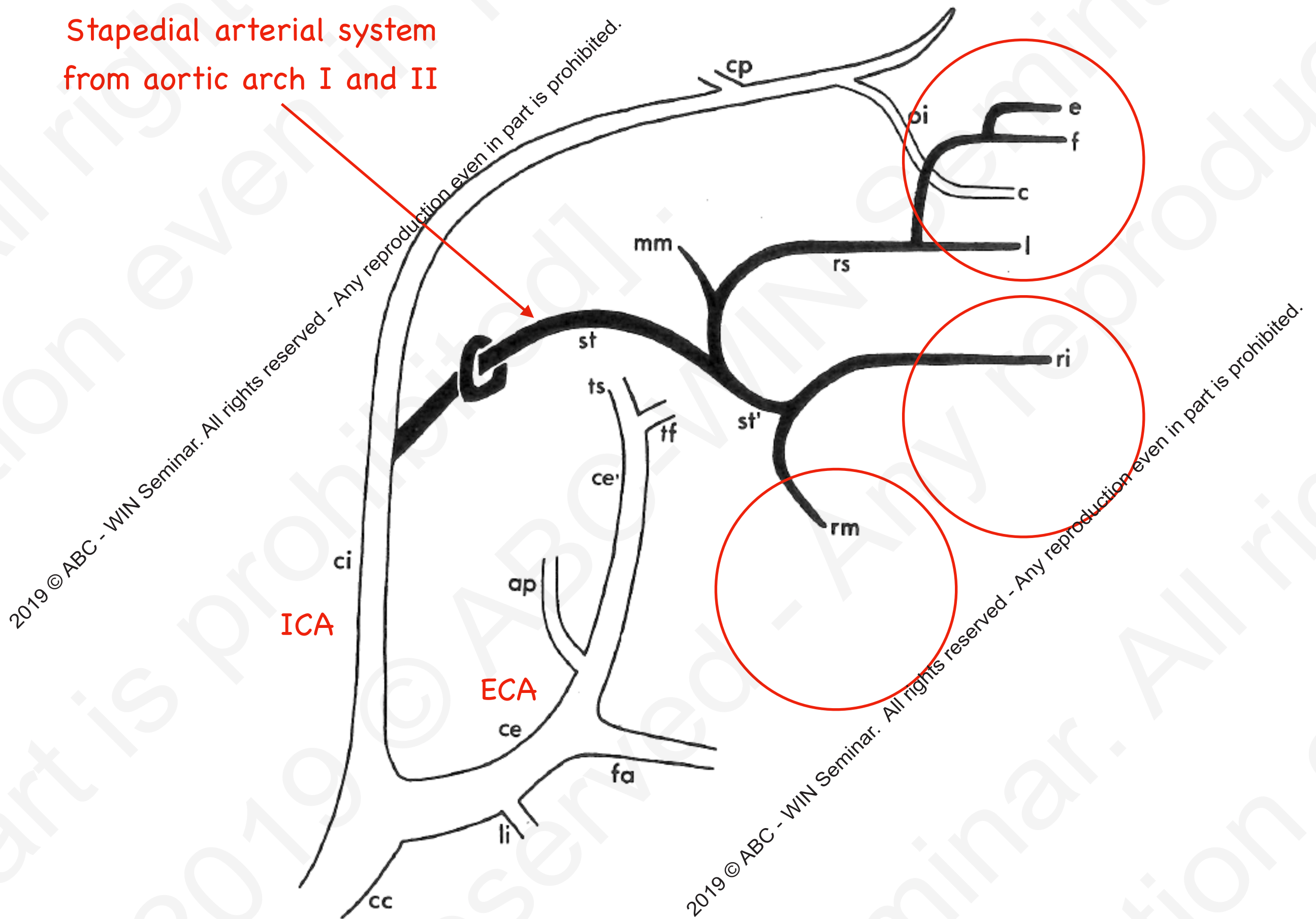


# Basic pattern of the cephalic arterial system of the mammals





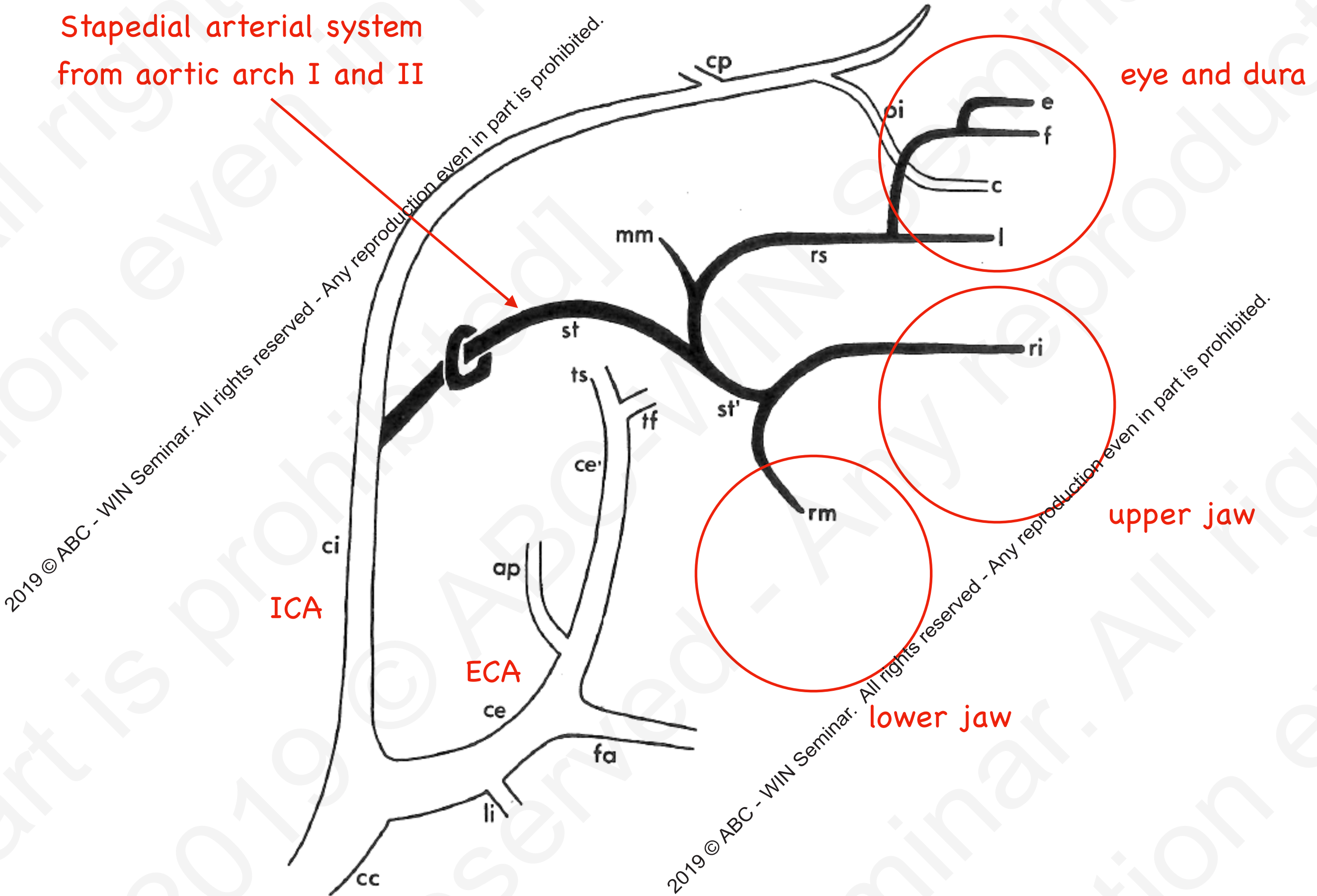
Stapedial arterial system  
from aortic arch I and II



2019 © ABC - WIN Seminar. All rights reserved - Any reproduction even in part is prohibited.

2019 © ABC - WIN Seminar. All rights reserved - Any reproduction even in part is prohibited.

Stapedial arterial system  
from aortic arch I and II

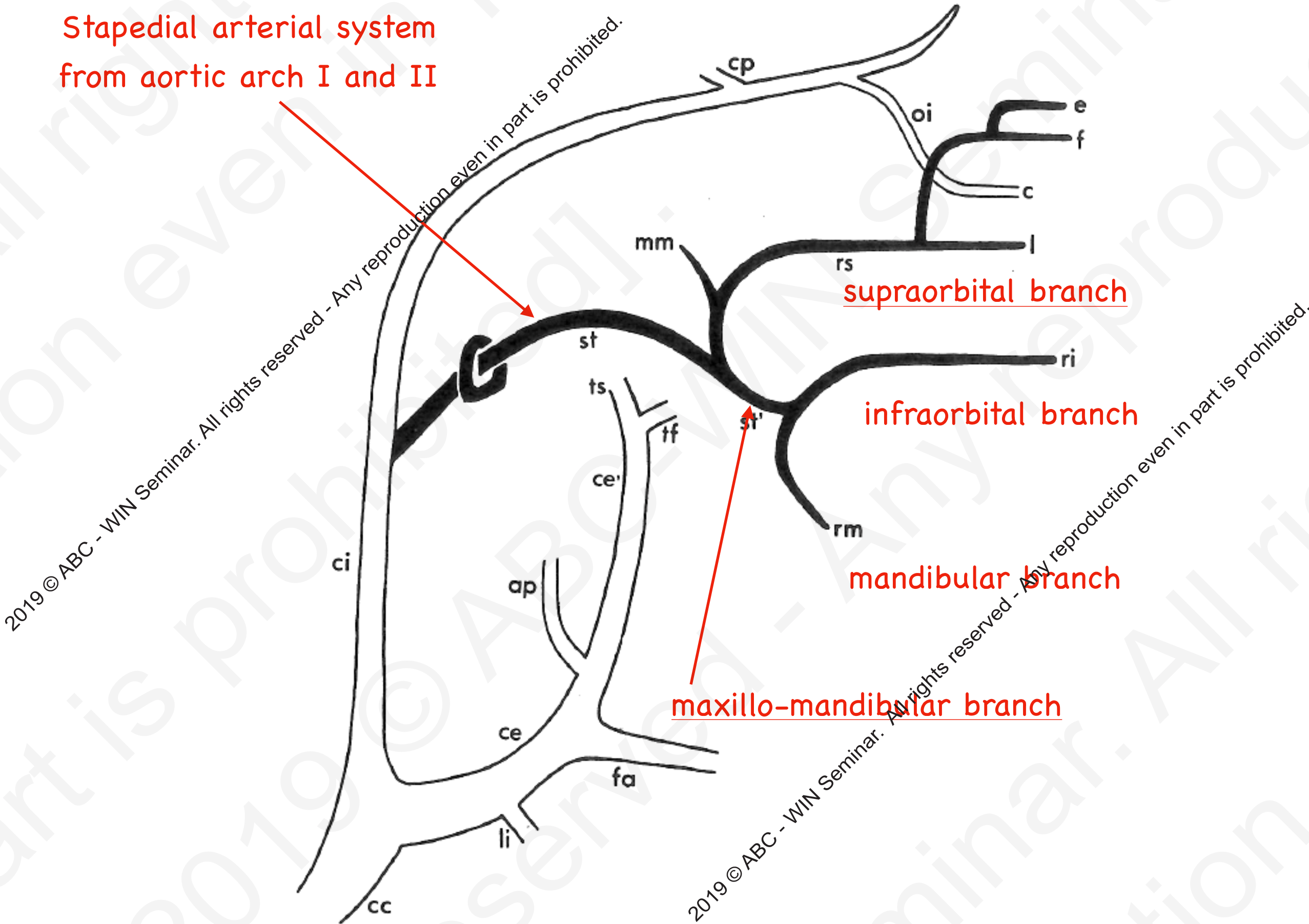


eye and dura

upper jaw

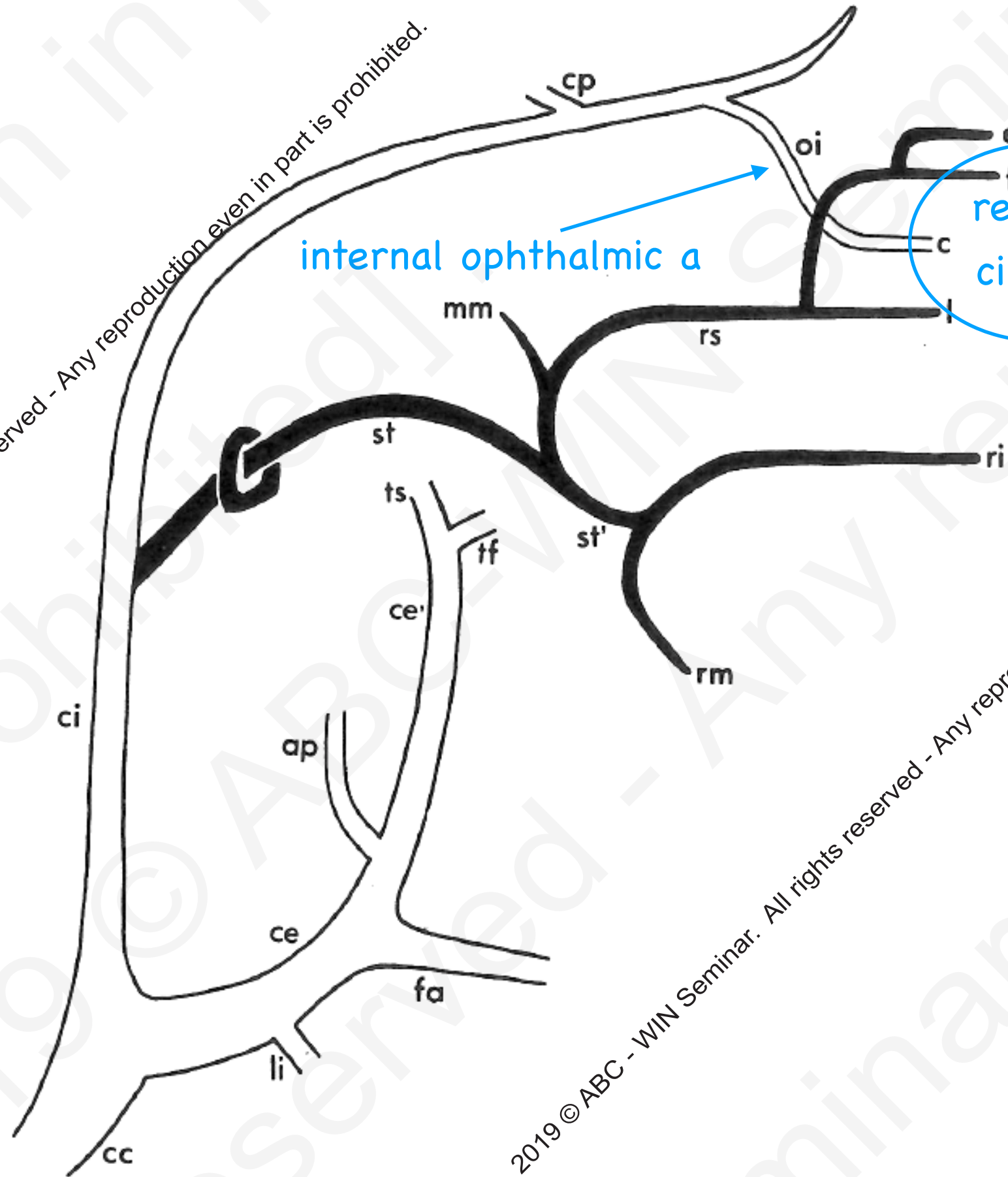
lower jaw

Stapedial arterial system  
from aortic arch I and II





2019 © ABC - WIN Seminar. All rights reserved - Any reproduction even in part is prohibited.



internal ophthalmic a

retinal a  
ciliary a

bulbar structures

2019 © ABC - WIN Seminar. All rights reserved - Any reproduction even in part is prohibited.





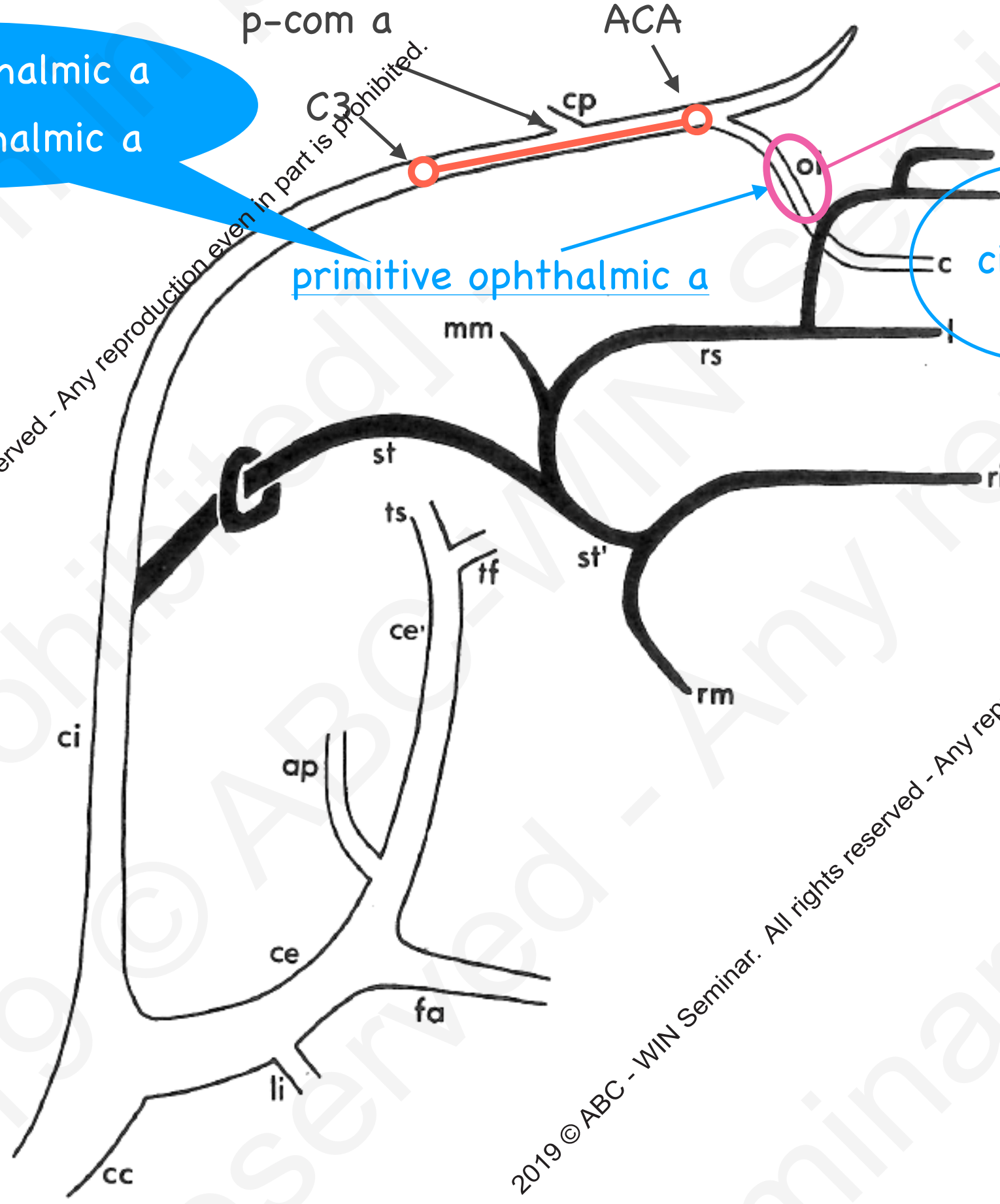
ventral ophthalmic a  
dorsal ophthalmic a

p-com a  
ACA  
cp  
C3  
primitive ophthalmic a

optic canal

ciliary a

bulbar structures



2019 © ABC - WIN Seminar. All rights reserved - Any reproduction even in part is prohibited.

2019 © ABC - WIN Seminar. All rights reserved - Any reproduction even in part is prohibited.

ventral ophthalmic a  
dorsal ophthalmic a

p-com a

ACA

optic canal

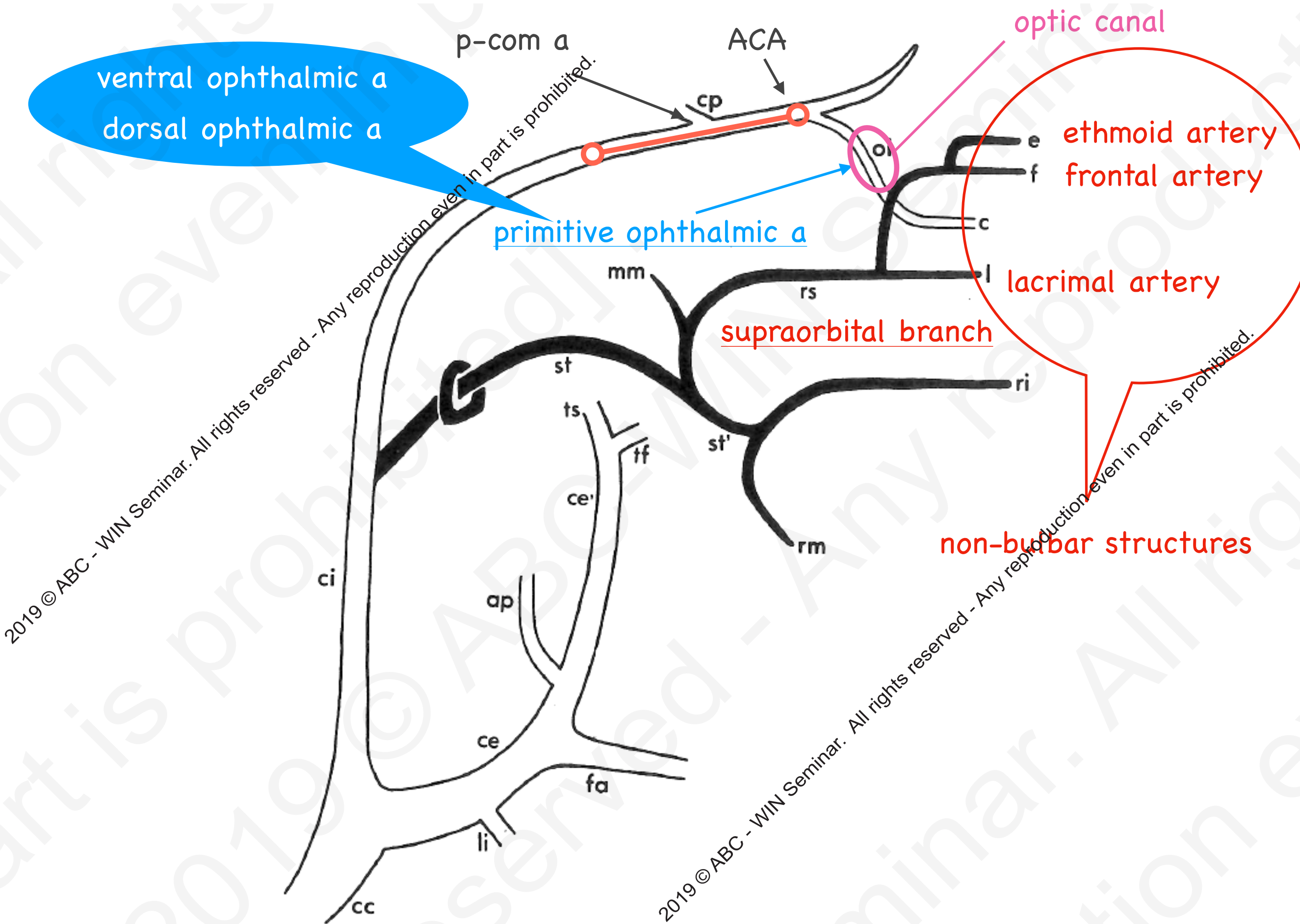
primitive ophthalmic a

ethmoid artery  
frontal artery

lacrimal artery

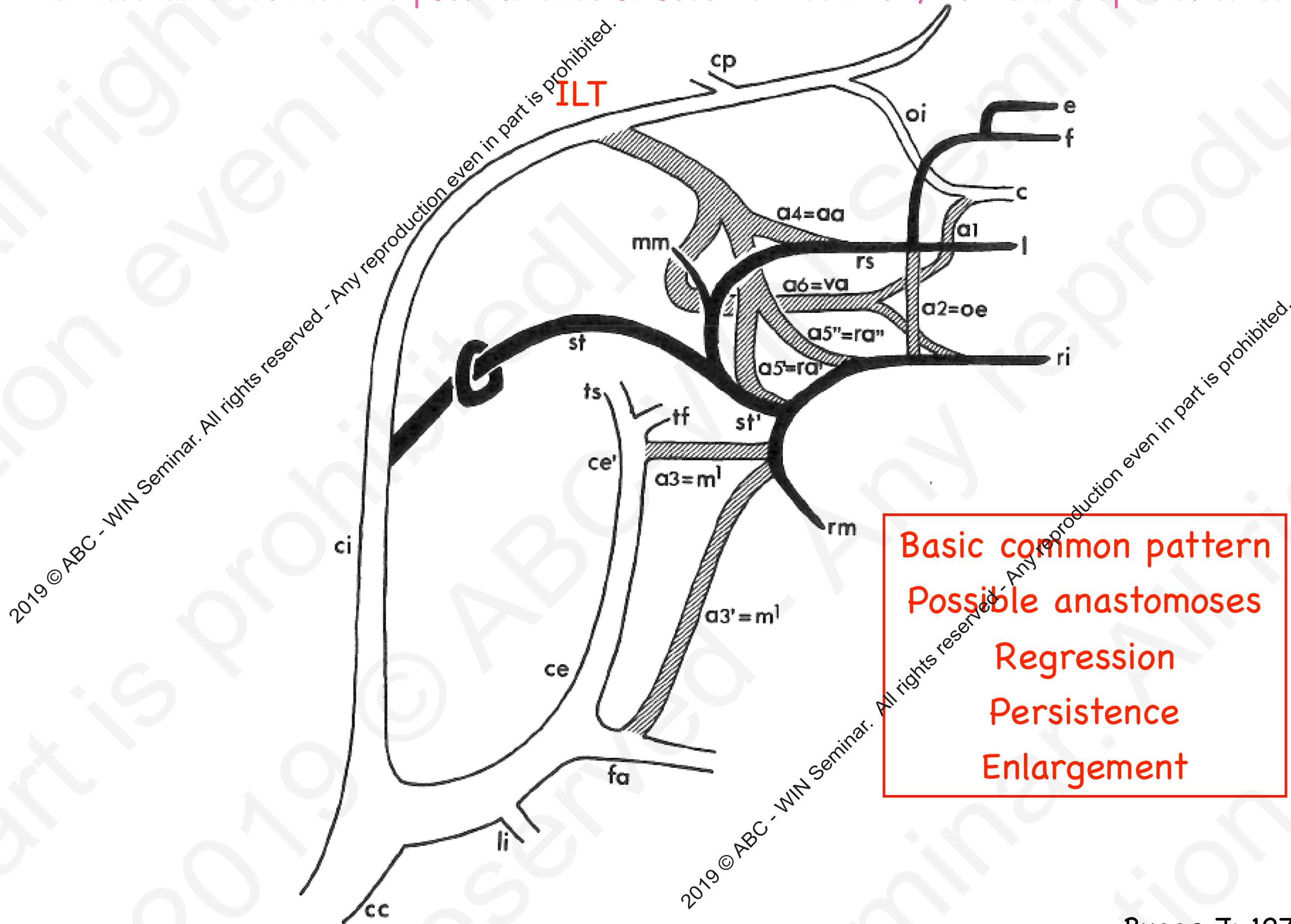
supraorbital branch

non-bar structures

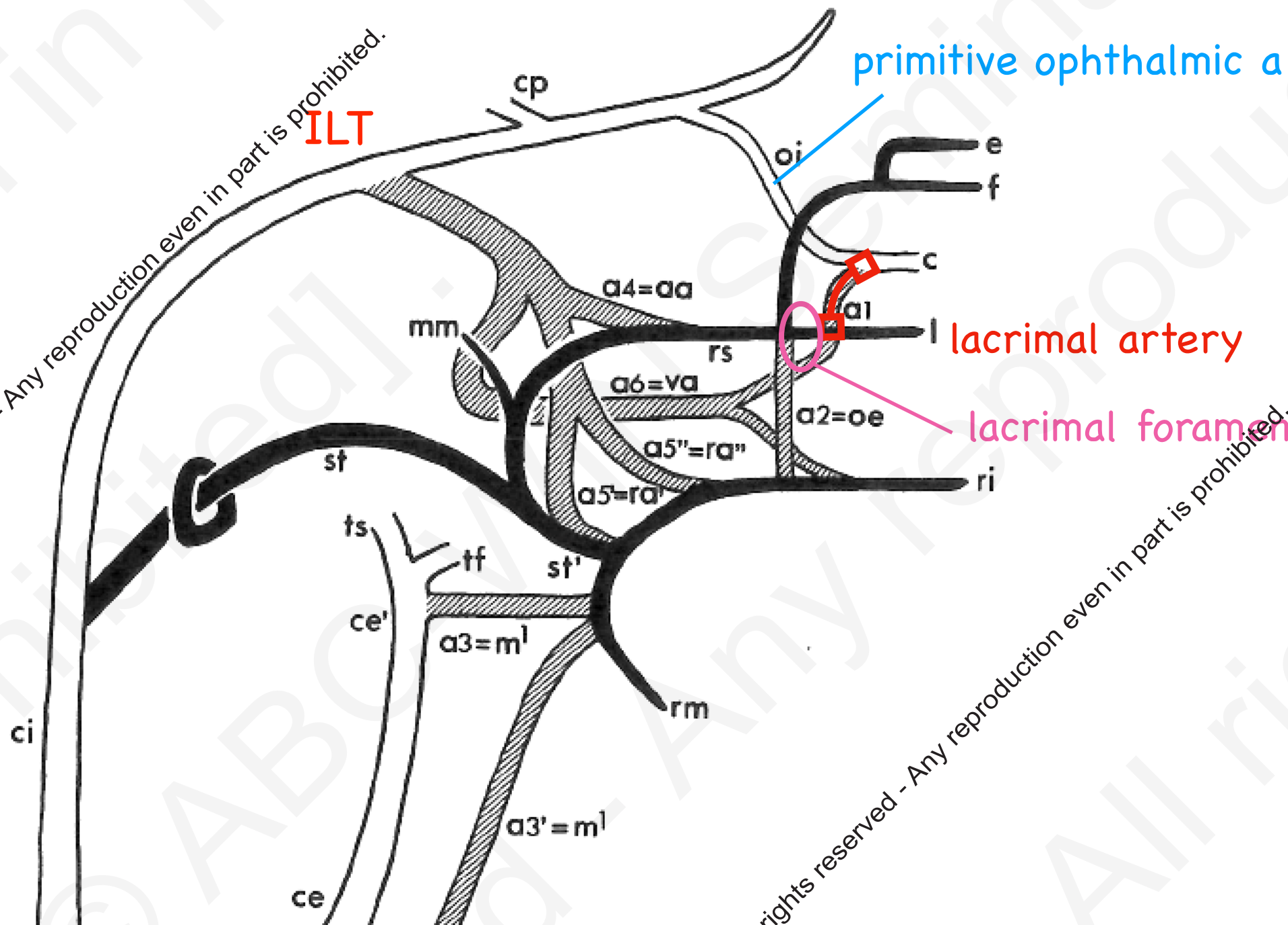




Hatched arteries indicate possible anastomoses between ICA, ECA and stapedal artery.



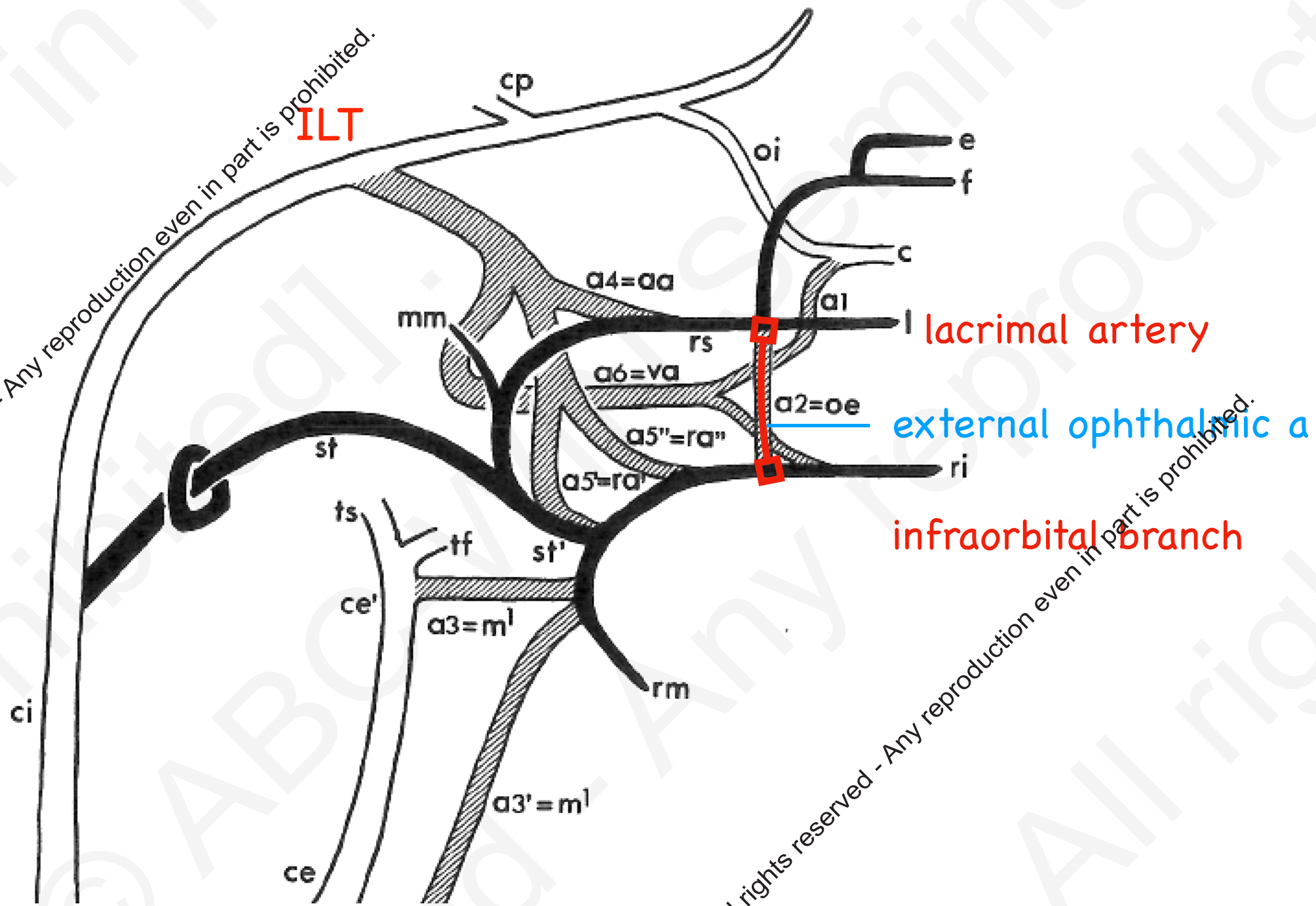
2019 © ABC - WIN Seminar. All rights reserved - Any reproduction even in part is prohibited.



This a1 anastomosis is established within 2 months of the gestational period and persists without regression.

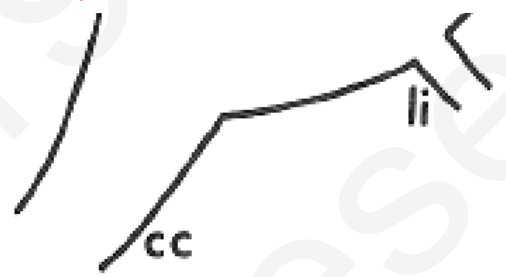
2019 © ABC - WIN Seminar. All rights reserved - Any reproduction even in part is prohibited.

2019 © ABC - WIN Seminar. All rights reserved - Any reproduction even in part is prohibited.



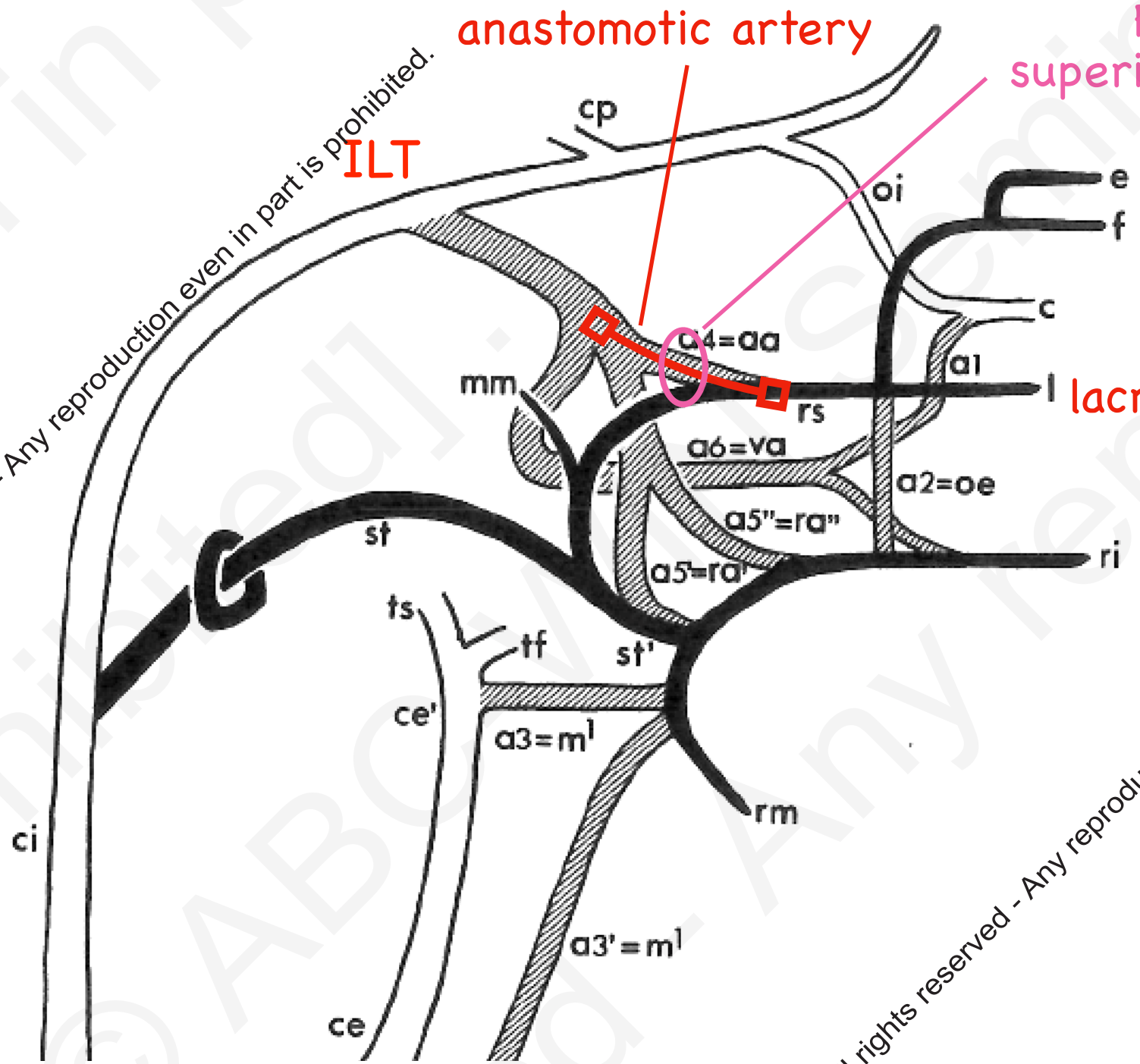
lacrimal artery  
external ophthalmic a  
infraorbital branch

This a2 anastomosis is established later in 5-9 months of gestational period and constitutes external ophthalmic artery.



2019 © ABC - WIN Seminar. All rights reserved - Any reproduction even in part is prohibited.

2019 © ABC - WIN Seminar. All rights reserved - Any reproduction even in part is prohibited.



anastomotic artery

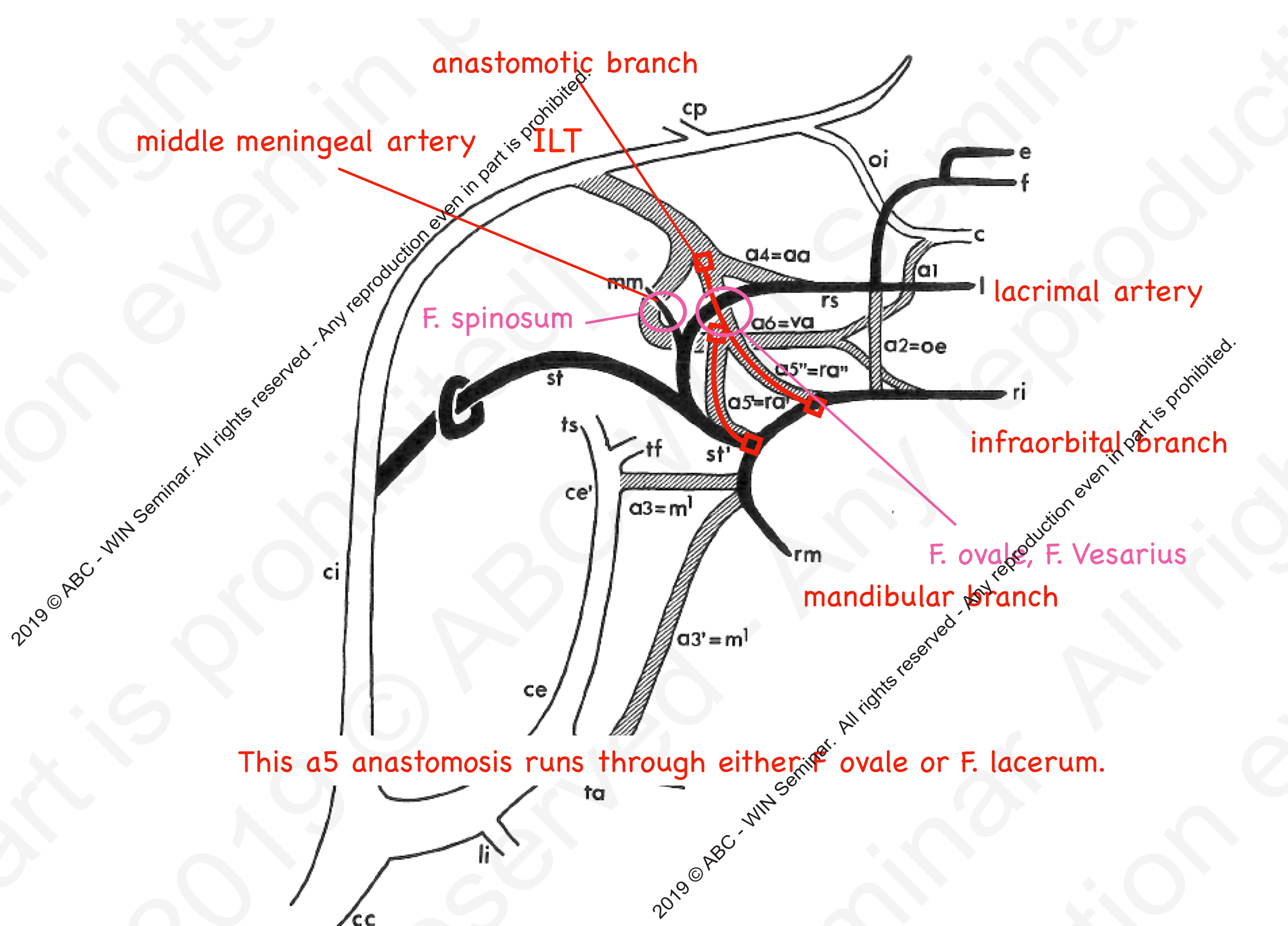
F. rotundum  
superior orbital fissure

lacrimal artery

This a4 anastomosis runs through either F rotundum or medial superior orbital fissure.

2019 © ABC - WIN Seminar. All rights reserved - Any reproduction even in part is prohibited.

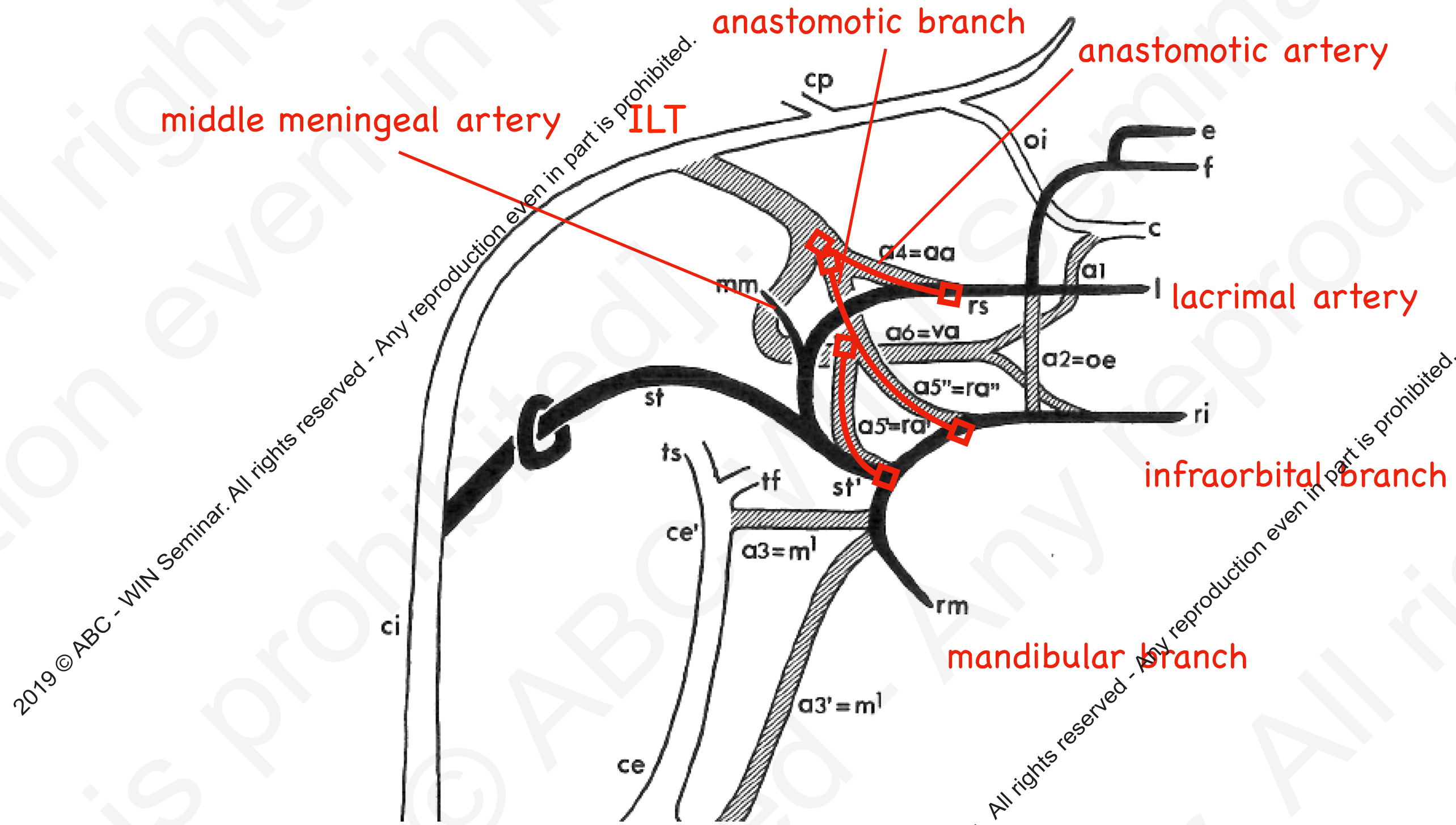




2019 © ABC - WIN Seminar. All rights reserved - Any reproduction even in part is prohibited.

2019 © ABC - WIN Seminar. All rights reserved - Any reproduction even in part is prohibited.

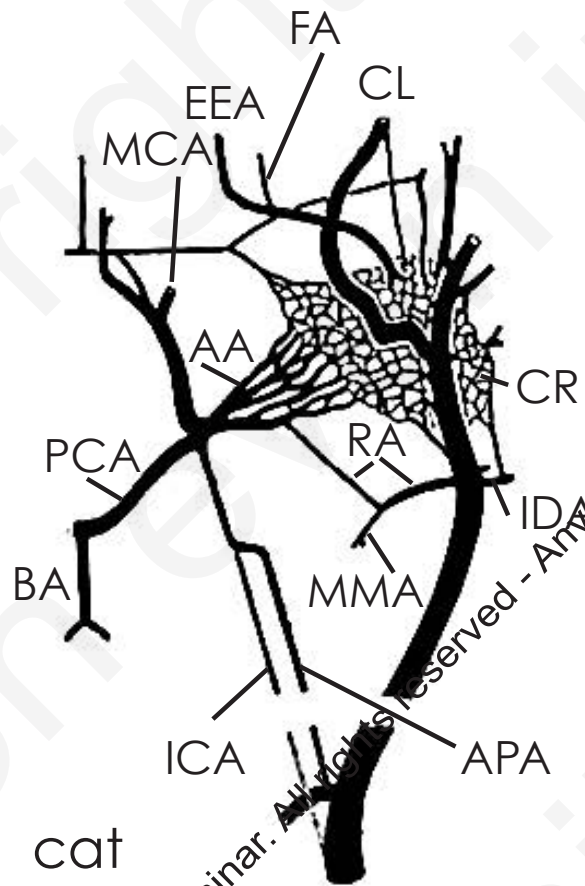
This a5 anastomosis runs through either F. ovale or F. lacerum.



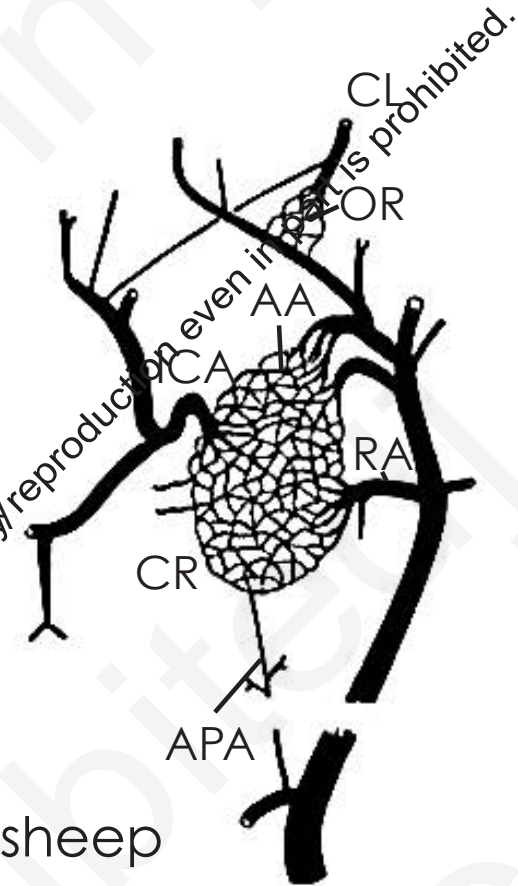
Anastomotic artery (arteria anastomotica) and anastomotic branch (ramus anastomoticus) can be regarded the homologue to the rete mirabile.

2019 © ABC - WIN Seminar. All rights reserved - Any reproduction even in part is prohibited.

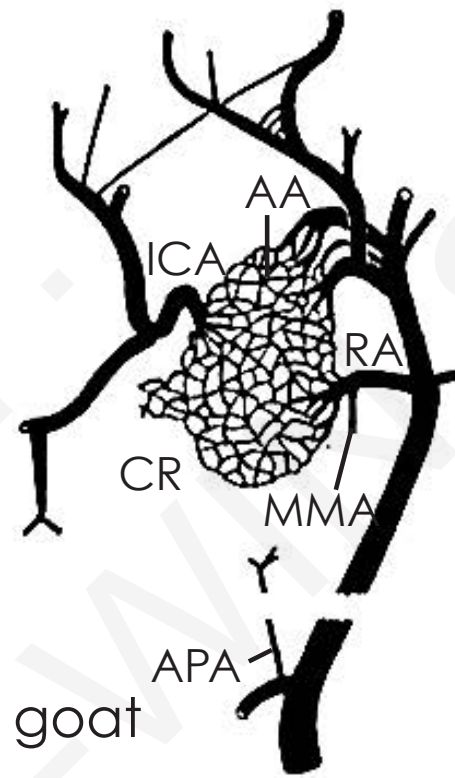
# rete mirabile



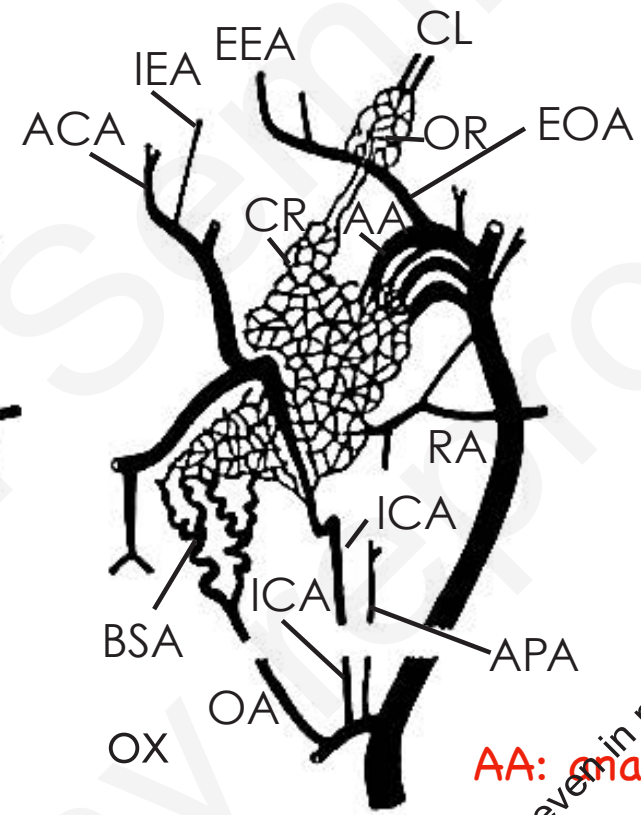
cat



sheep

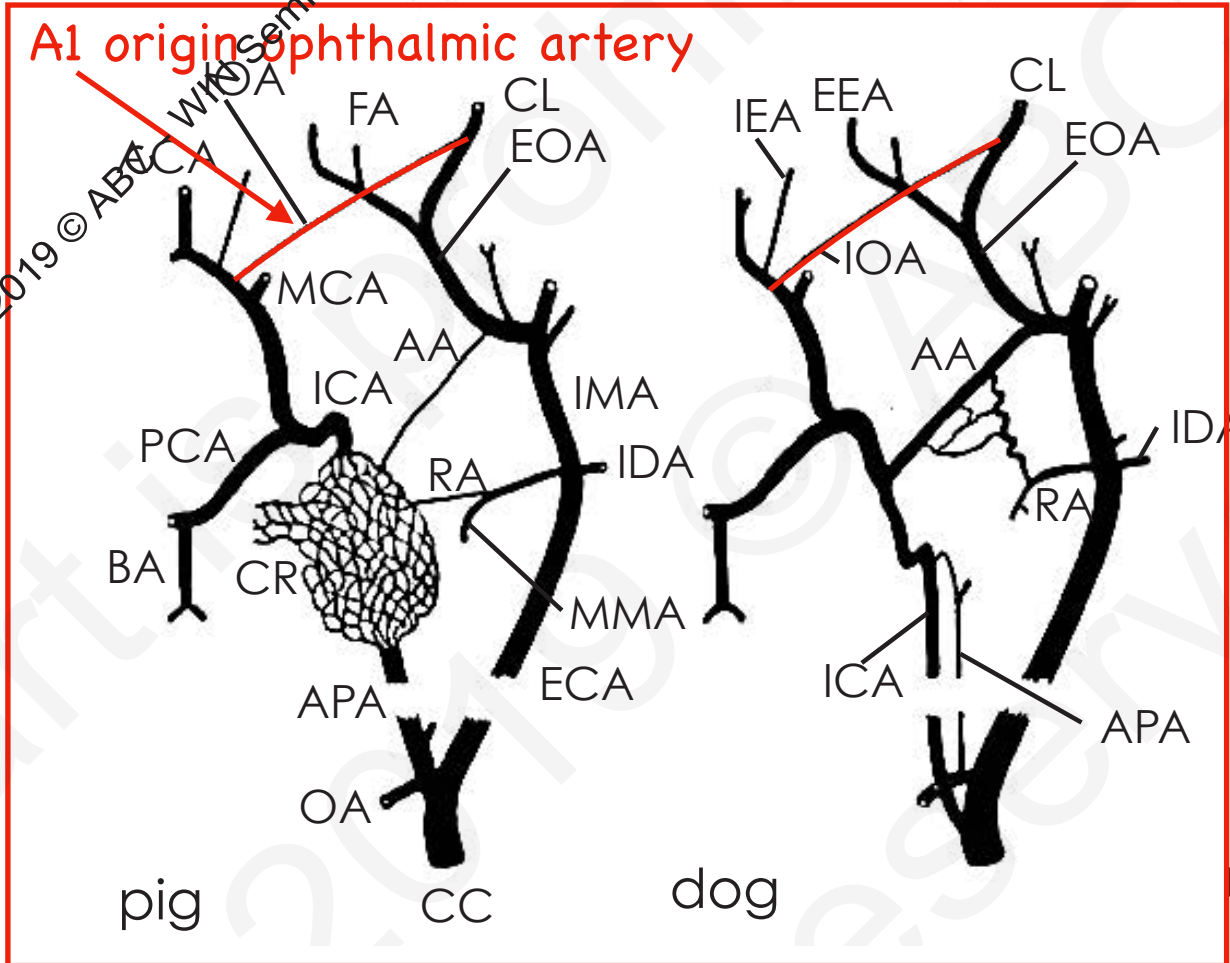


goat



OX

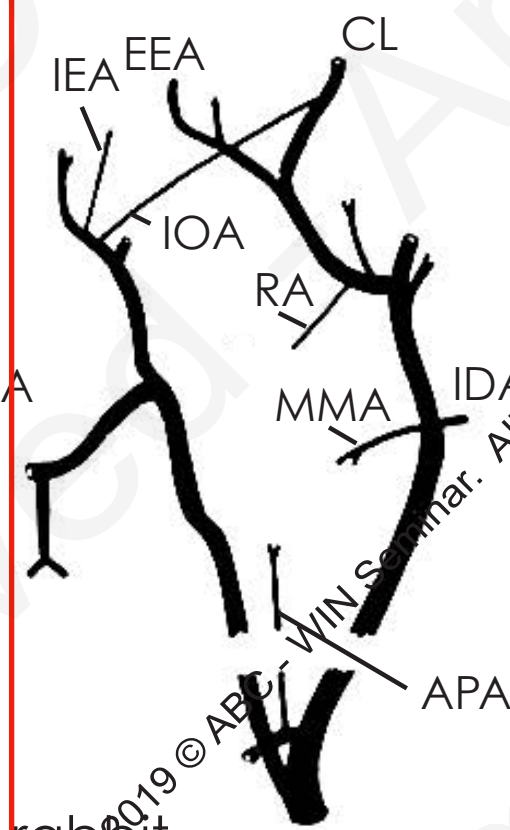
AA: anastomotic artery  
 RA: anastomotic branch (ramus anastomoticus)  
 CL: ciliary artery



pig

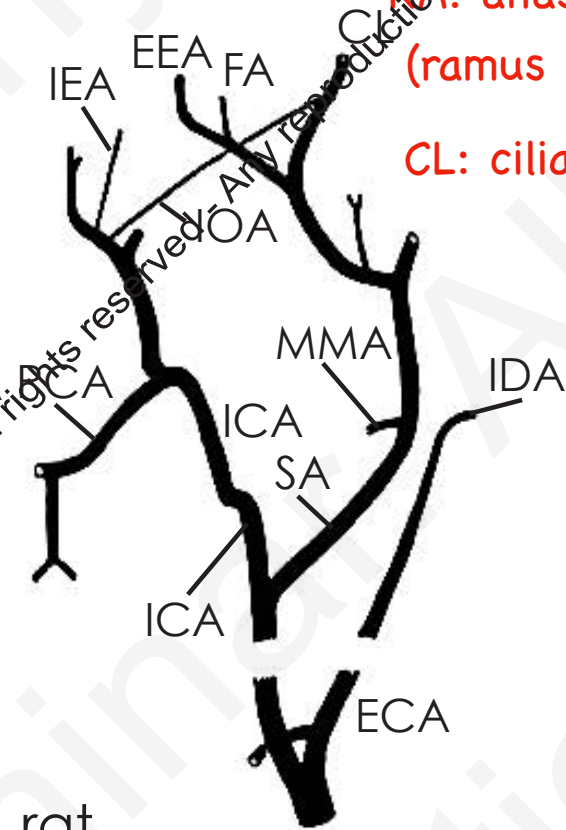
cc

dog



rabbit

rat

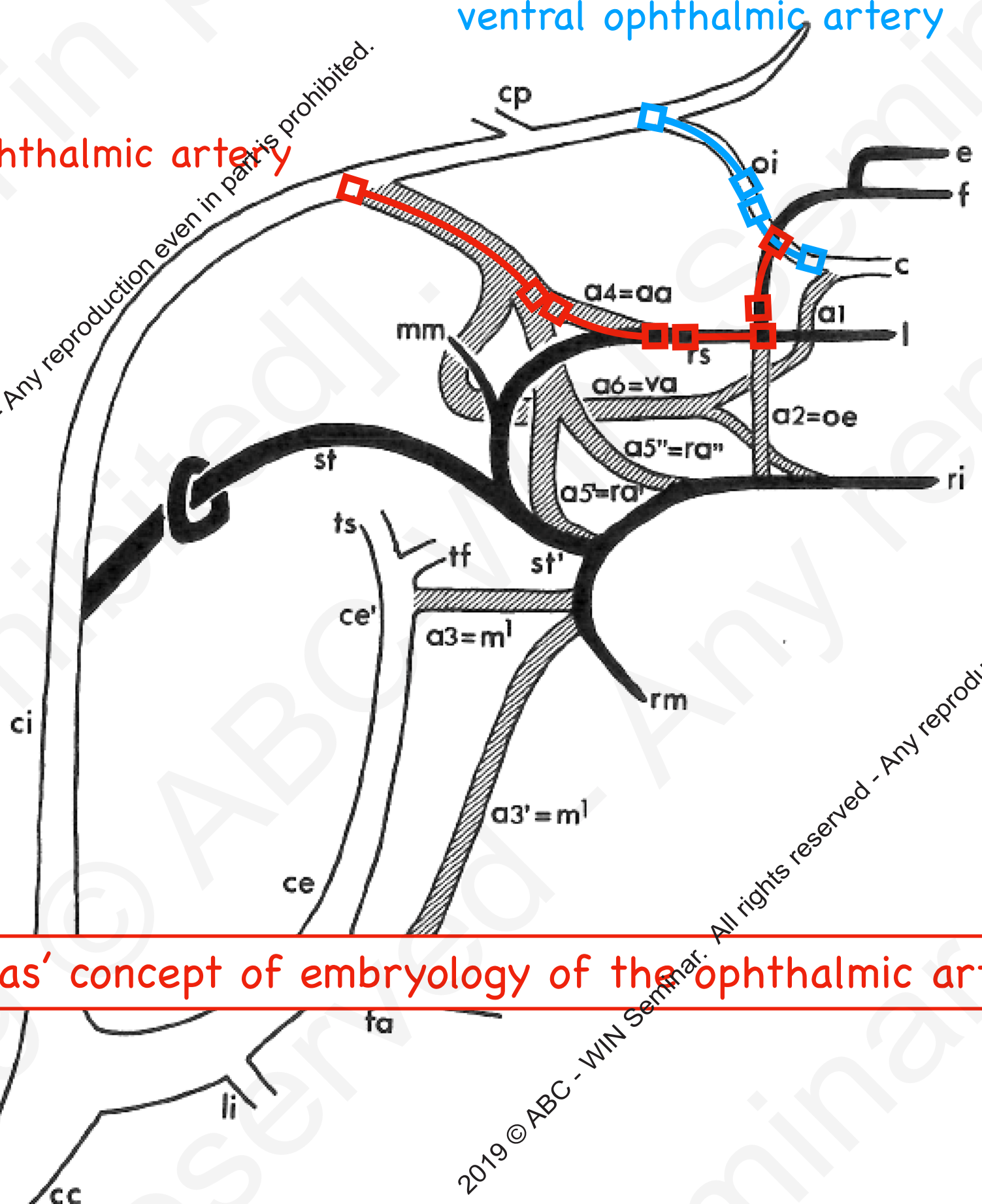




2019 © ABC - WIN Seminar. All rights reserved - Any reproduction even in part is prohibited.

ventral ophthalmic artery

dorsal ophthalmic artery



Lasjaunias' concept of embryology of the ophthalmic artery

2019 © ABC - WIN Seminar. All rights reserved - Any reproduction even in part is prohibited.



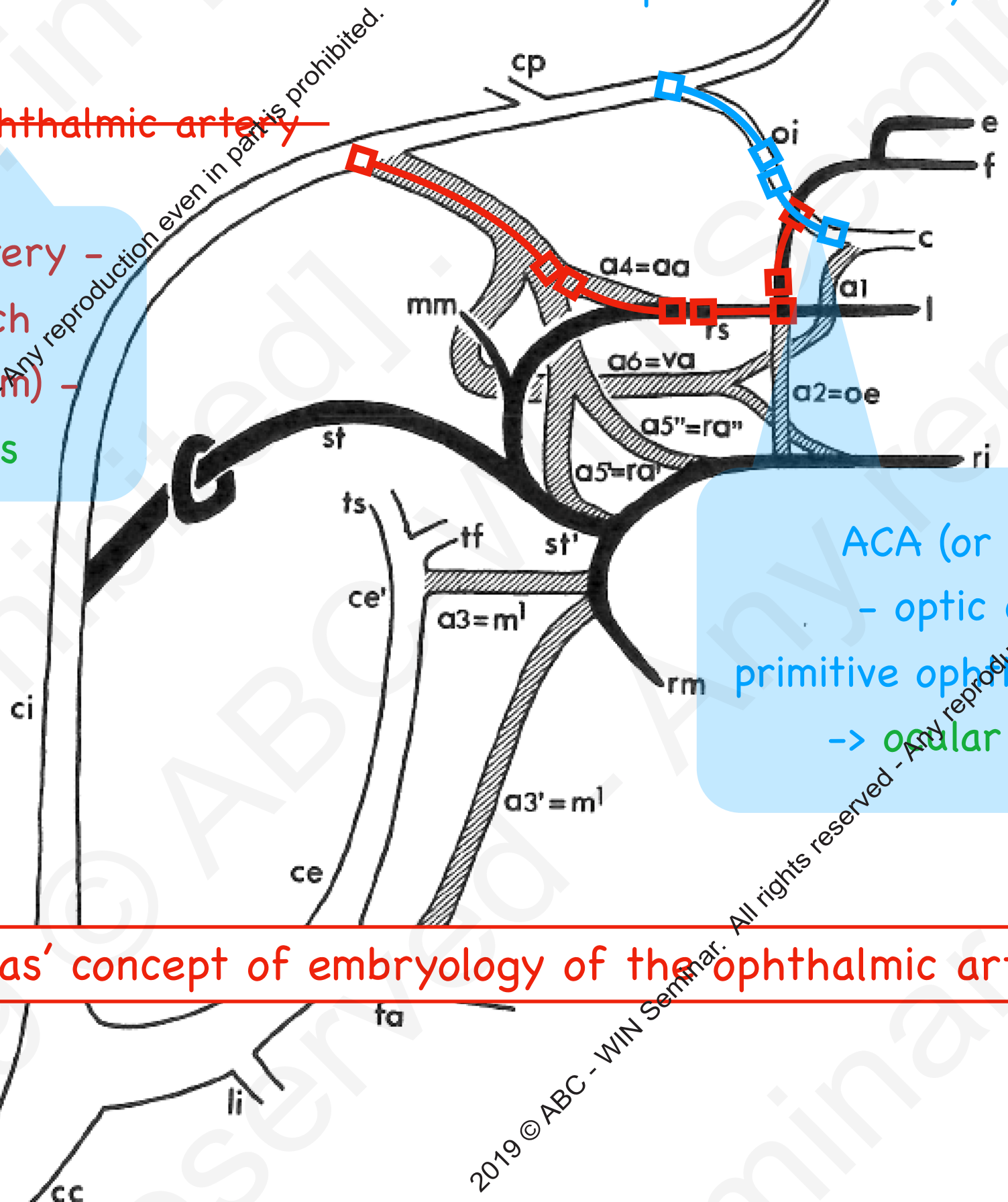
~~dorsal ophthalmic artery~~

~~ventral ophthalmic artery~~

ILT - anastomotic artery -  
supraorbital branch  
- SOF (or F. rotundum) -  
-> orbital arteries

ACA (or C3 ICA)  
- optic canal -  
primitive ophthalmic artery  
-> ocular arteries

Lasjaunias' concept of embryology of the ophthalmic artery



2019 © ABC - WIN Seminar. All rights reserved. Any reproduction even in part is prohibited.

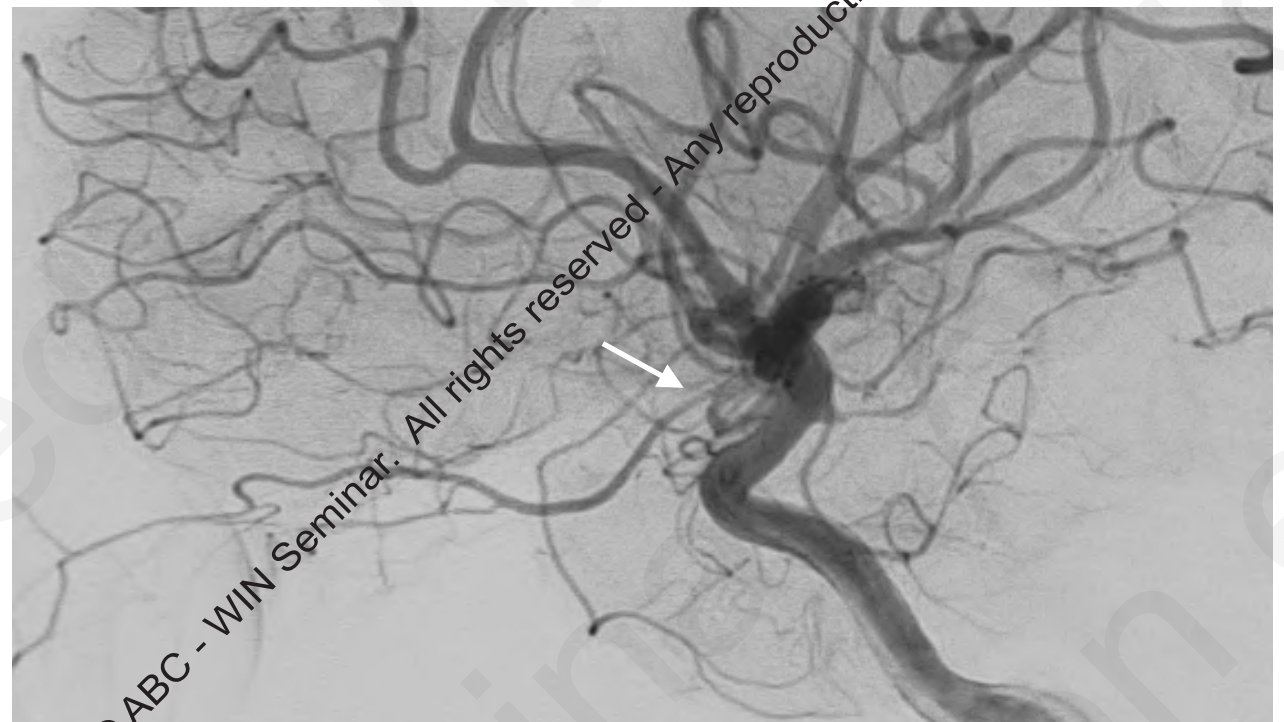
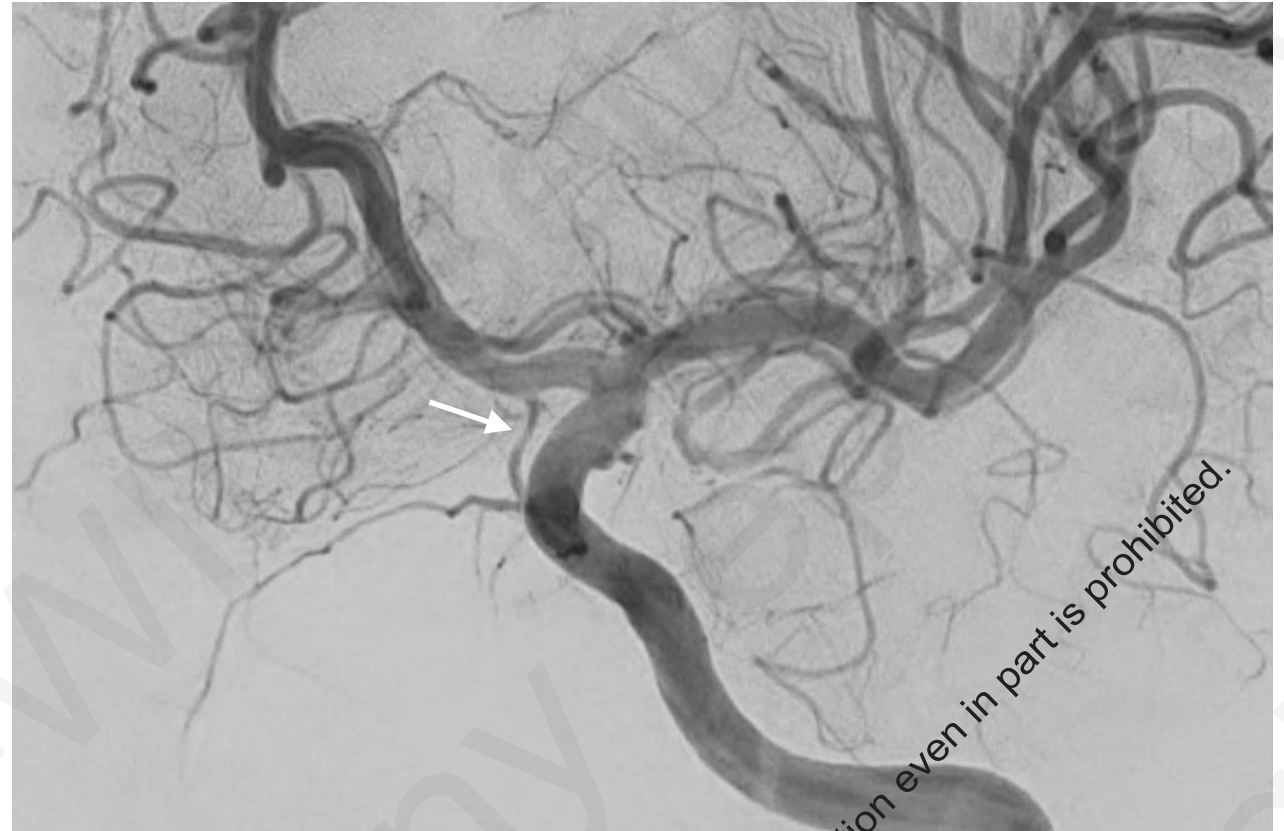
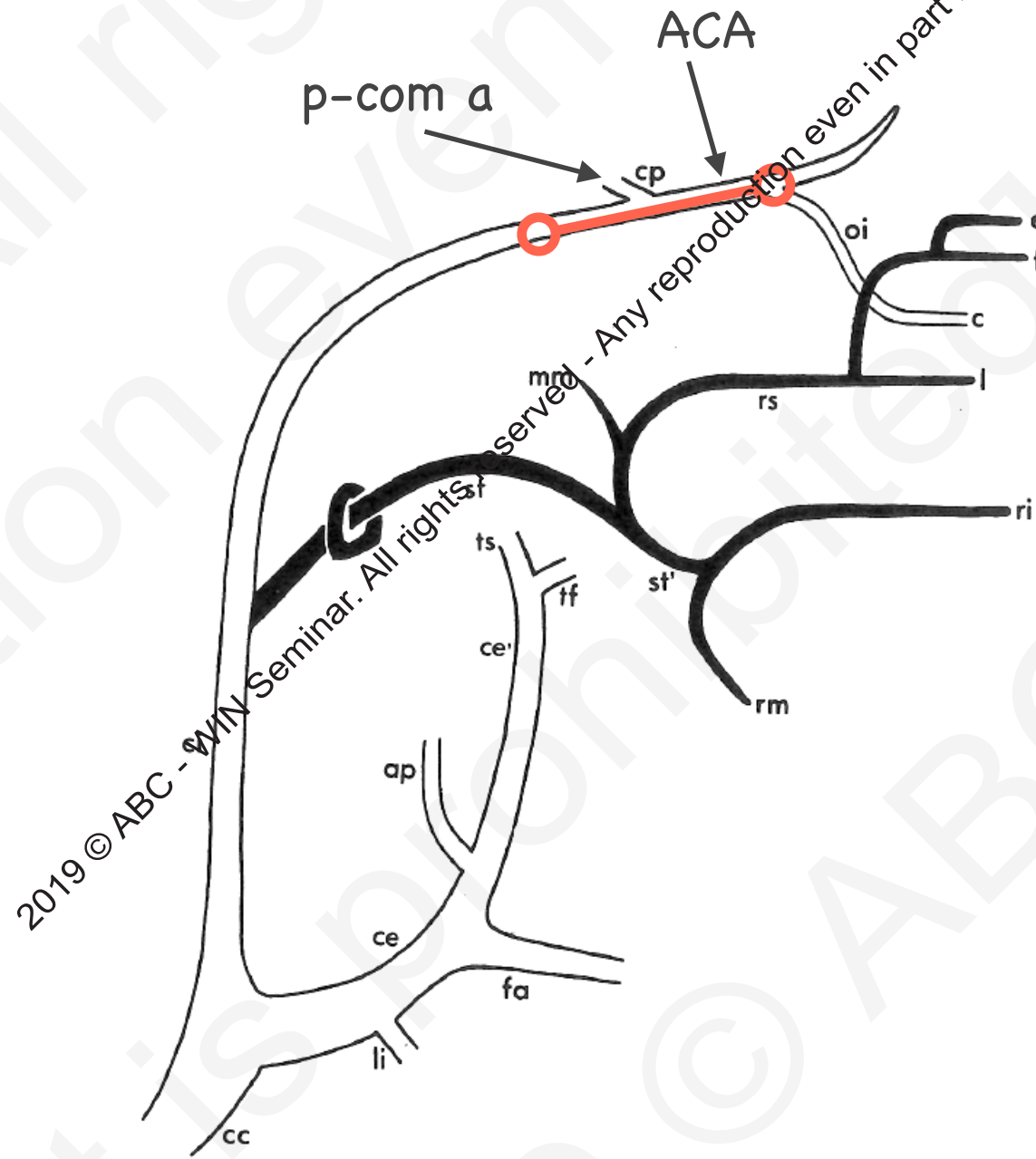
2019 © ABC - WIN Seminar. All rights reserved. Any reproduction even in part is prohibited.

2019 © ABC - WIN Seminar. All rights reserved - Any reproduction even in part is prohibited.

# Ophthalmic artery variations

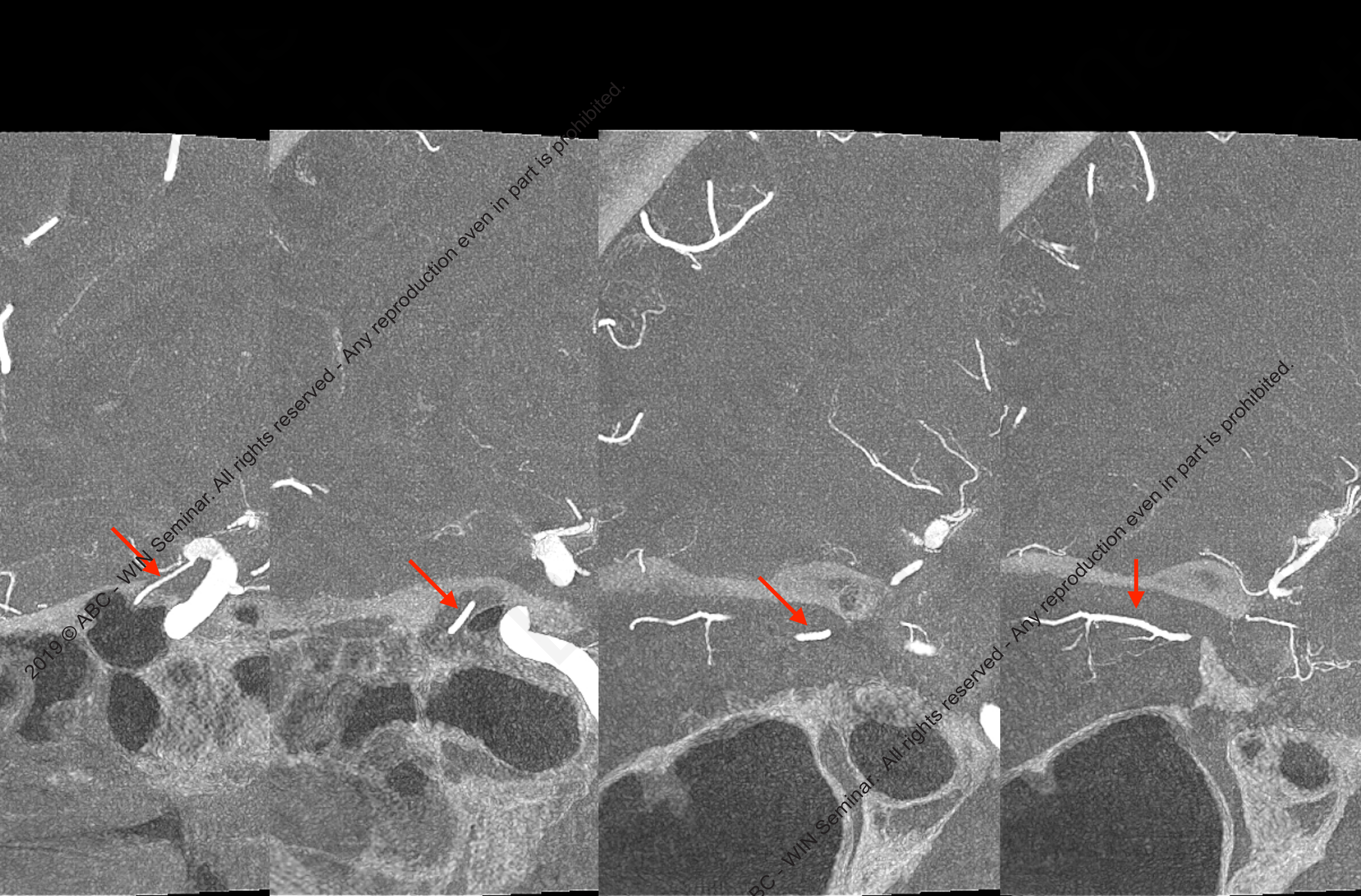2019 © ABC - WIN Seminar. All rights reserved - Any reproduction even in part is prohibited.

# Misunderstood "ventral ophthalmic artery"



ACA (A1) origin primitive ophthalmic artery

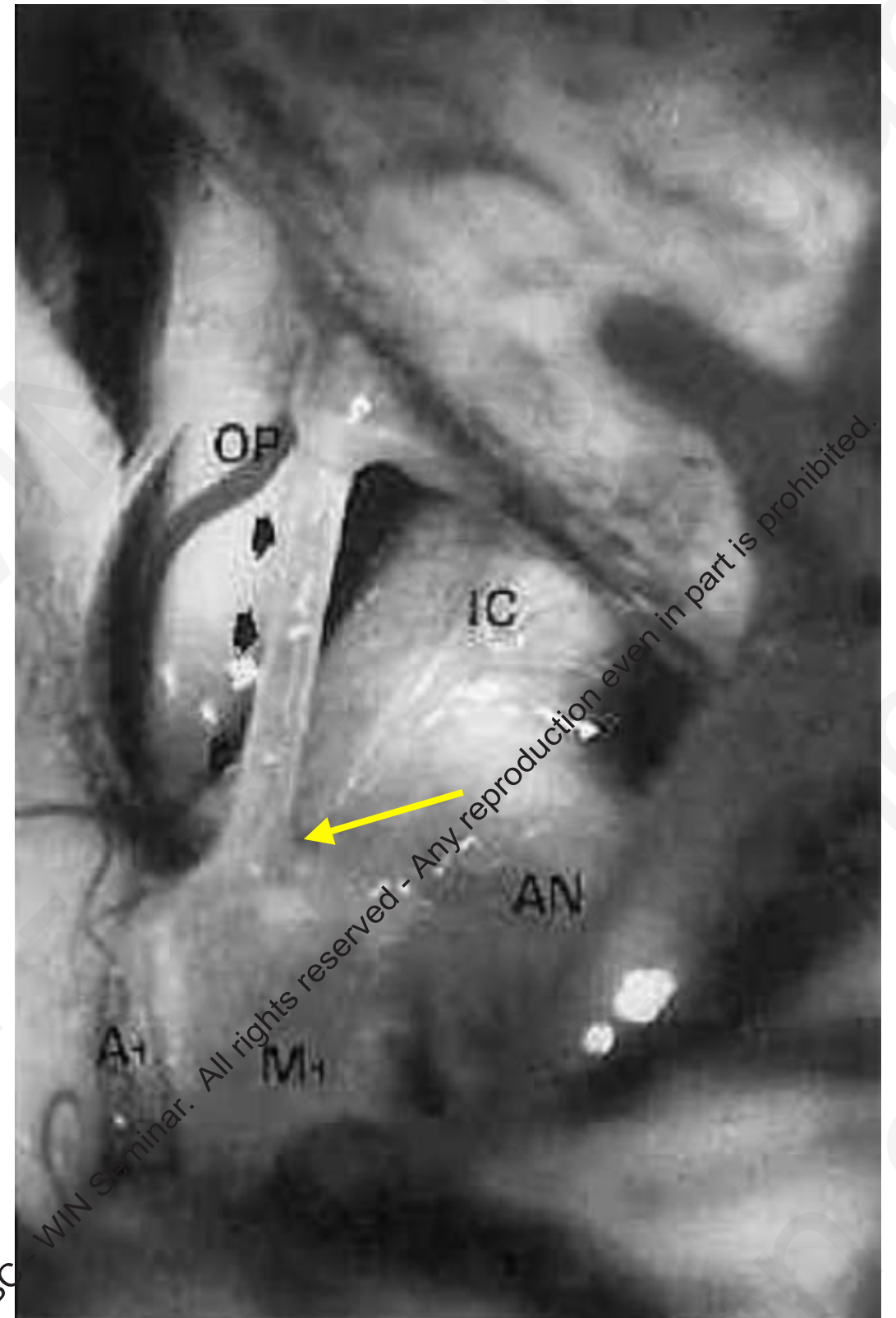
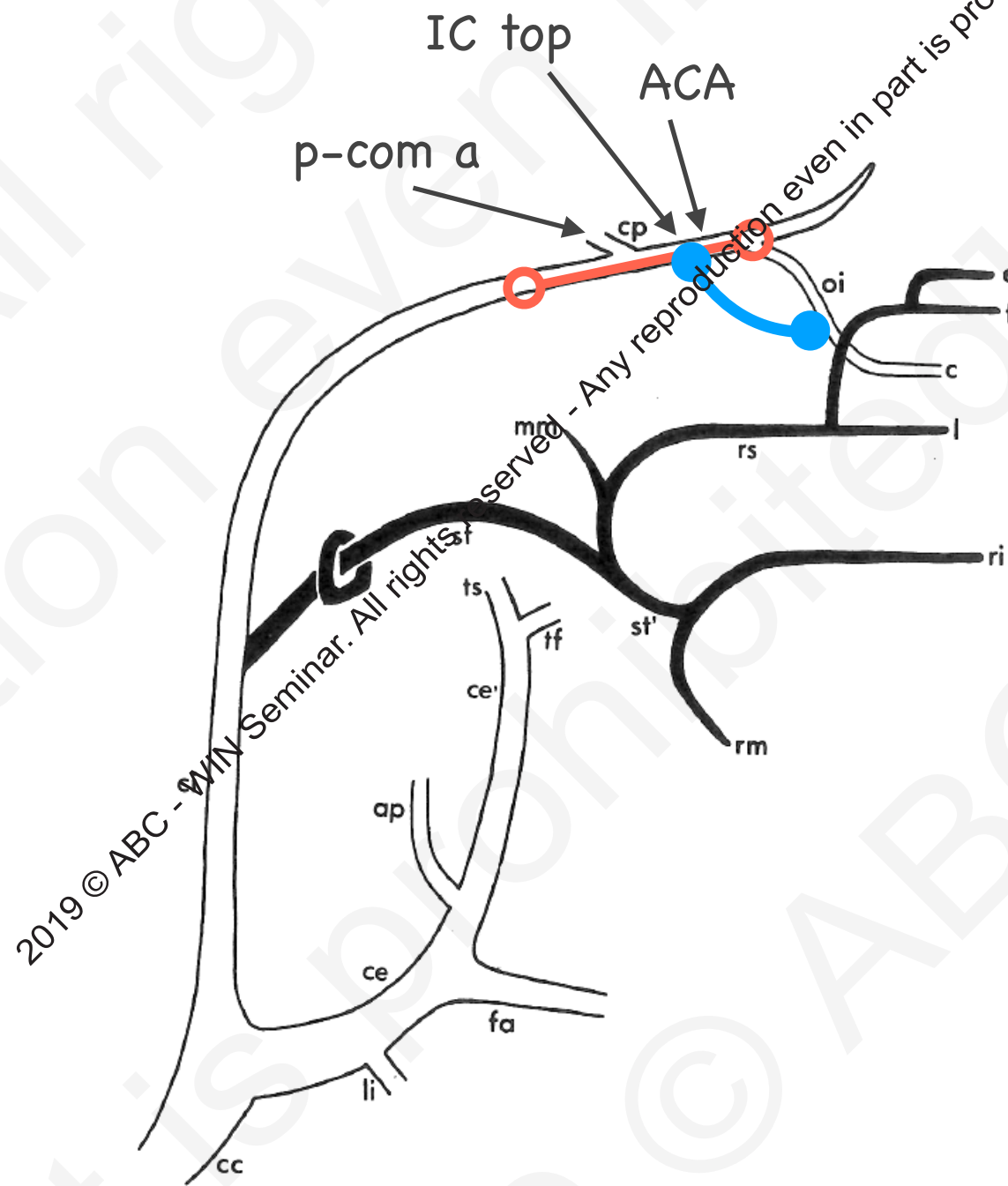




ophthalmic artery of A1 origin = primitive ophthalmic artery  
-> runs through optic canal

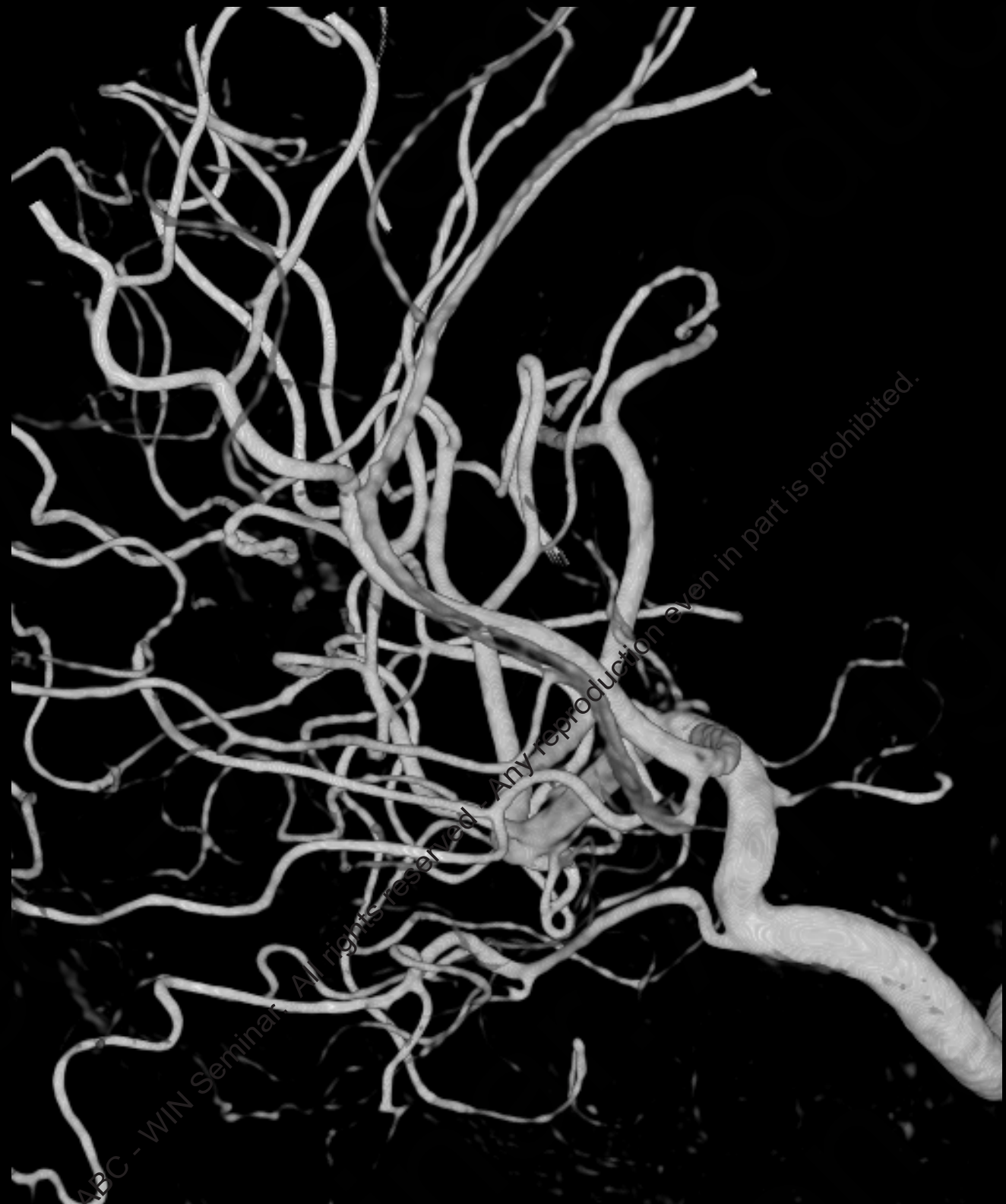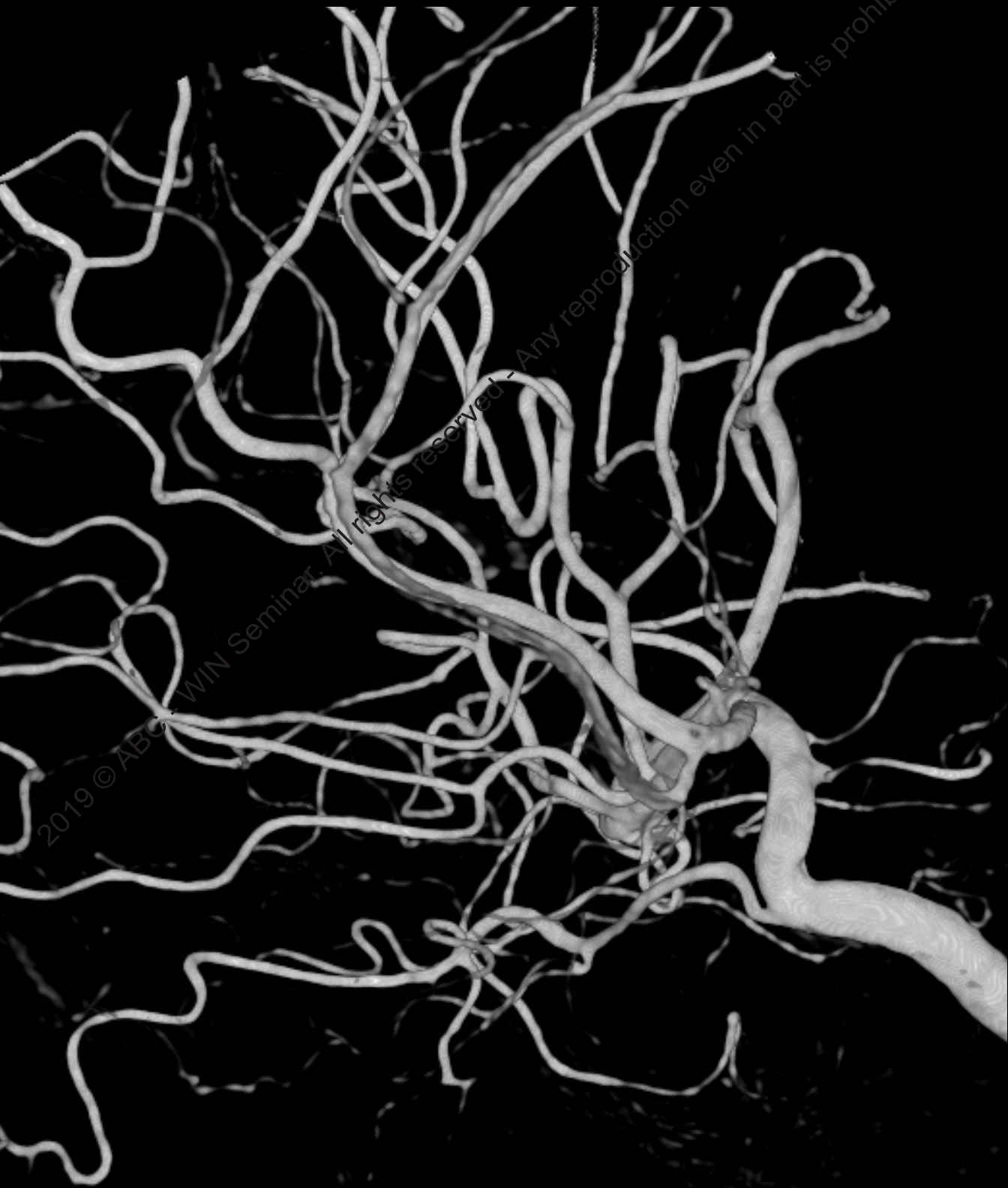


# Misunderstood "ventral ophthalmic artery"



IC terminal origin primitive ophthalmic artery

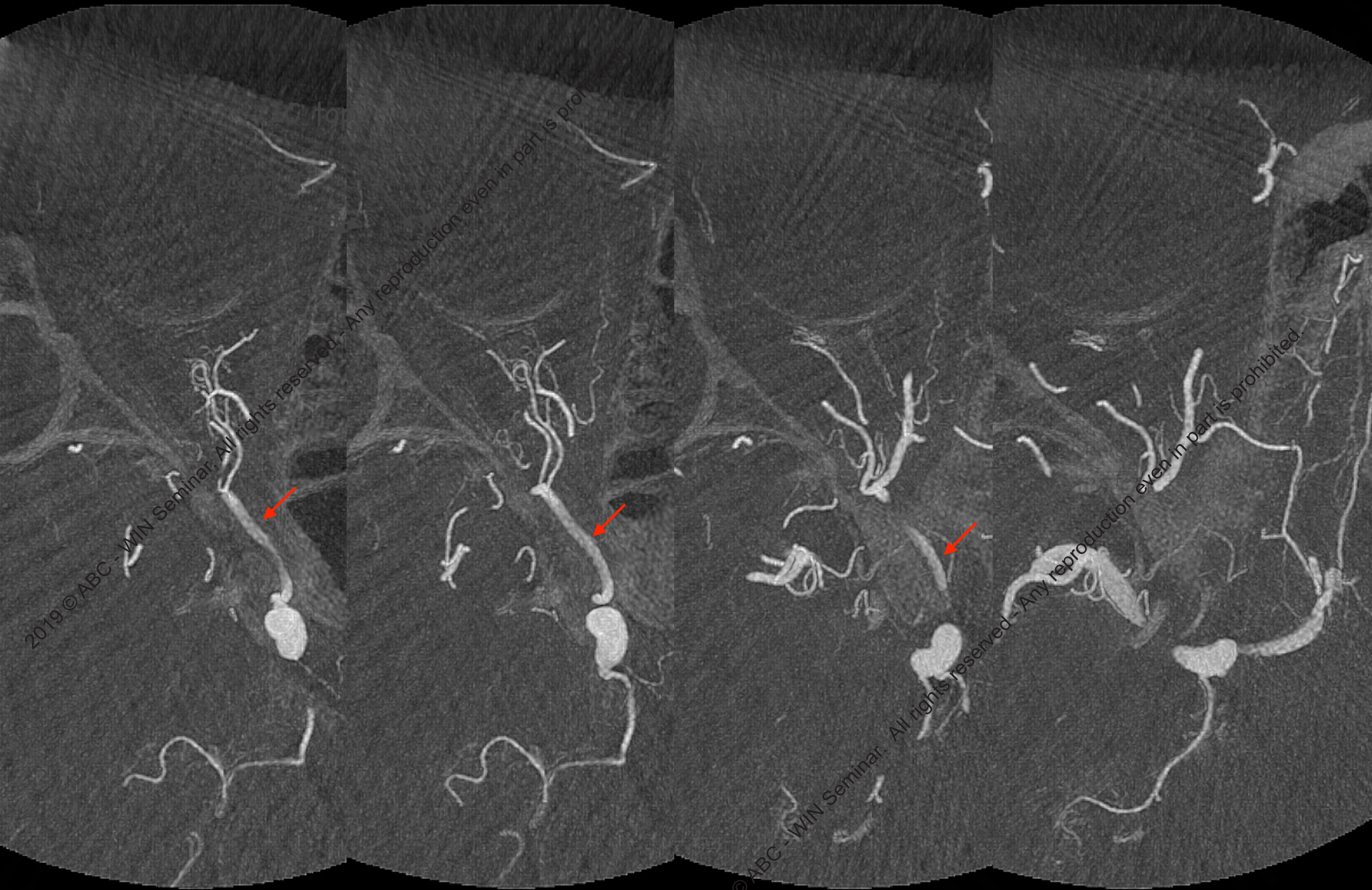
Hamada J: JNS 1991



23/M

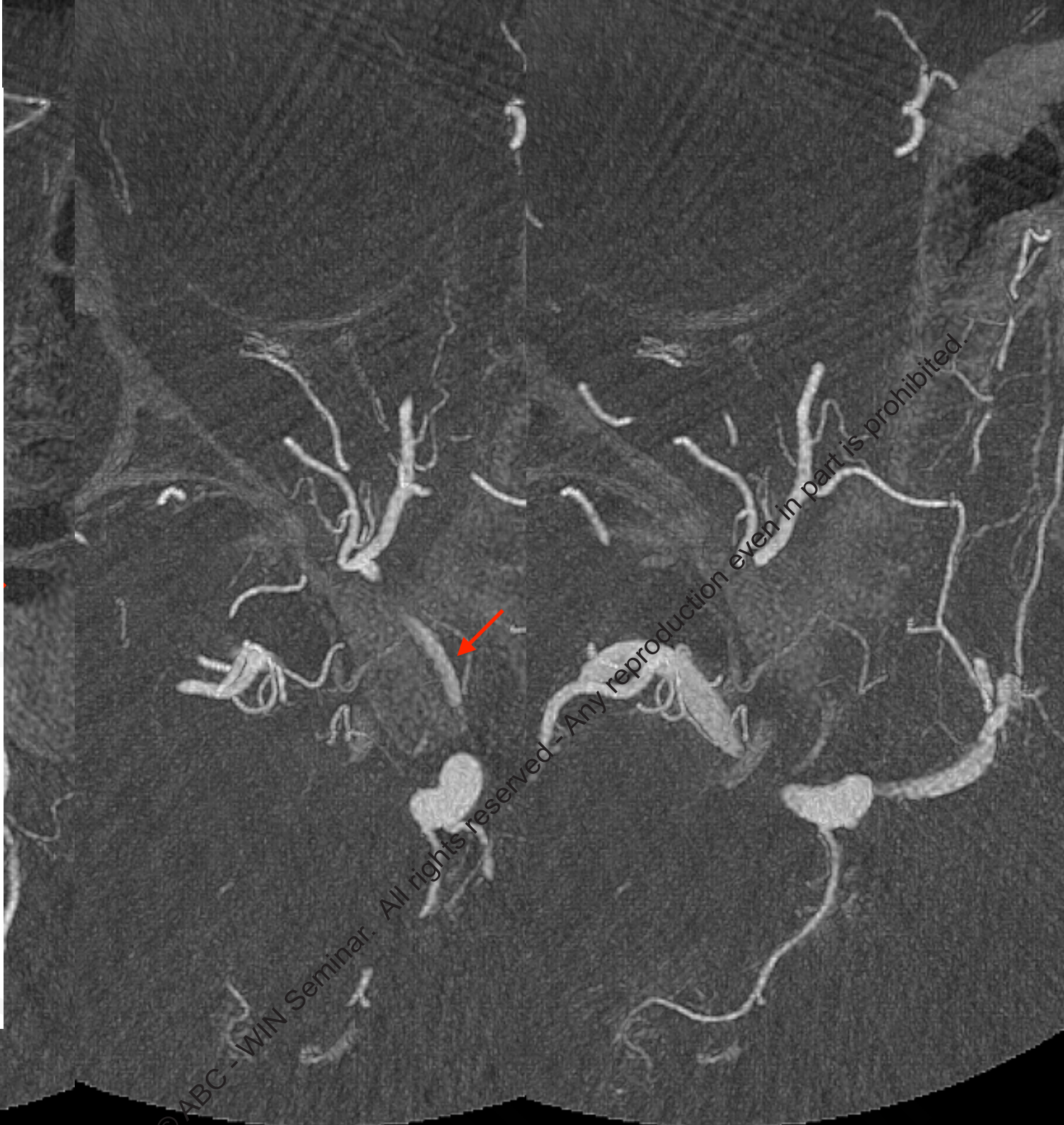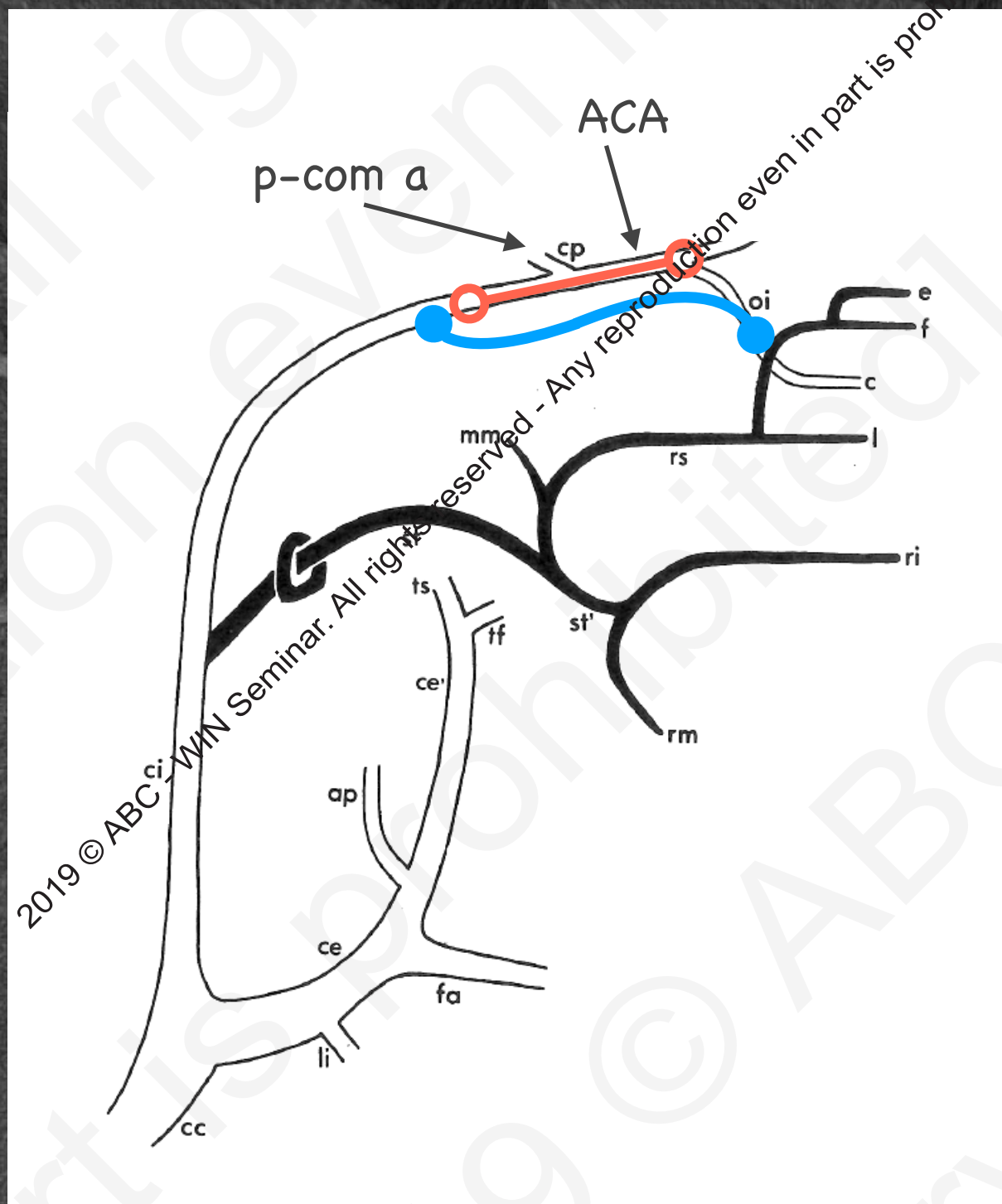
👁️ stereoscopic view





Ophthalmic artery runs through the optic canal.


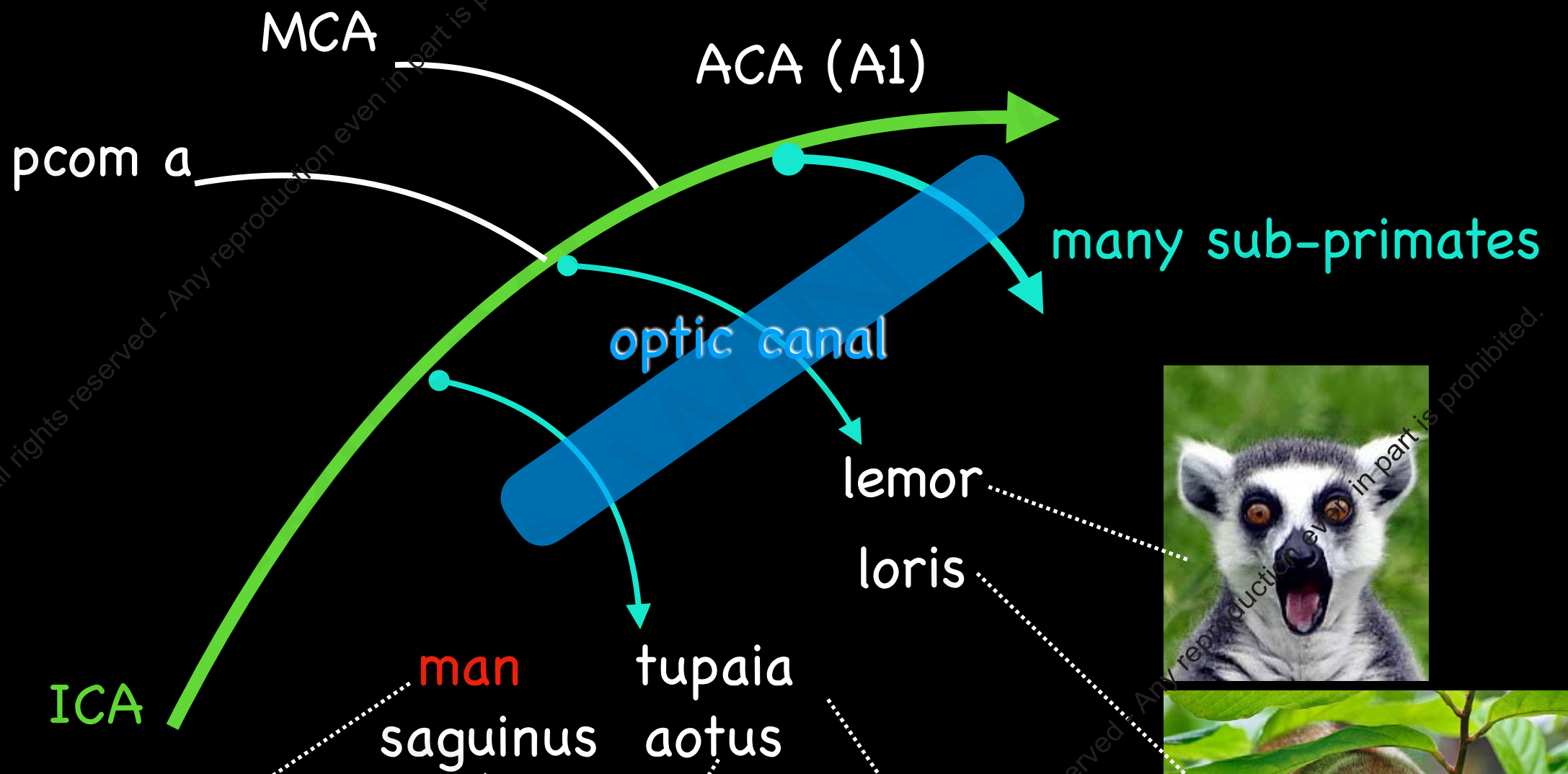




Ophthalmic artery runs through the optic canal.



# Phylogenetic changes of the ophthalmic artery origin



2019 © ABC - WIN Seminar. All rights reserved. Any reproduction even in part is prohibited.

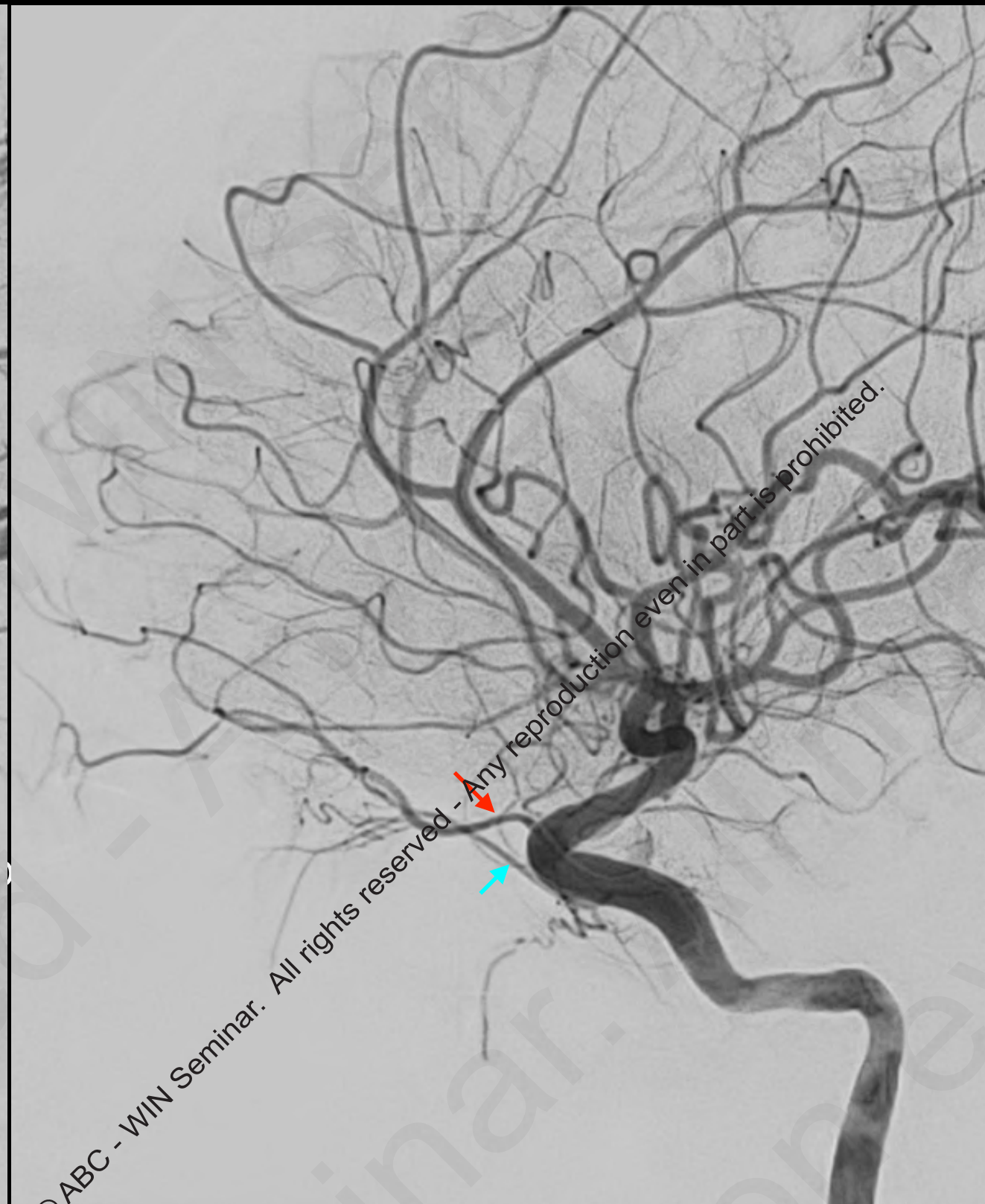
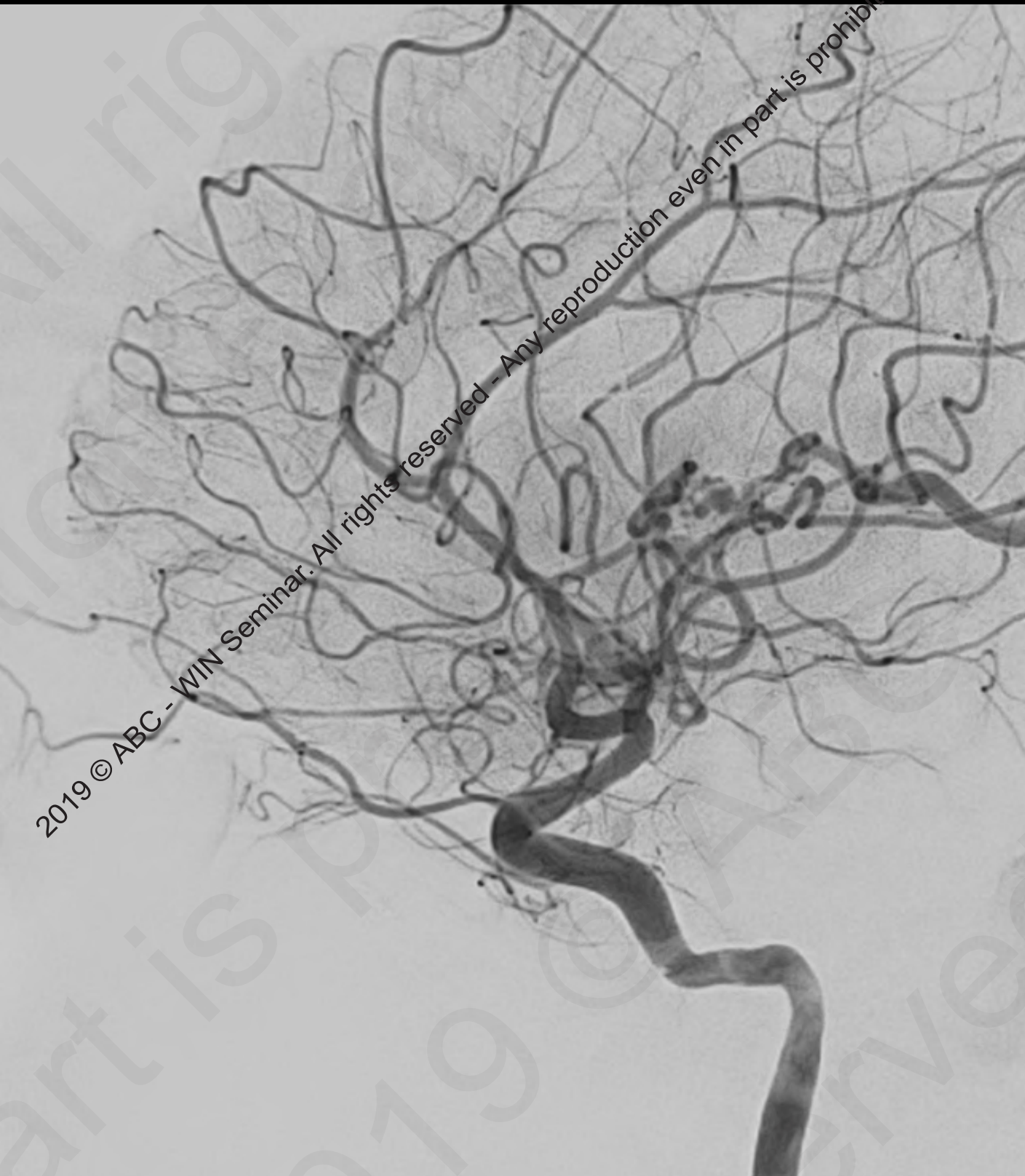
2019 © ABC - WIN Seminar. All rights reserved. Any reproduction even in part is prohibited.



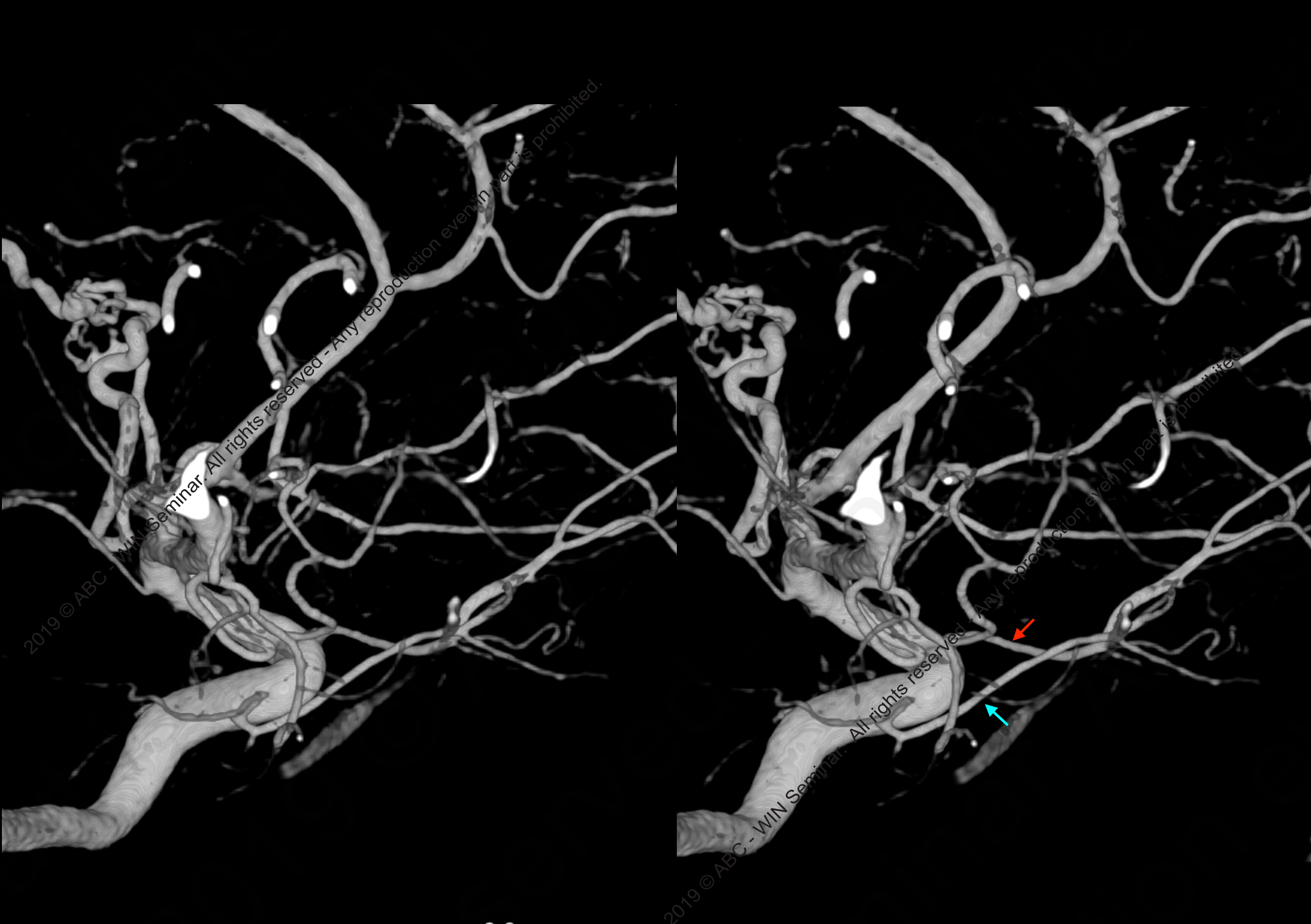




# 16/M: double ophthalmic a + AVM

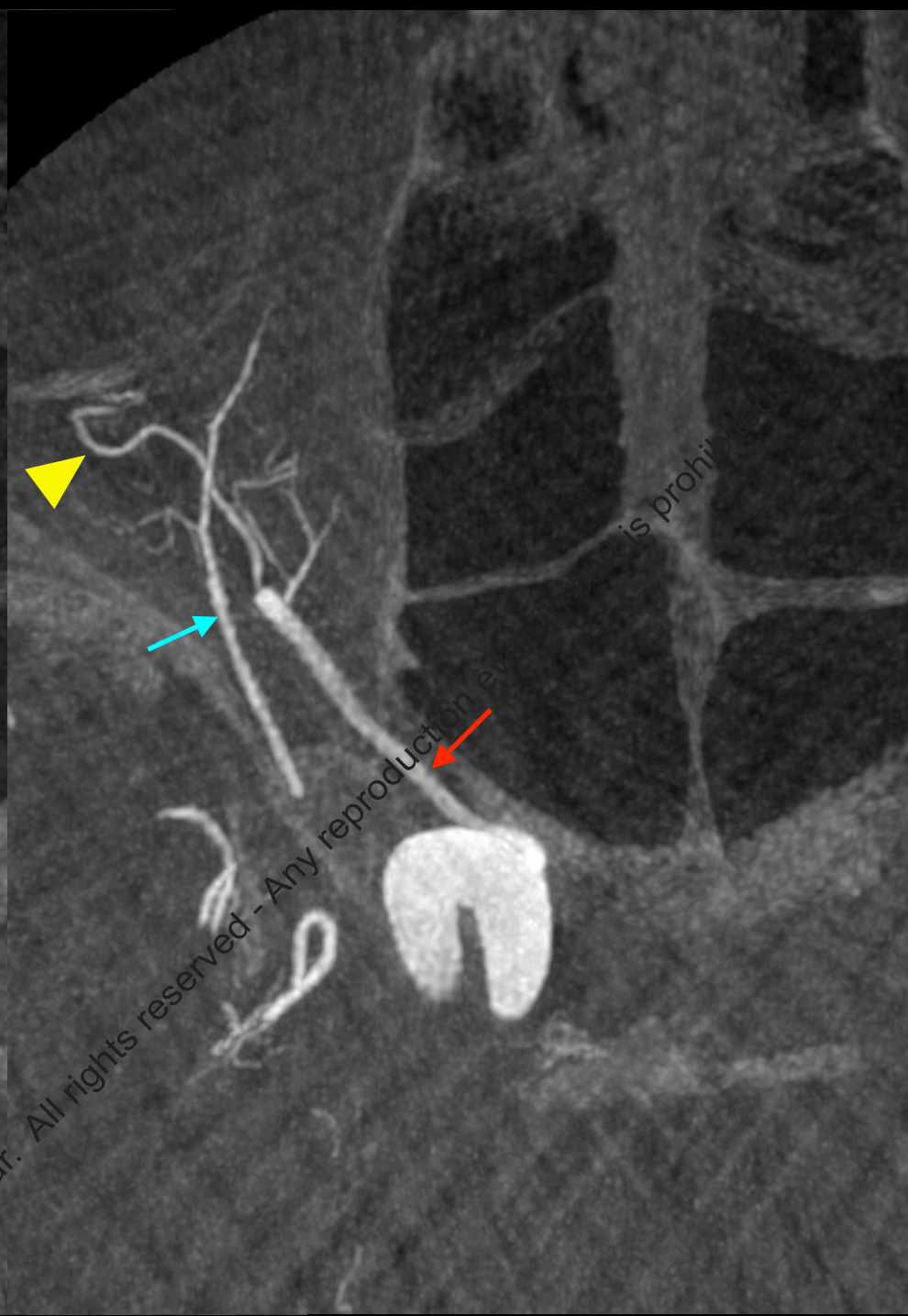
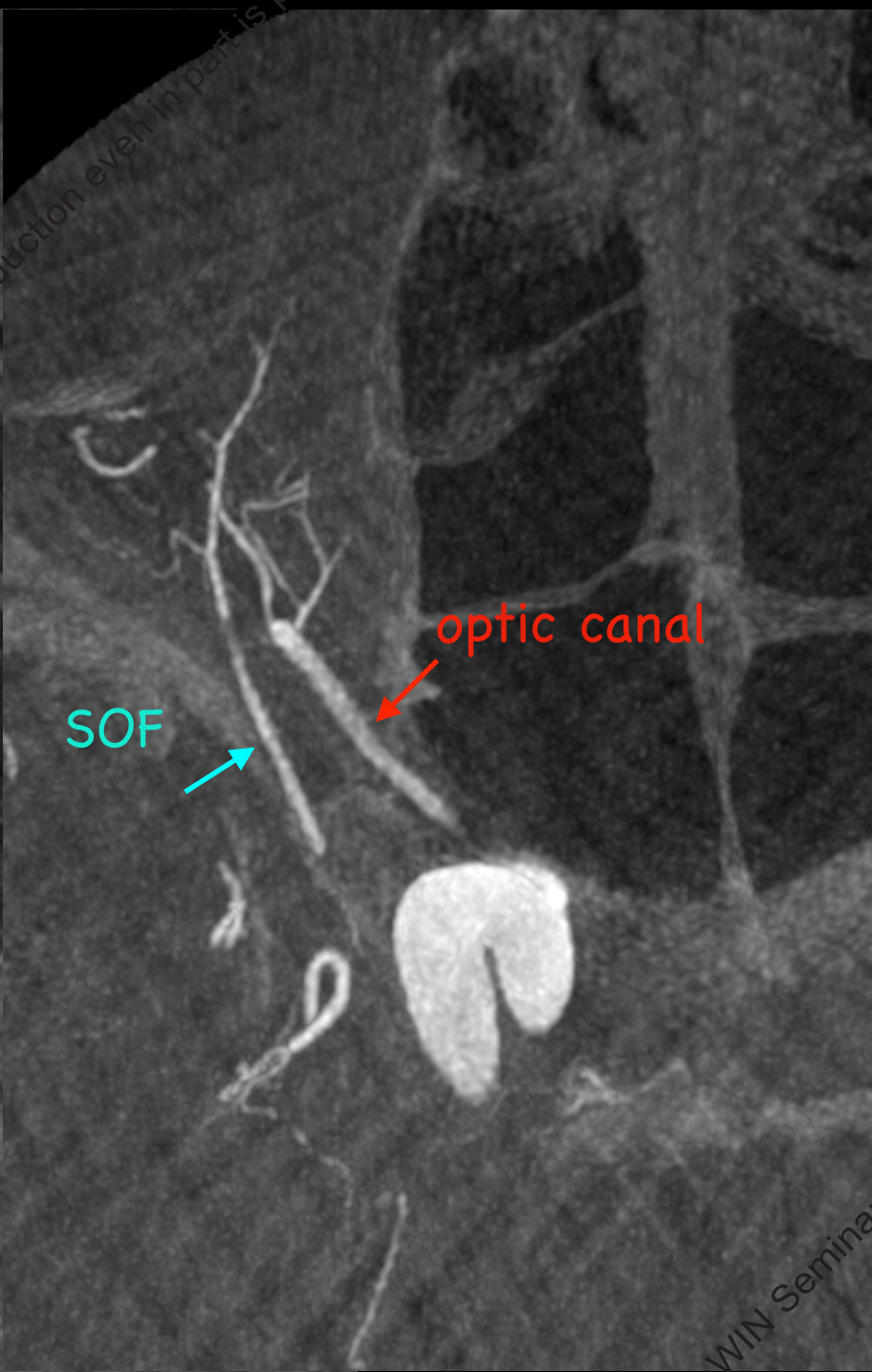
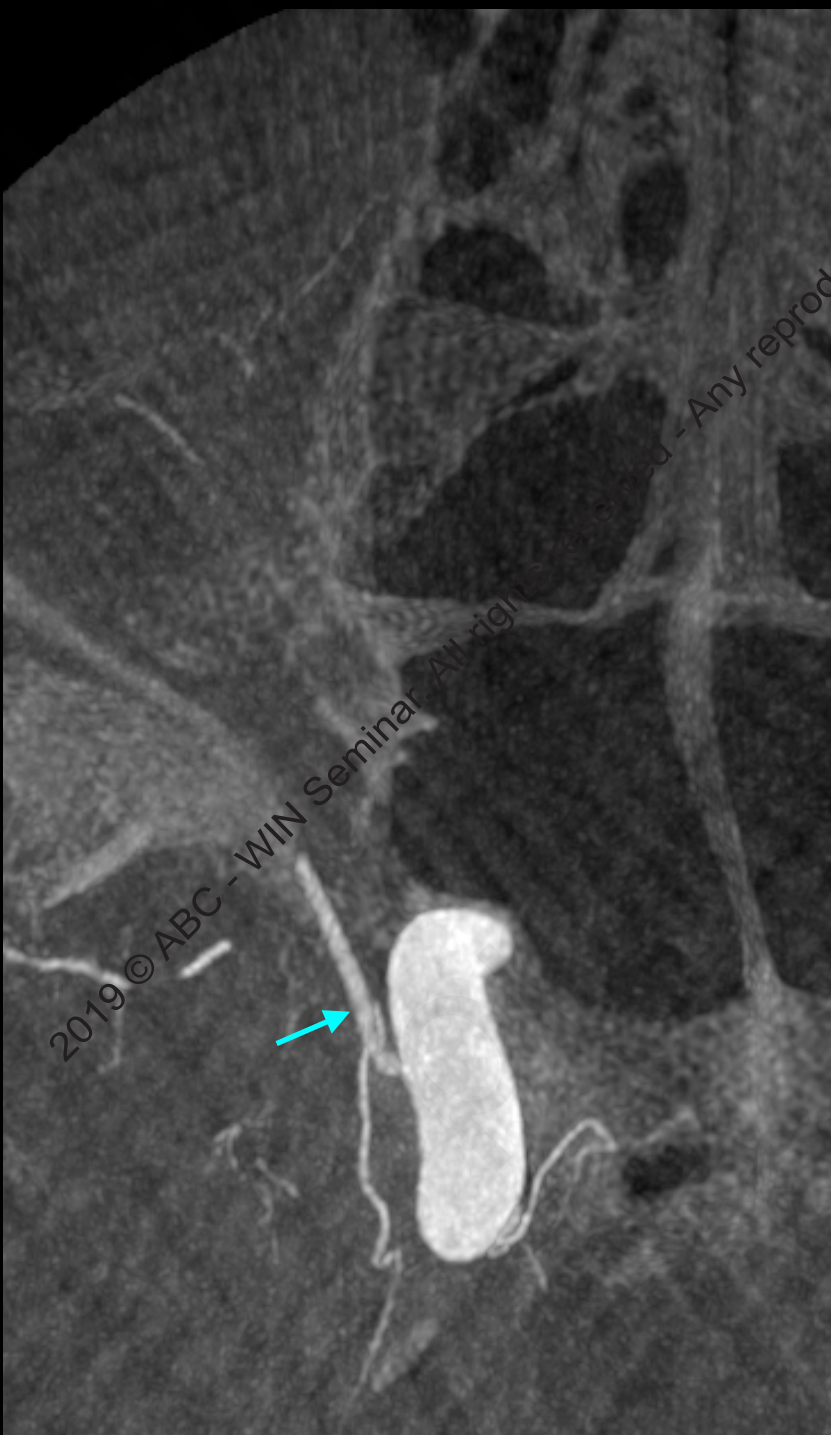

👁️ stereoscopic view



👁️ stereoscopic view

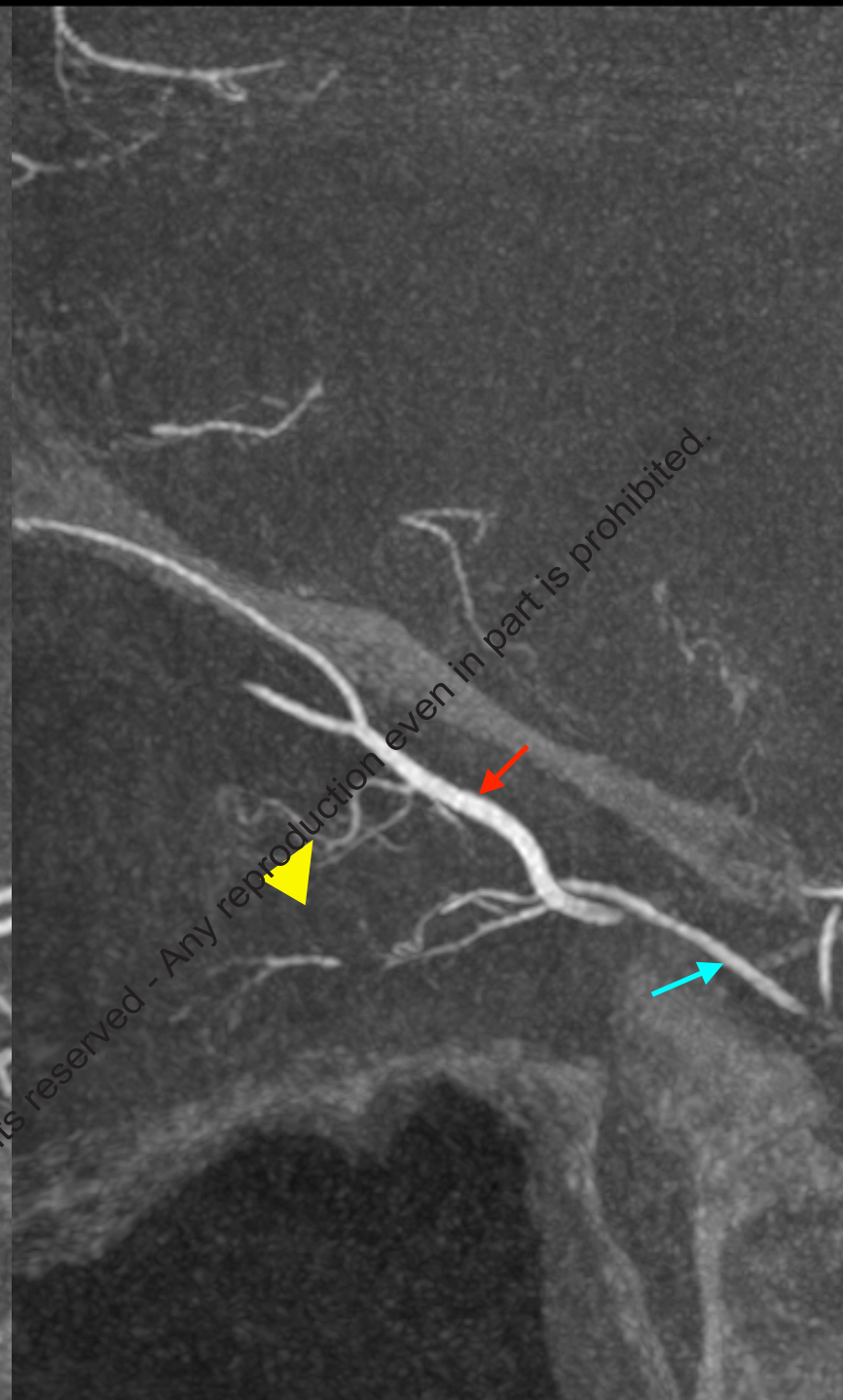
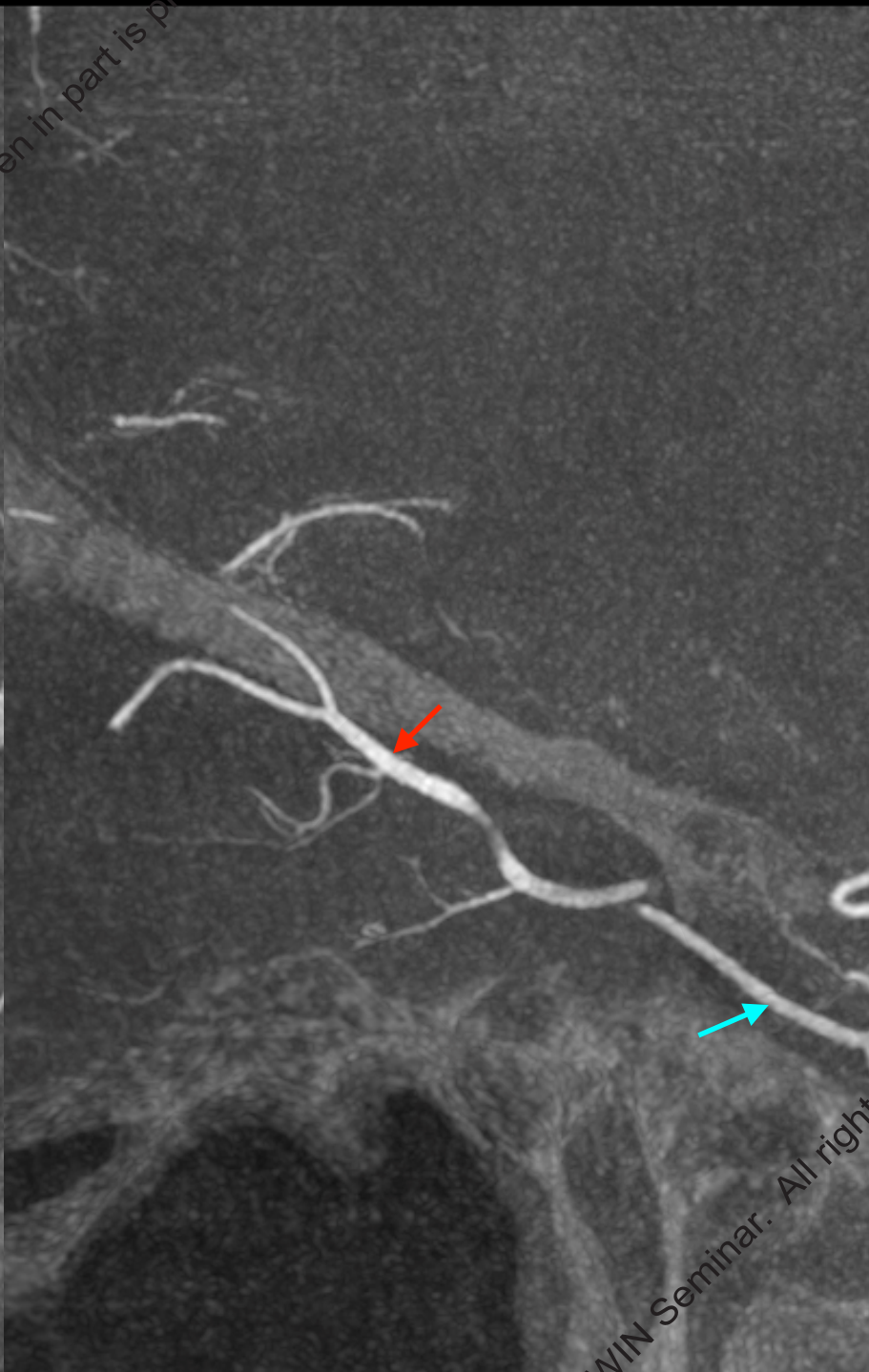
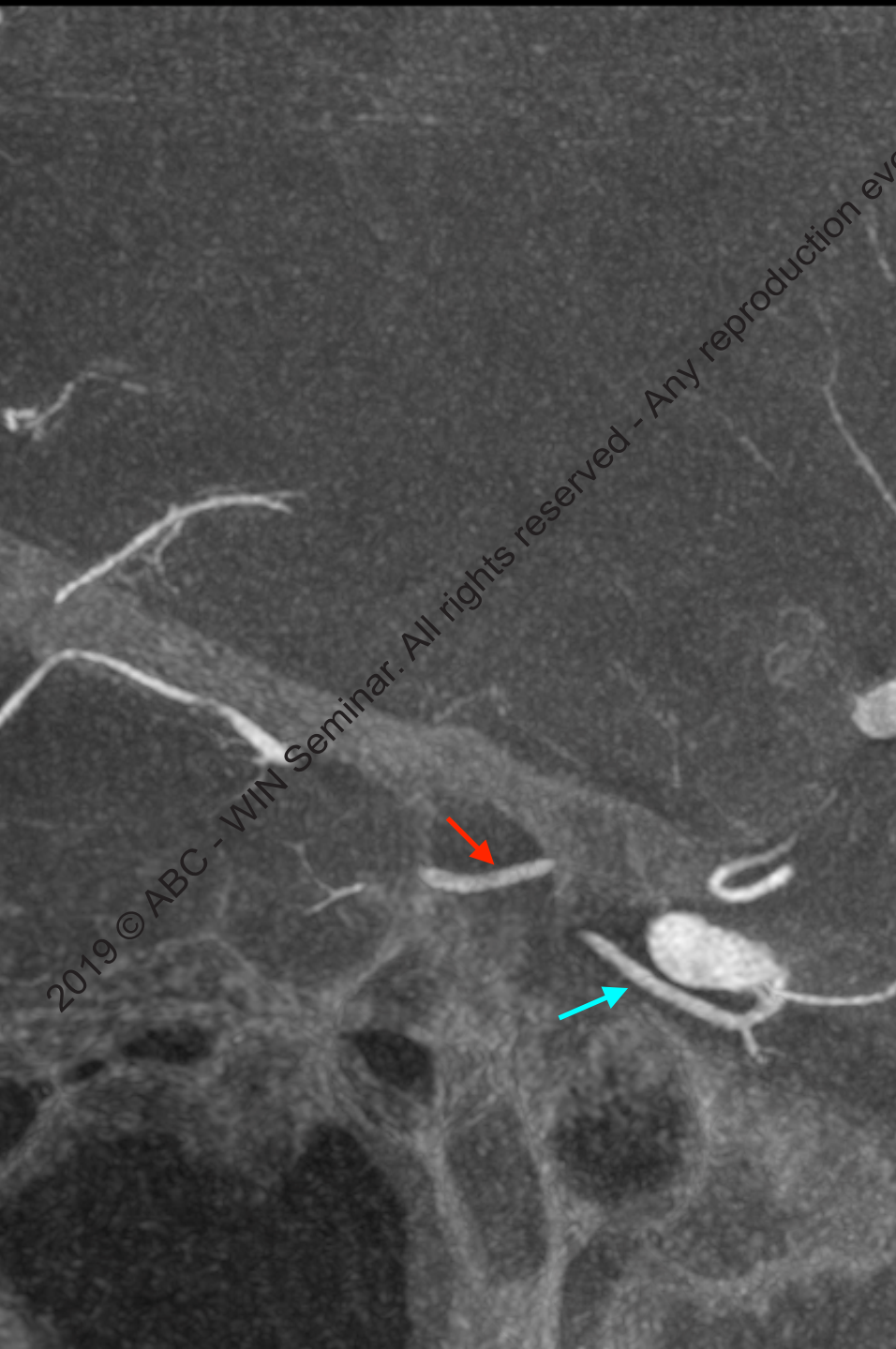




▲ central retinal artery

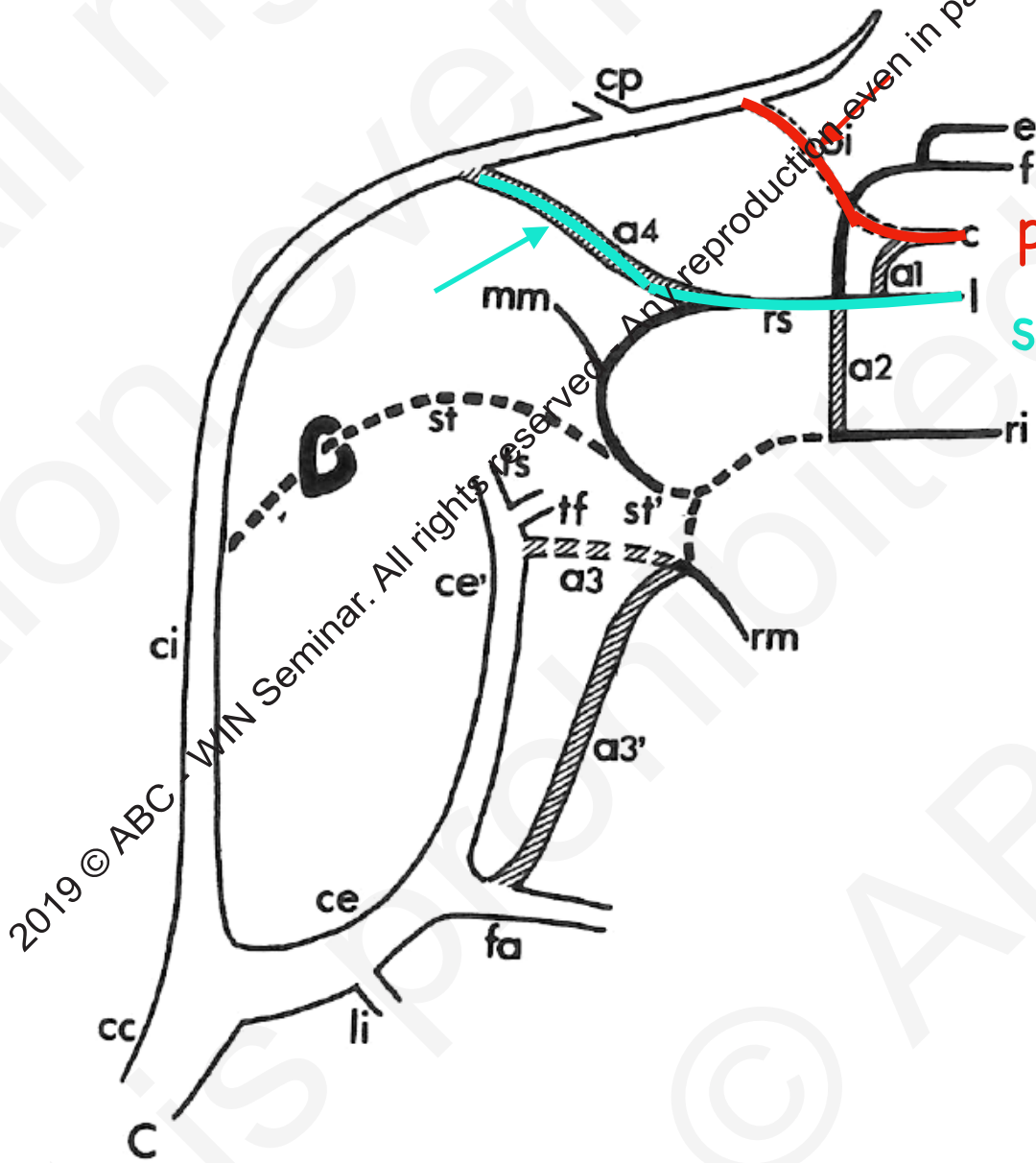


# 16/M: double ophthalmic a + AVM

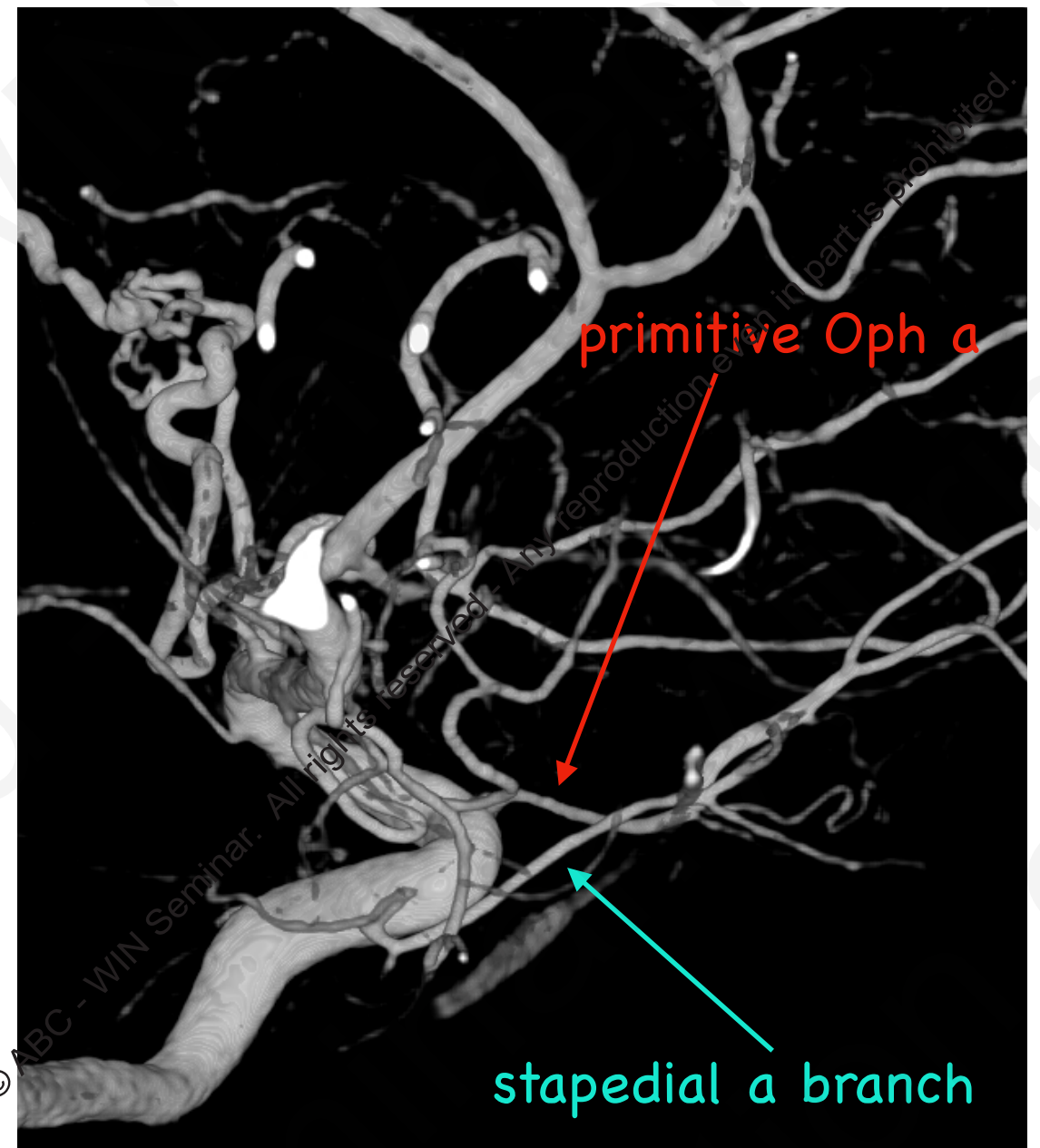


▲ central retinal artery

Misunderstood "ventral and dorsal ophthalmic arteries"  
- double (duplicated) ophthalmic arteries -



primitive Oph a  
stapedial a



2019 © ABC - WIN Seminar. All rights reserved.

2019 © ABC - WIN Seminar. All rights reserved.



# What is the origin of the ILT?

primitive maxillary artery  
(lateral branch of PMA)

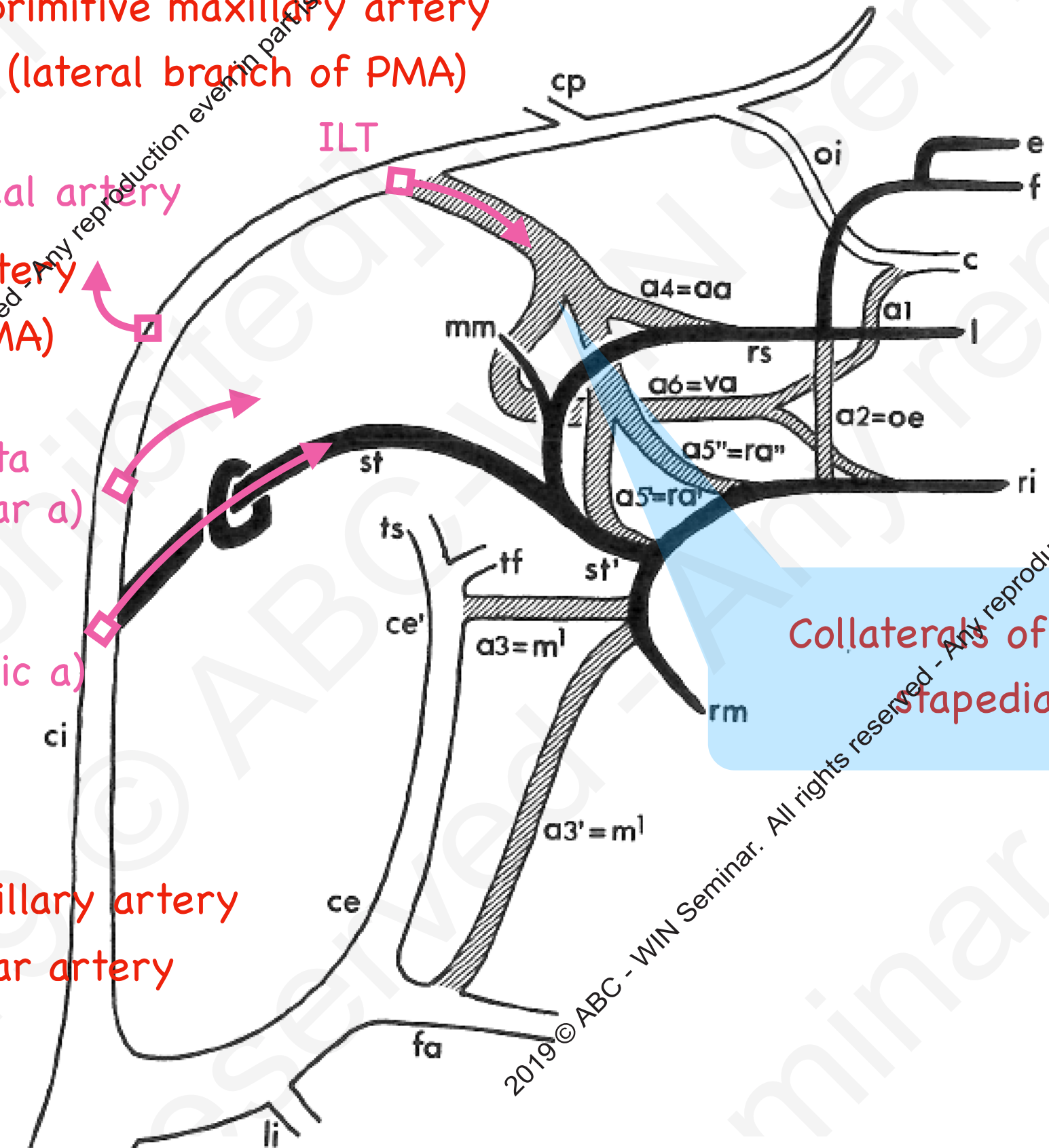
inferior hypophyseal artery

primitive maxillary artery  
(medial branch of PMA)

1st aorta  
(mandibular a)

2nd aorta  
(carotico-tympanic a)

PMA: primitive maxillary artery  
-> pre-mandibular artery

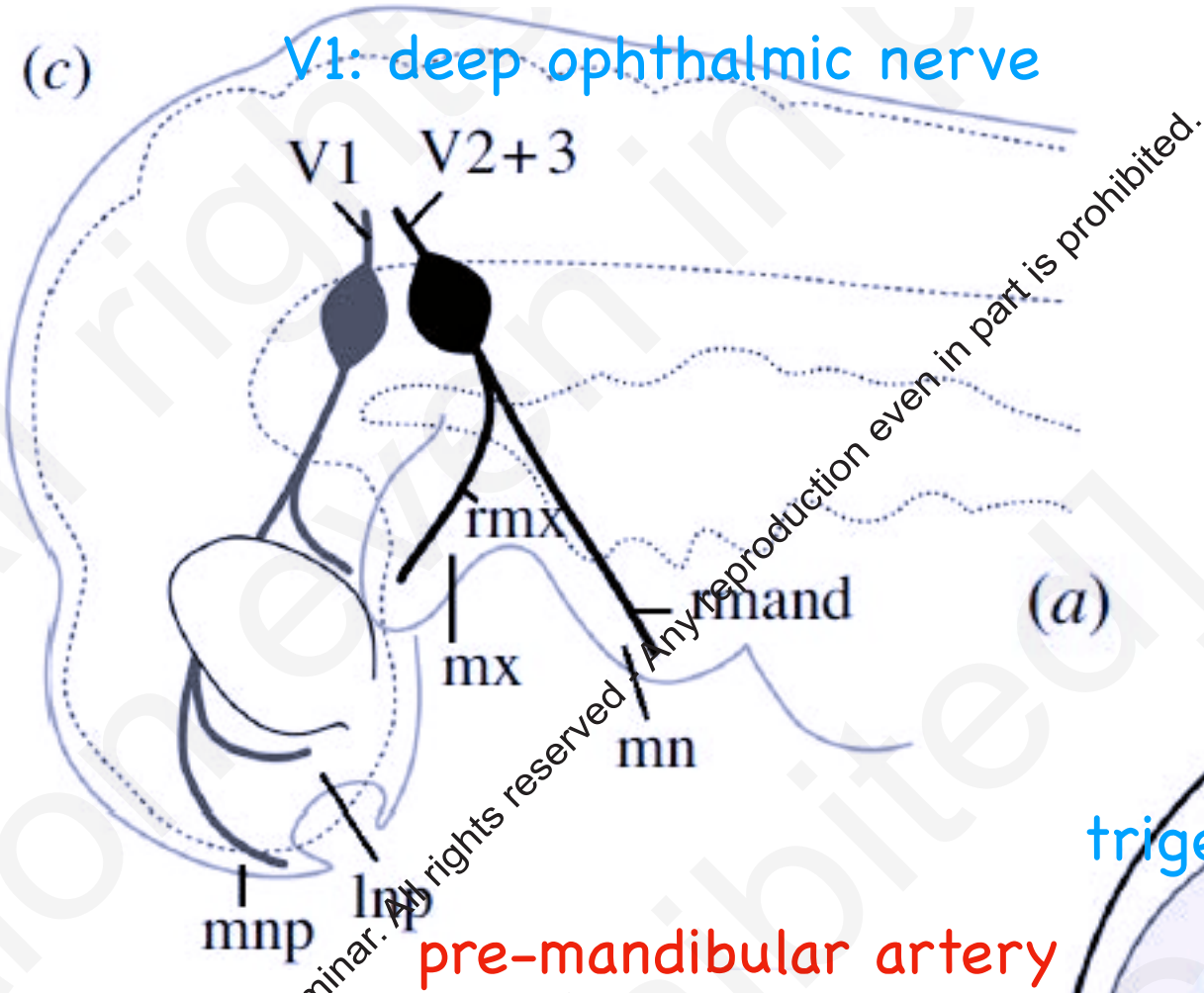


Collaterals of ILT are all of stapedial artery.

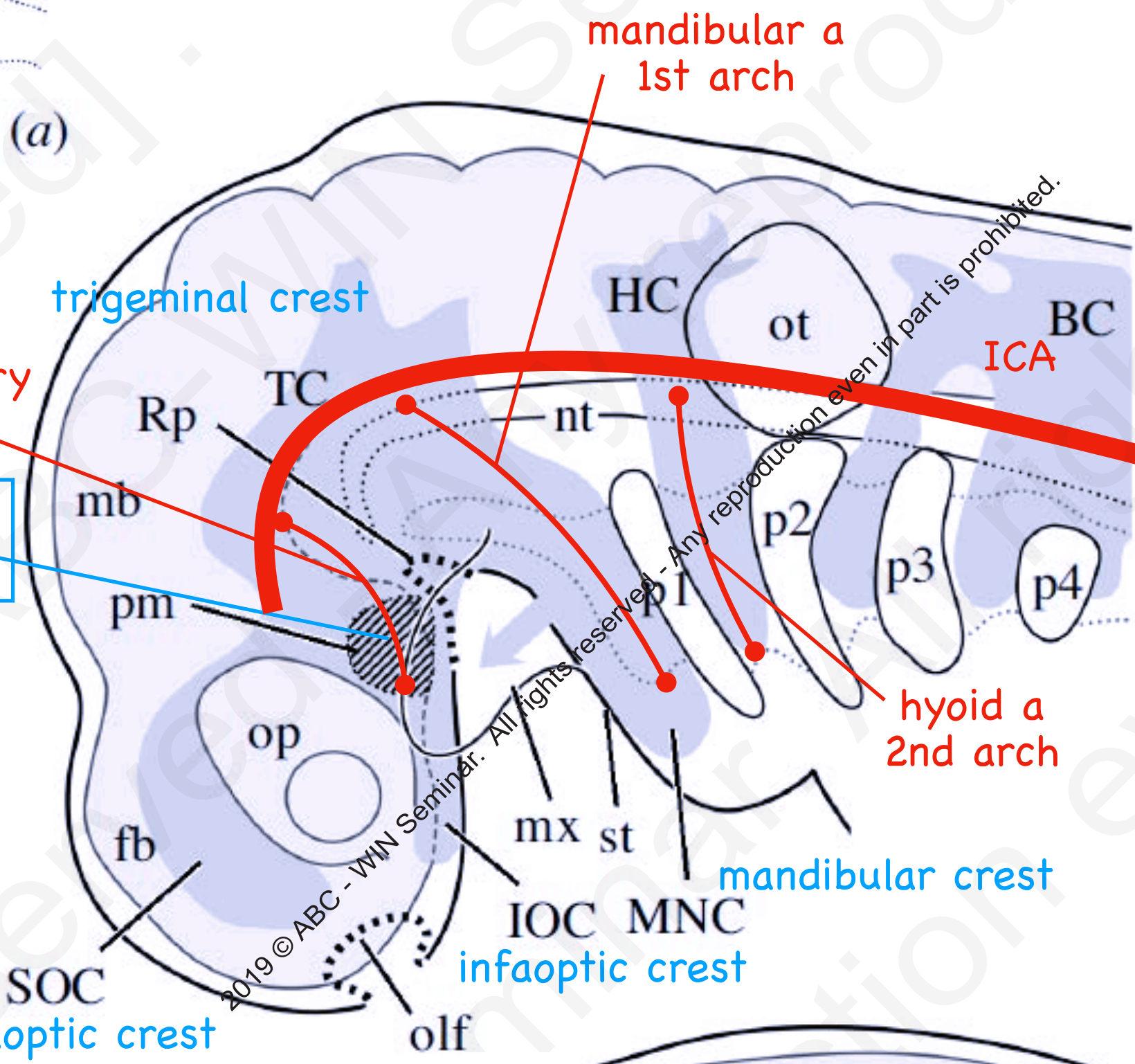
2019 © ABC - WIN Seminar. All rights reserved. Any reproduction even in part is prohibited.

2019 © ABC - WIN Seminar. All rights reserved. Any reproduction even in part is prohibited.

# Basic vertebrate model



2019 © ABC - WIN Seminar. All rights reserved. Any reproduction even in part is prohibited.



2019 © ABC - WIN Seminar. All rights reserved. Any reproduction even in part is prohibited.

pre-mandibular mesoderm

pre-mandibular artery  
 ILT

Arteries in red color are added to the illustration from Kuratani S 2001



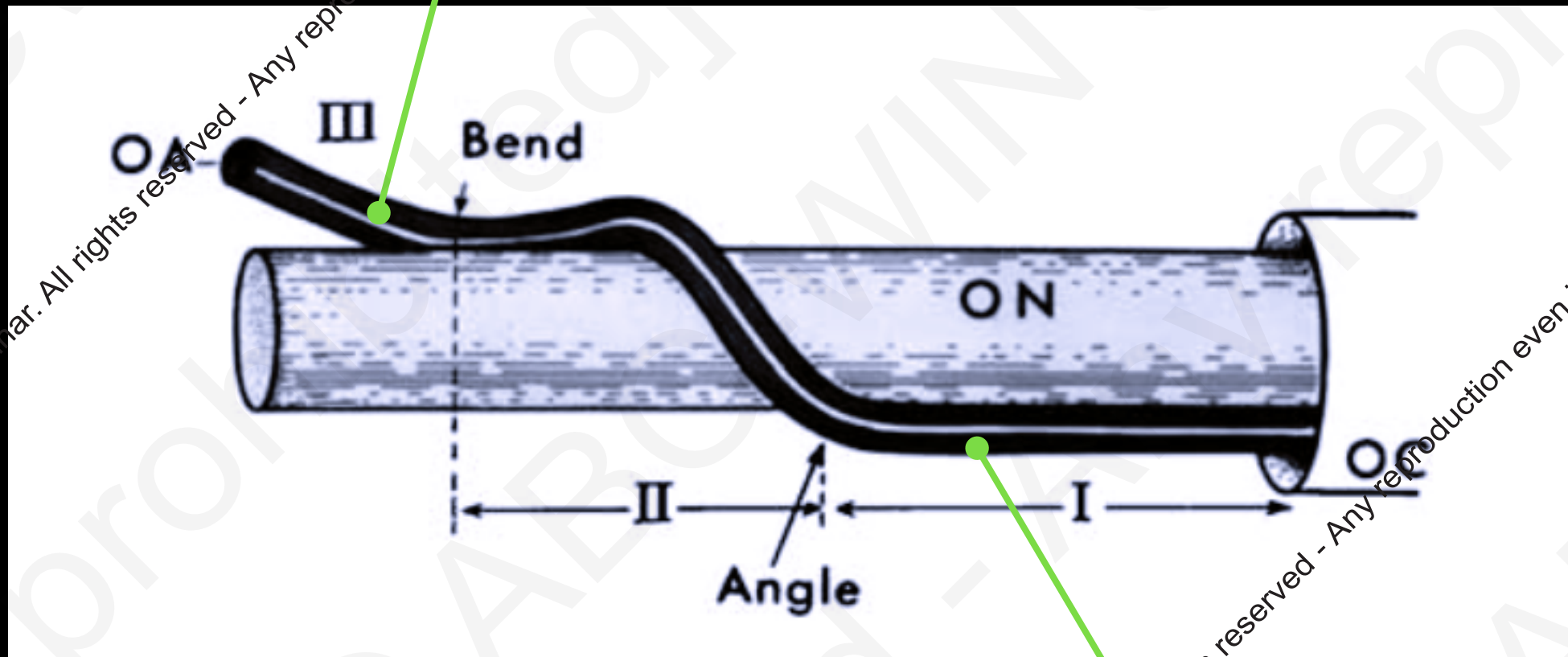
2019 © ABC - WIN Seminar. All rights reserved - Any reproduction even in part is prohibited.

# Orbital structures

2019 © ABC - WIN Seminar. All rights reserved - Any reproduction even in part is prohibited.

# Three segments of infraorbital ophthalmic artery

III portion: supero-medial course



I portion: infero-lateral course

in the case of cross-over course (83%)

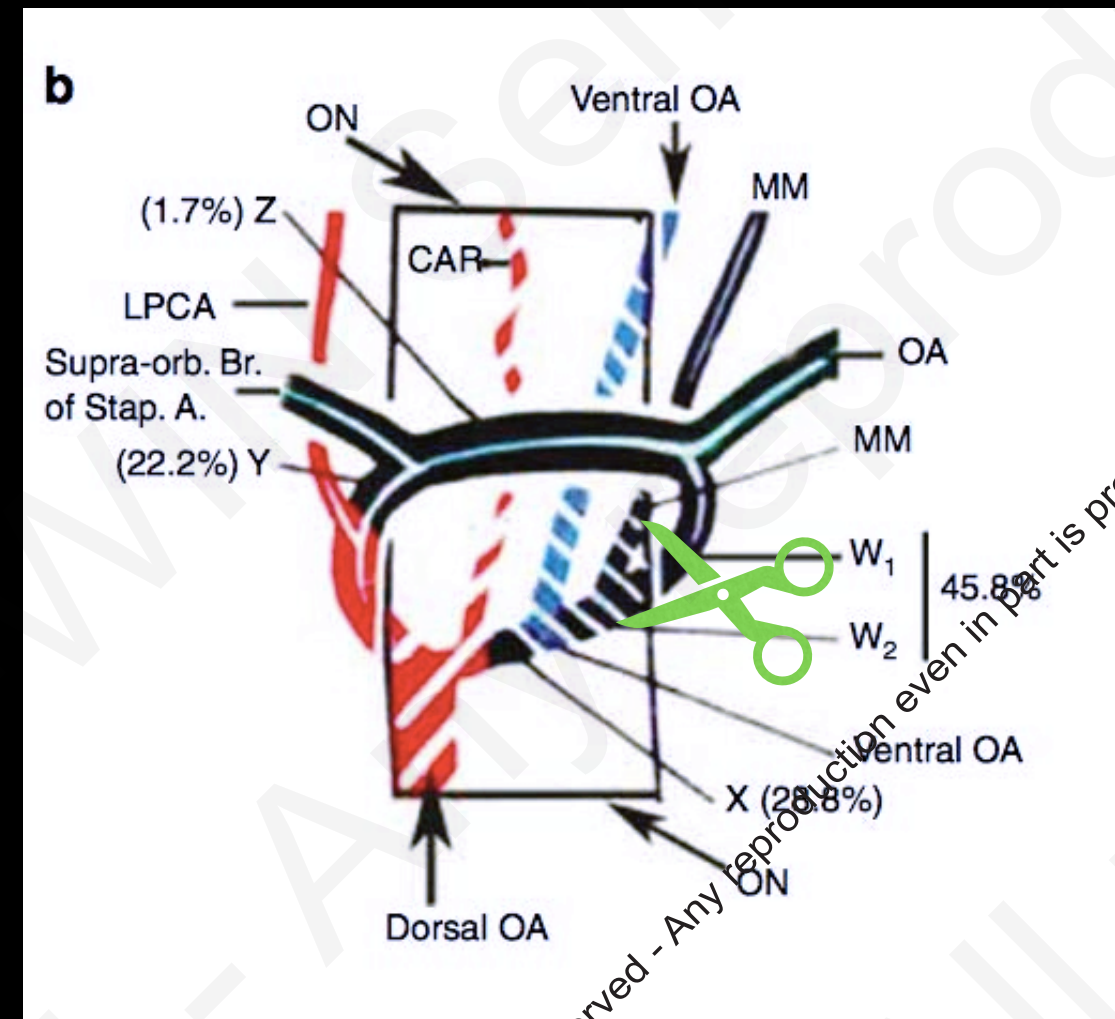
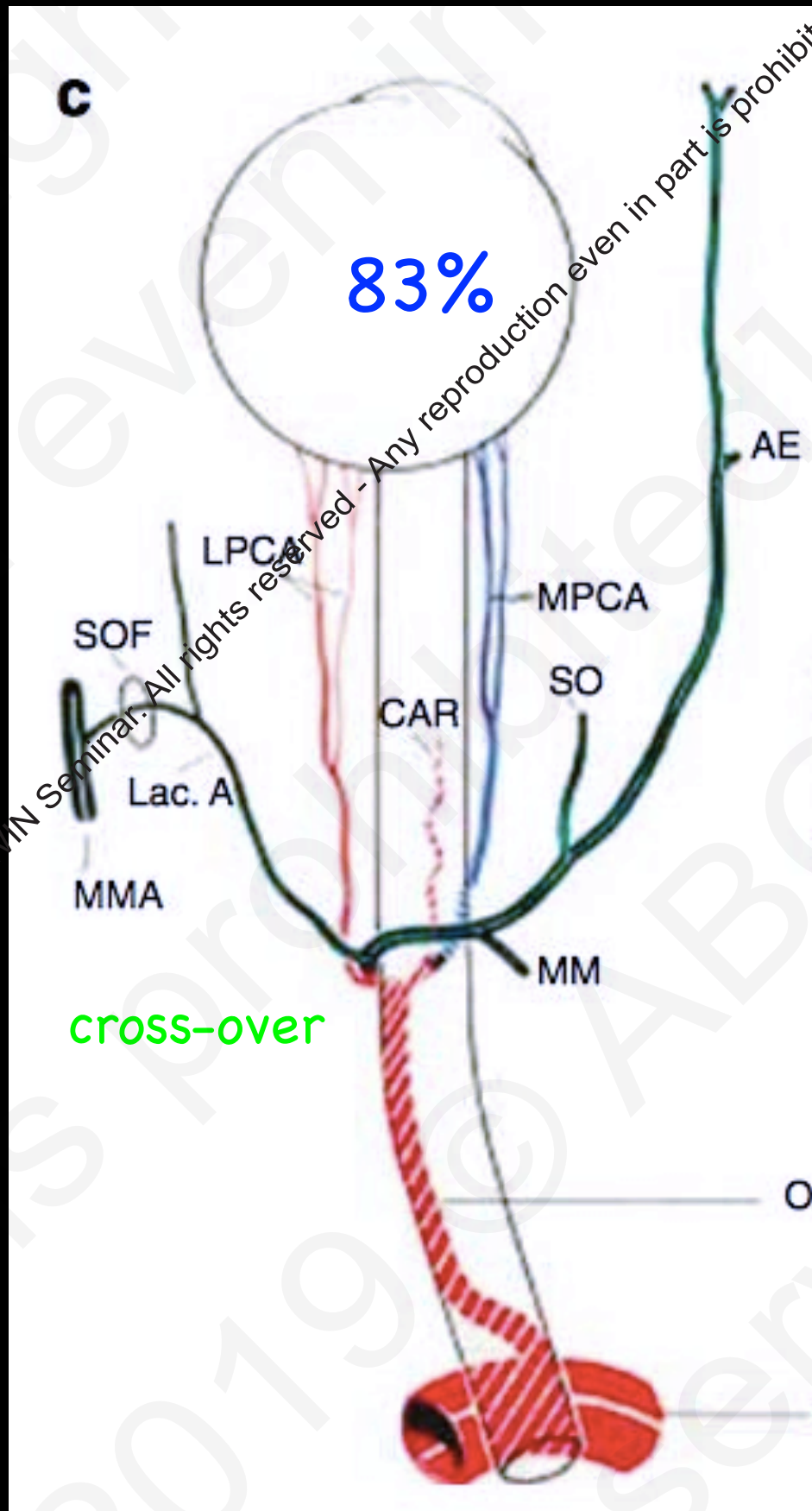








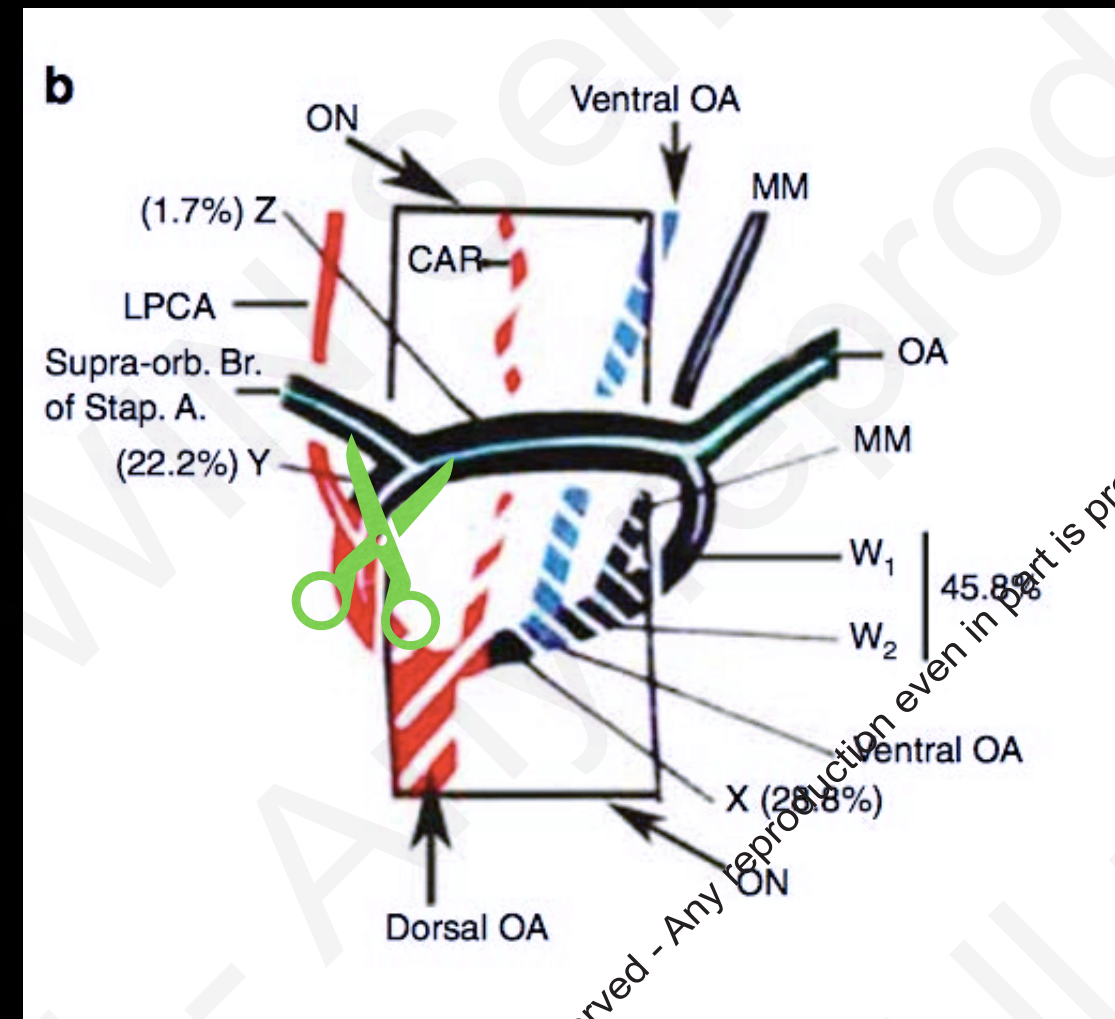
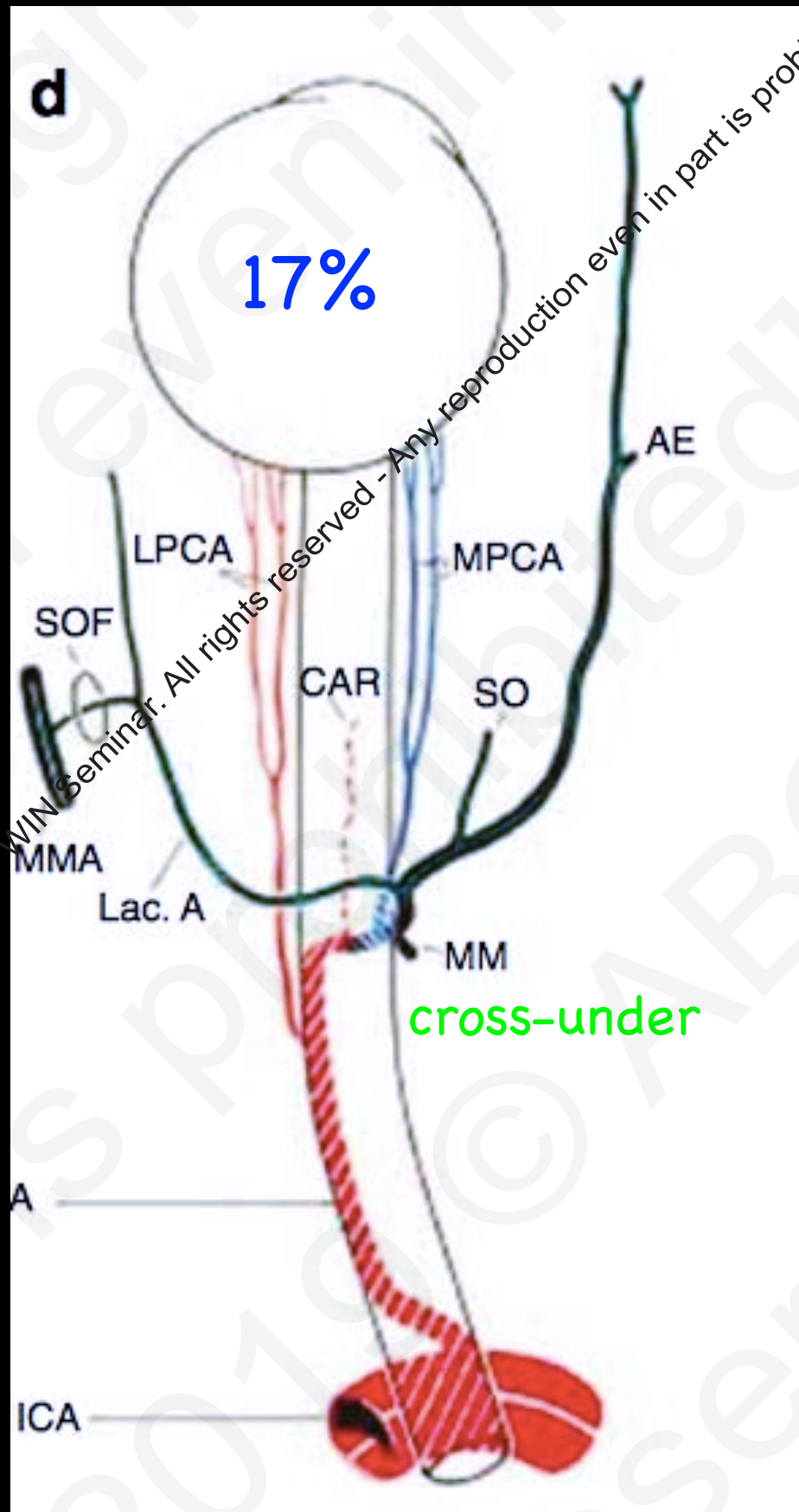
# Crossing-over ophthalmic artery



proximal: CRA + MPCA  
distal: LPCA

 regression

# Crossing-under ophthalmic artery

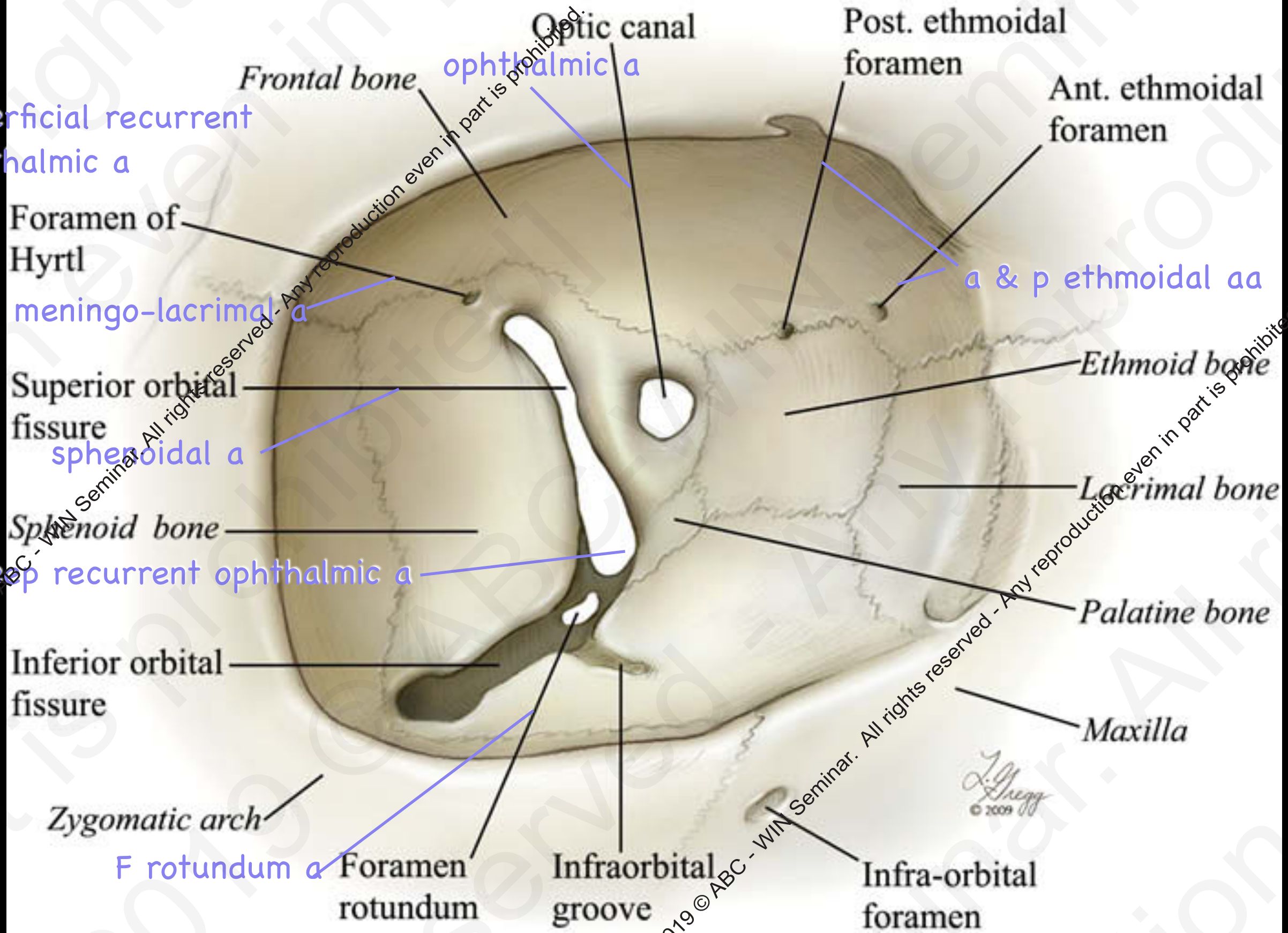


proximal: LPCA  
 then: CRA  
 distal: MPCA

 regression



superficial recurrent  
ophthalmic a



Foramen of  
Hyrtl

meningo-lacrimal a

Superior orbital  
fissure

sphenoidal a

Sphenoid bone

deep recurrent ophthalmic a

Inferior orbital  
fissure

Zygomatic arch

F rotundum a

Foramen  
rotundum

Infraorbital  
groove

Infra-orbital  
foramen

Optic canal

ophthalmic a

Frontal bone

Post. ethmoidal  
foramen

Ant. ethmoidal  
foramen

a & p ethmoidal aa

Ethmoid bone

Lacrimal bone

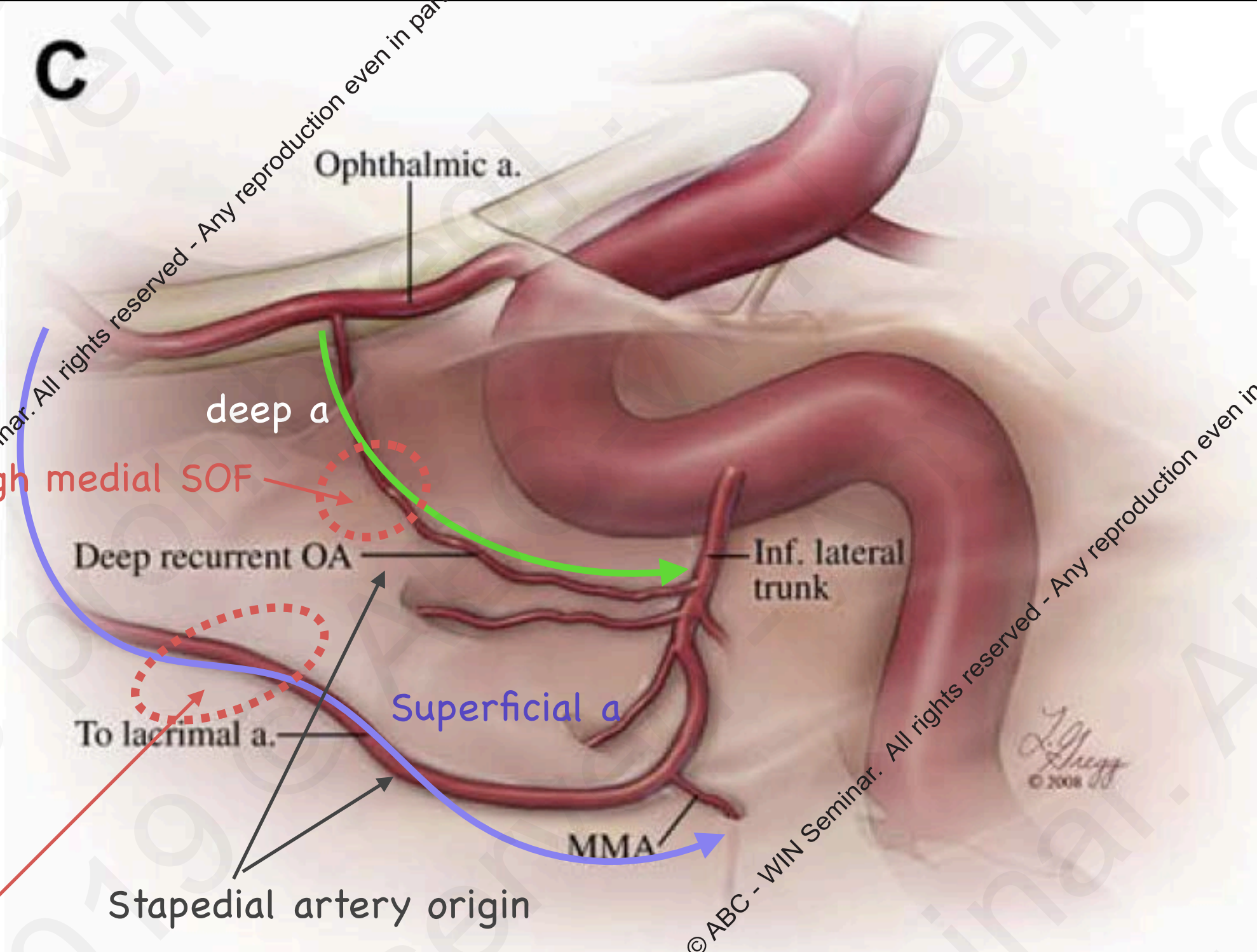
Palatine bone

Maxilla





# Superficial and deep recurrent meningeal (ophthalmic) arteries



through lateral SOF or Hyrtl canal

# Ophthalmic artery of the MMA origin (stapedial supply)

persistent stapedial artery

regressed primitive ophthalmic artery

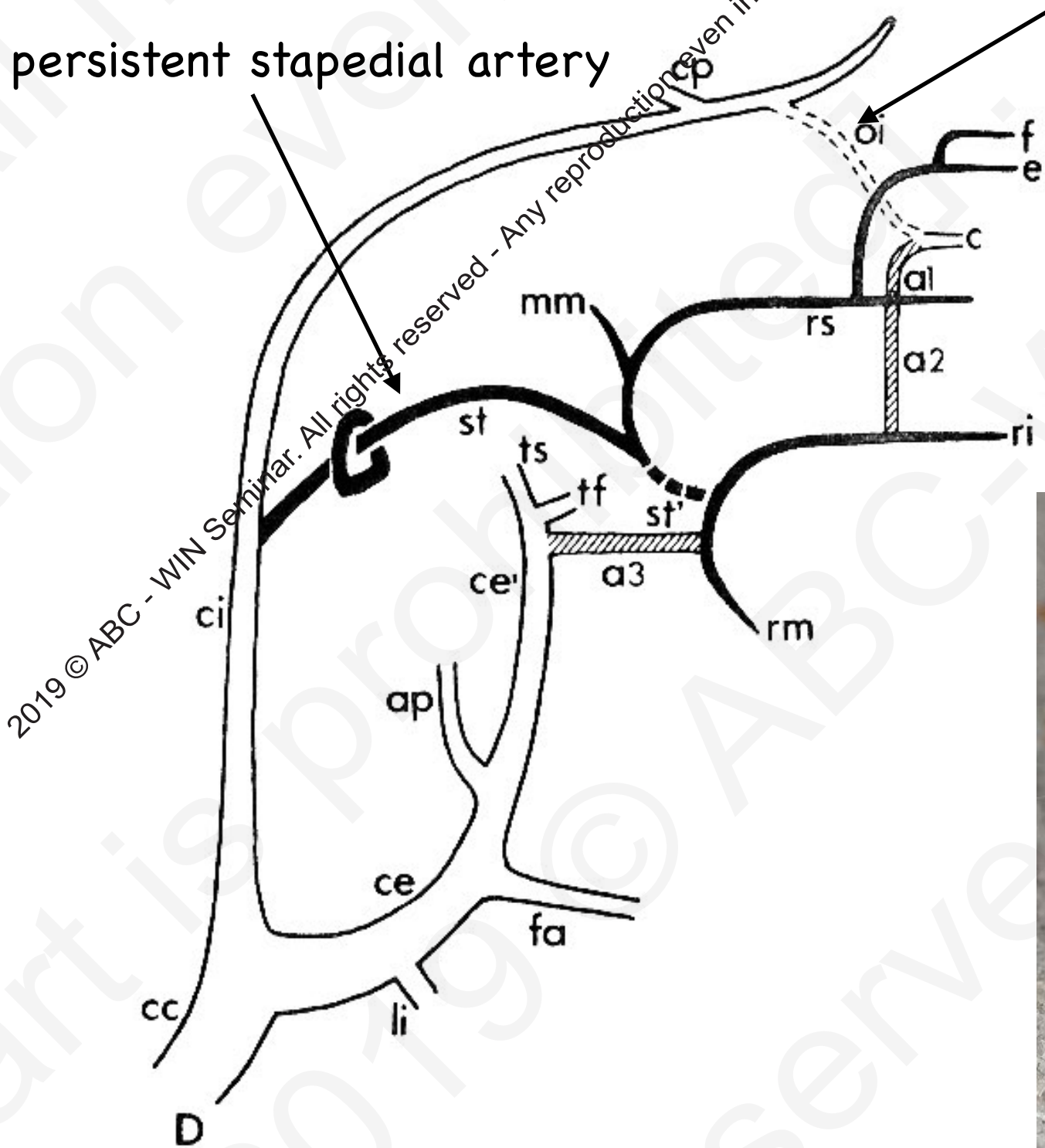
through medial SOF

-> **deep recurrent meningeal a**

through lateral SOF or lacrimal foramen

-> **superficial recurrent meningeal a**

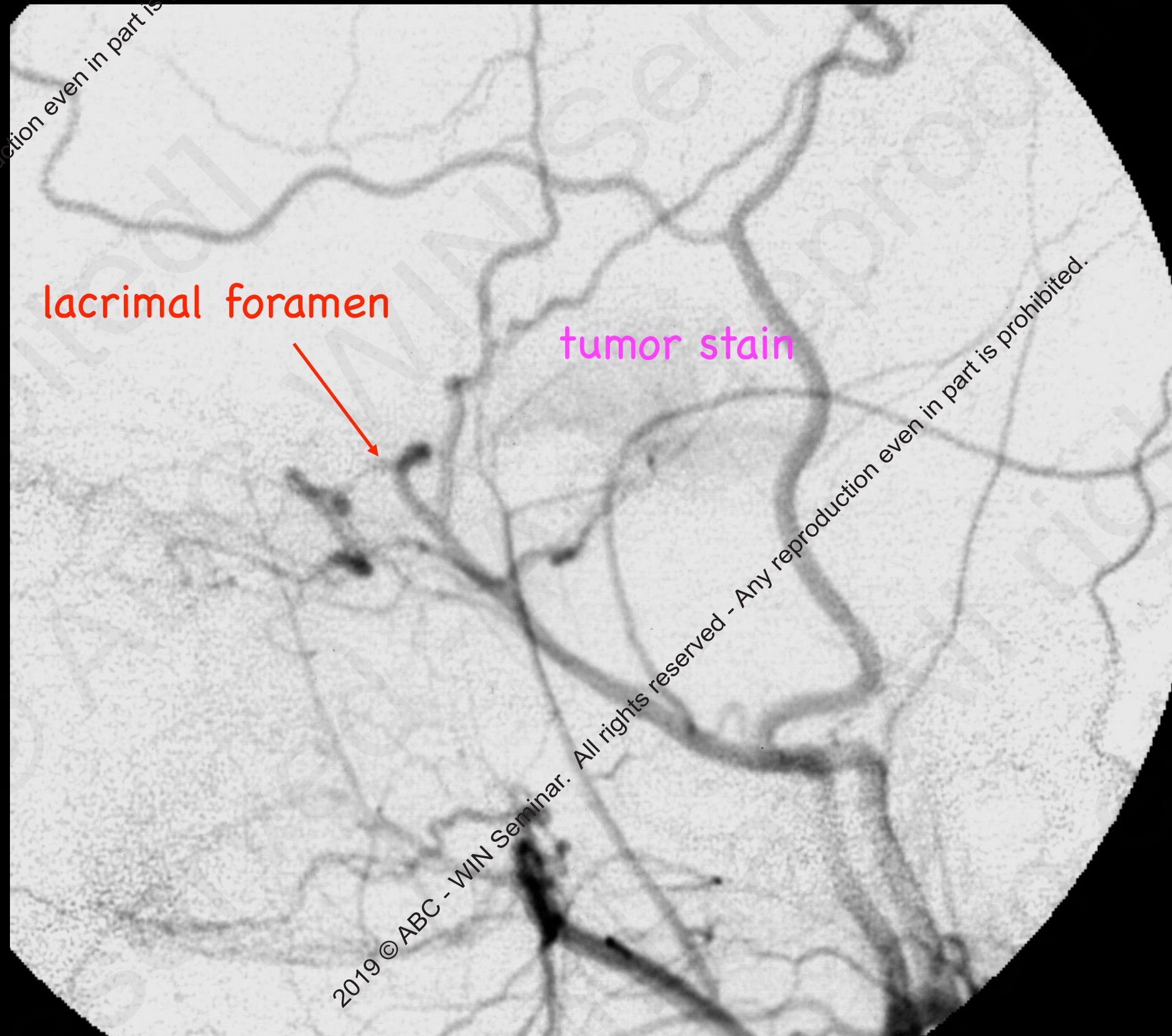
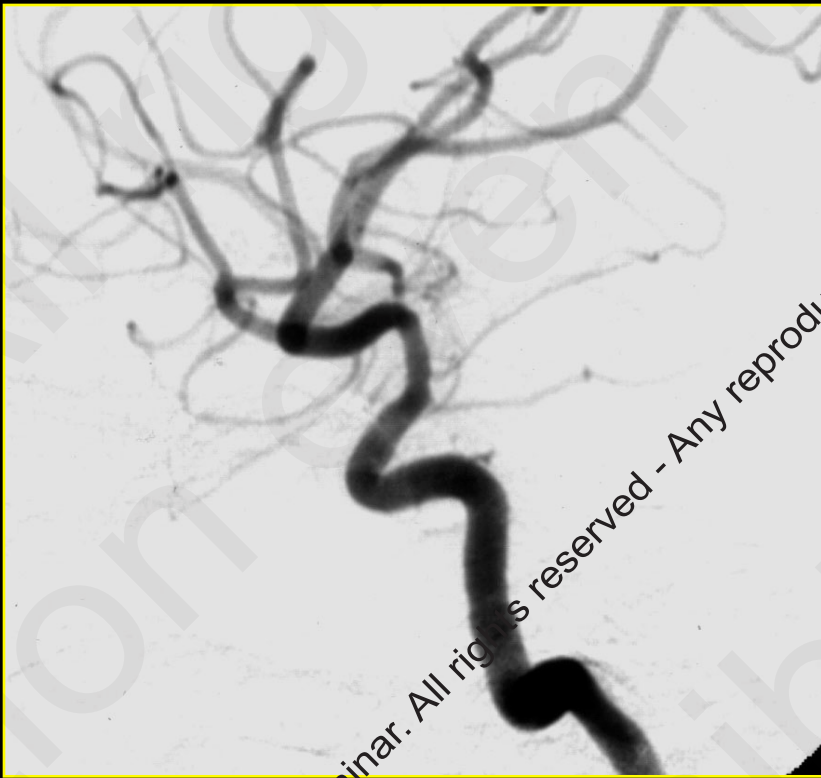
meningo-ophthalmic a  
sphenoidal a



Perognathus

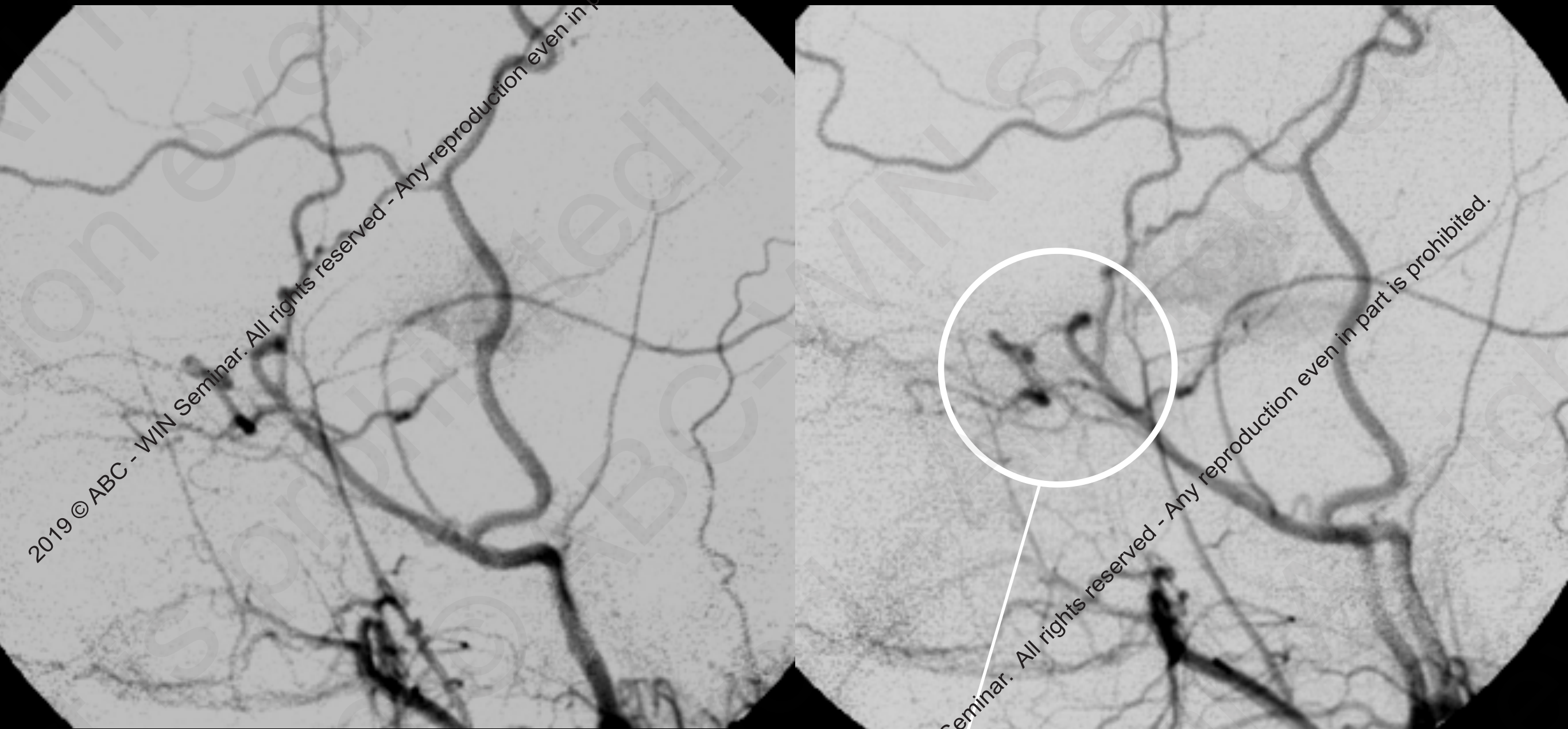


# Lacrimal foramen (Hyrtl foramen) and ophthalmic artery of MMA origin



29/F: meningioma

# Lacrimal foramen and ophthalmic artery of MMA origin



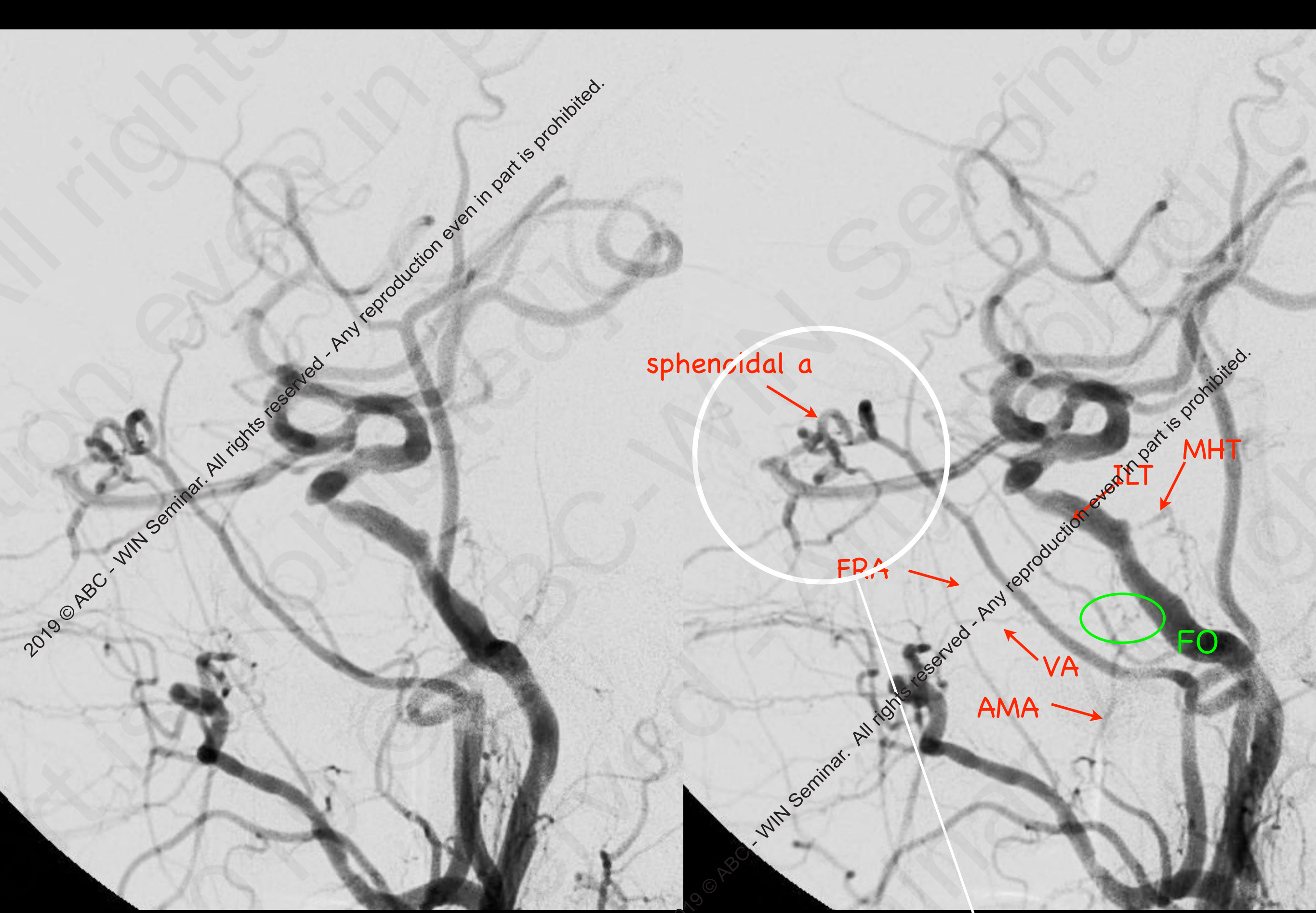
short and straight course

29/F: meningioma

👁️ stereoscopic view



2019 © ABC - WIN Seminar. All rights reserved - Any reproduction even in part is prohibited.



sphenoidal a

FPA

VA

AMA

LT

MHT

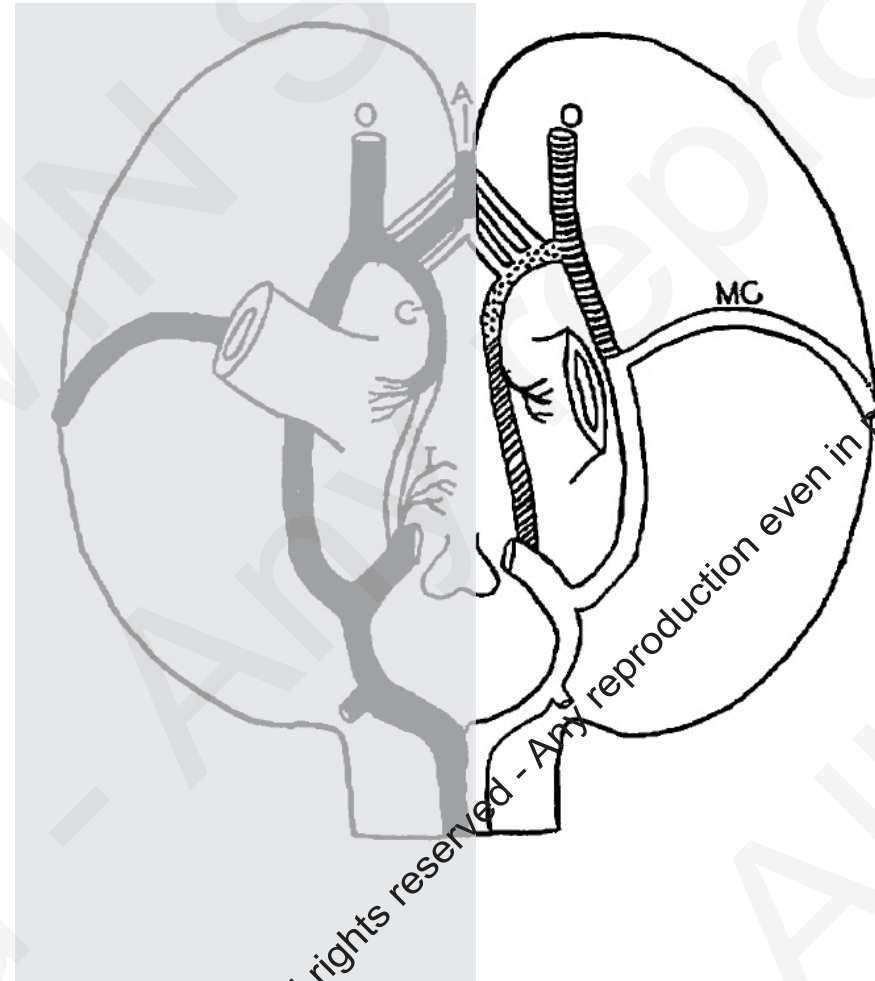
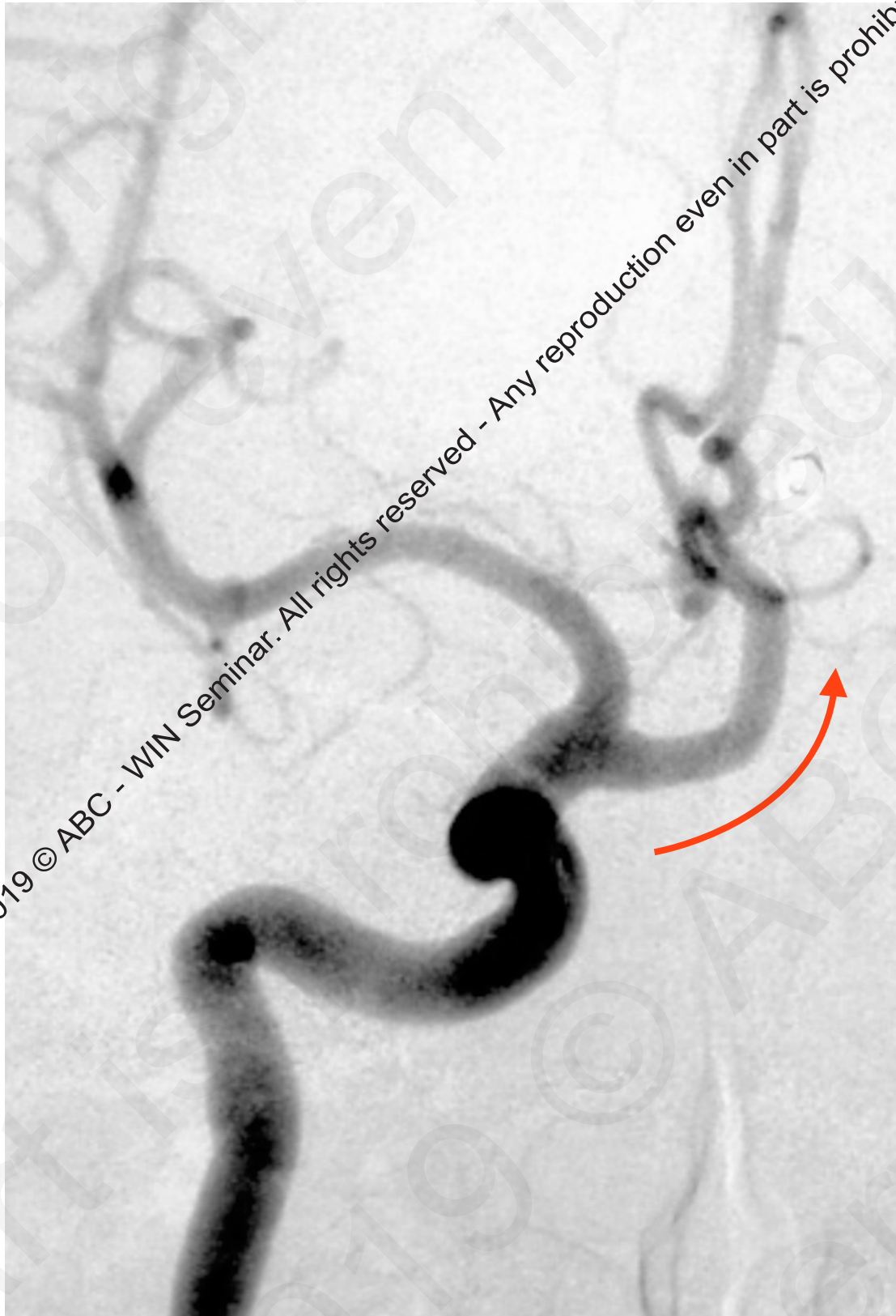
FO

carotid stenosis

👁️ stereoscopic view

long and tortuous course

# Infraoptic course of ACA

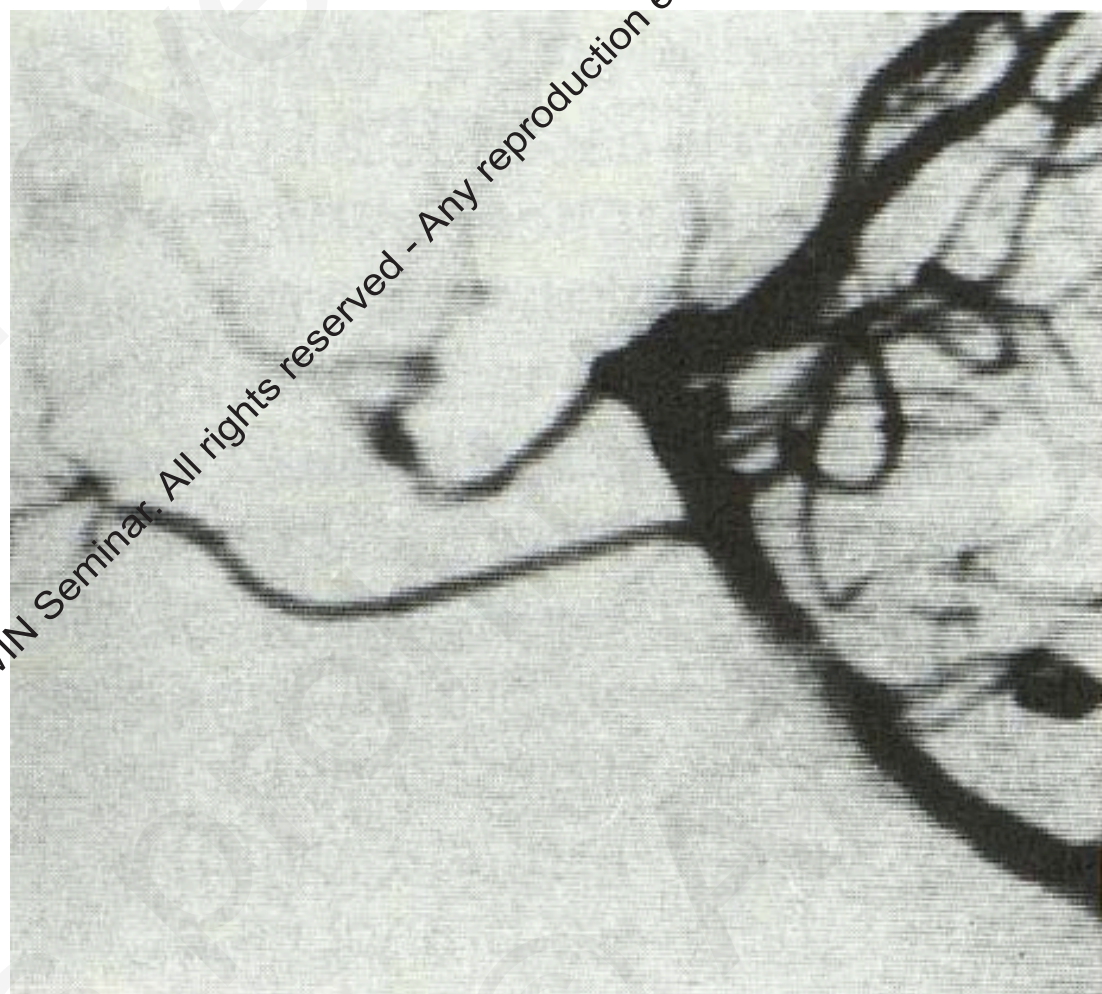


Moffat DB 1961

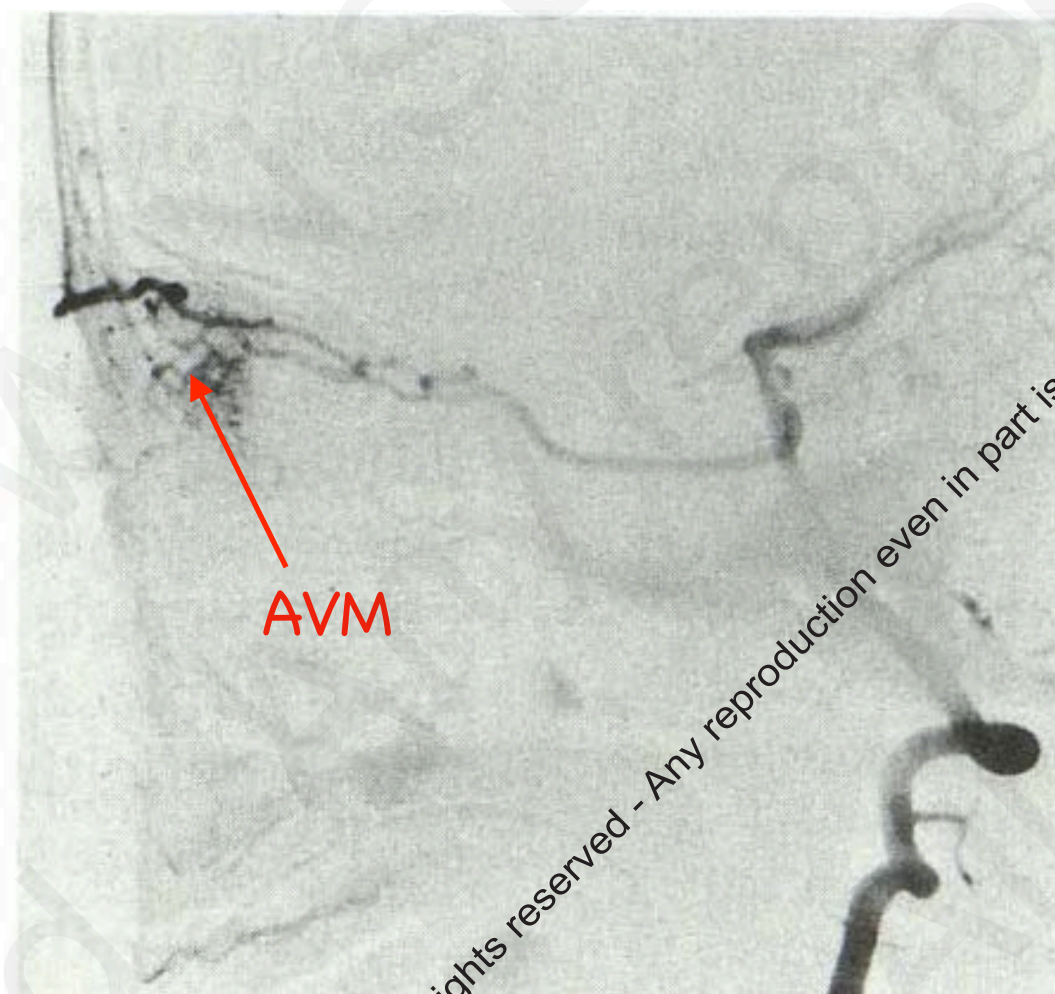
probably related to either chiasmatic branches of primitive olfactory and/or primitive maxillary (pre-mandibular) artery in origin



# Ophthalmic artery of the basilar artery origin



Right VAG with right carotid compression

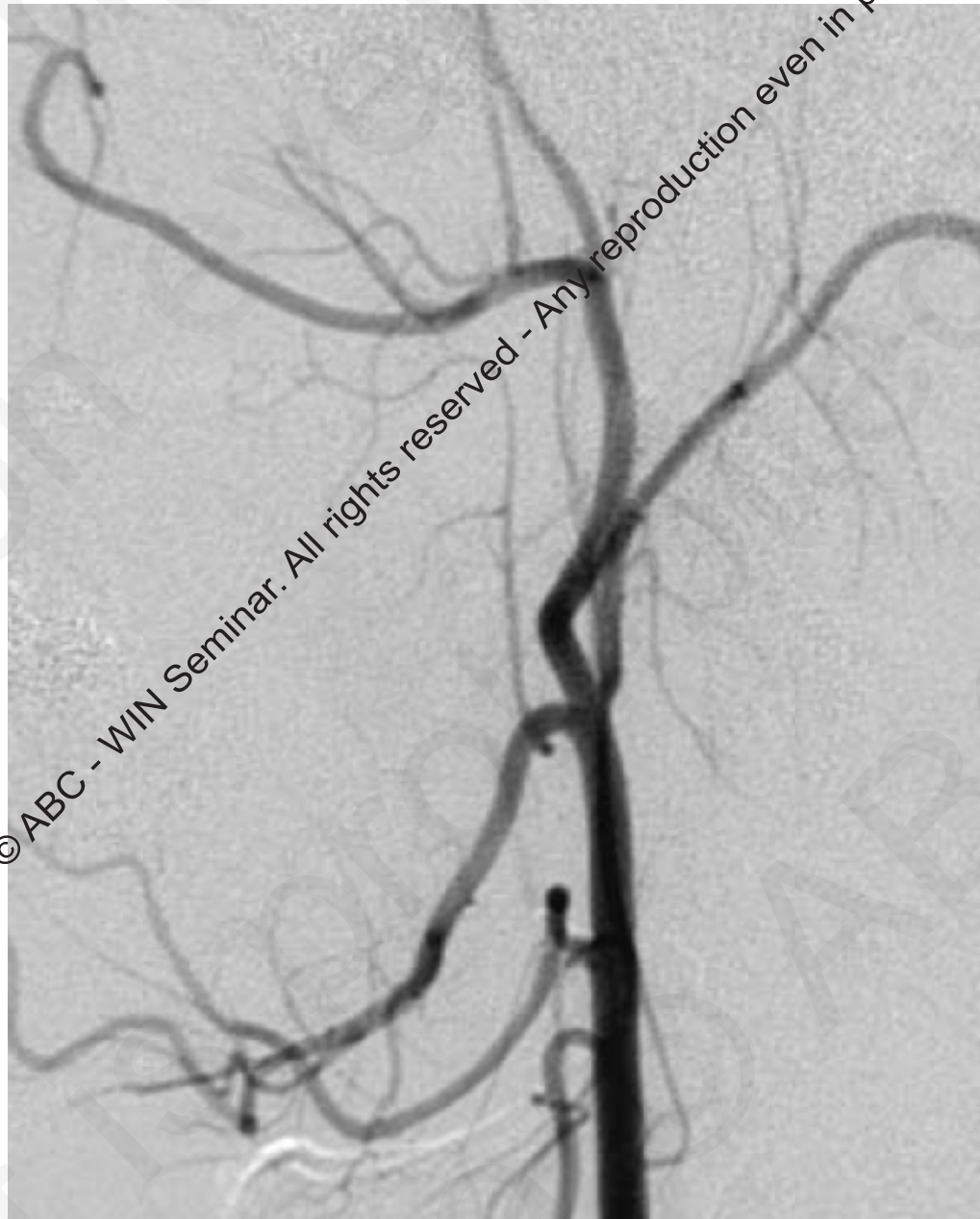

Right VAG

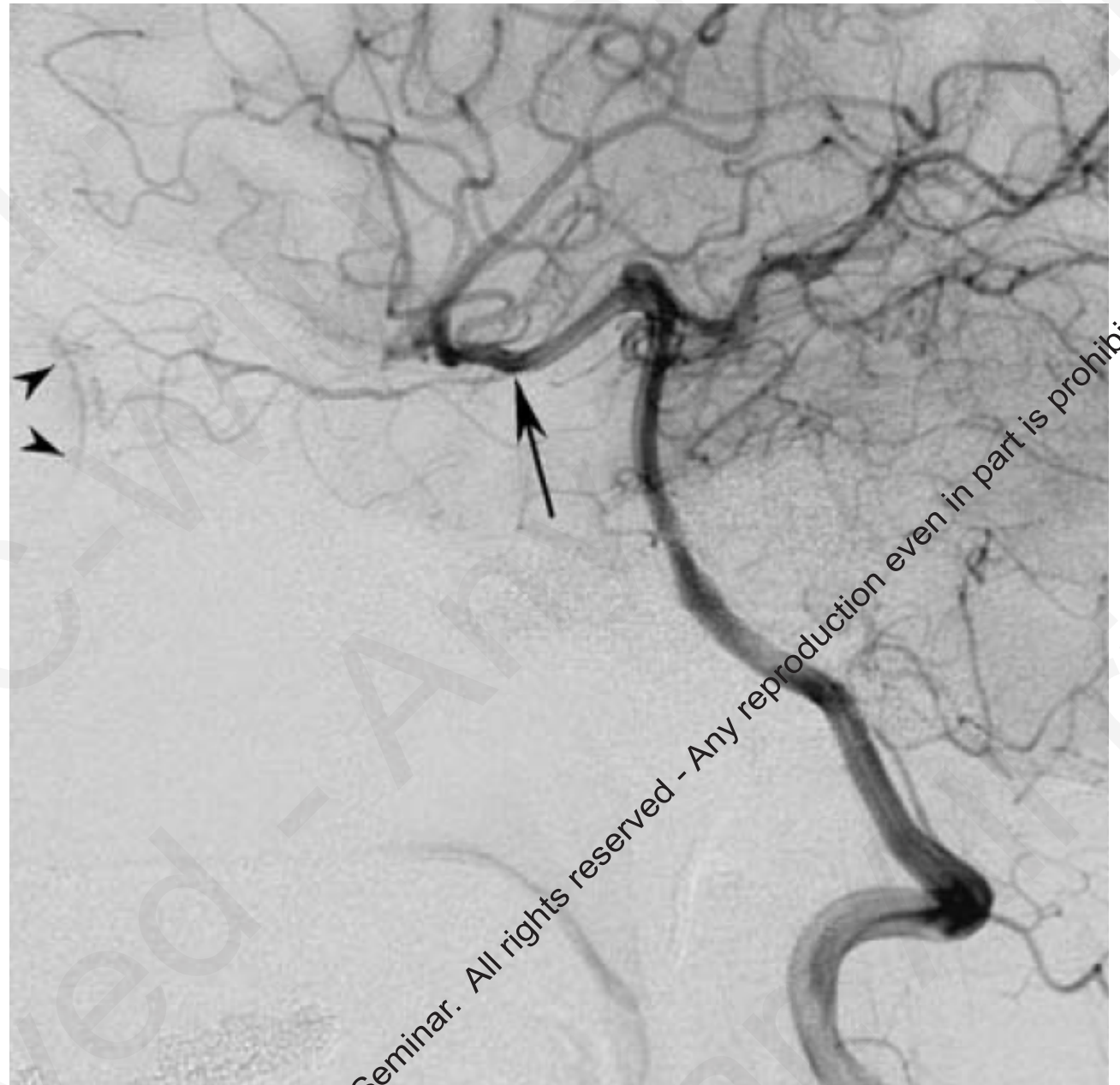




# Ophthalmic artery of the p-com origin



Right ICA agenesis

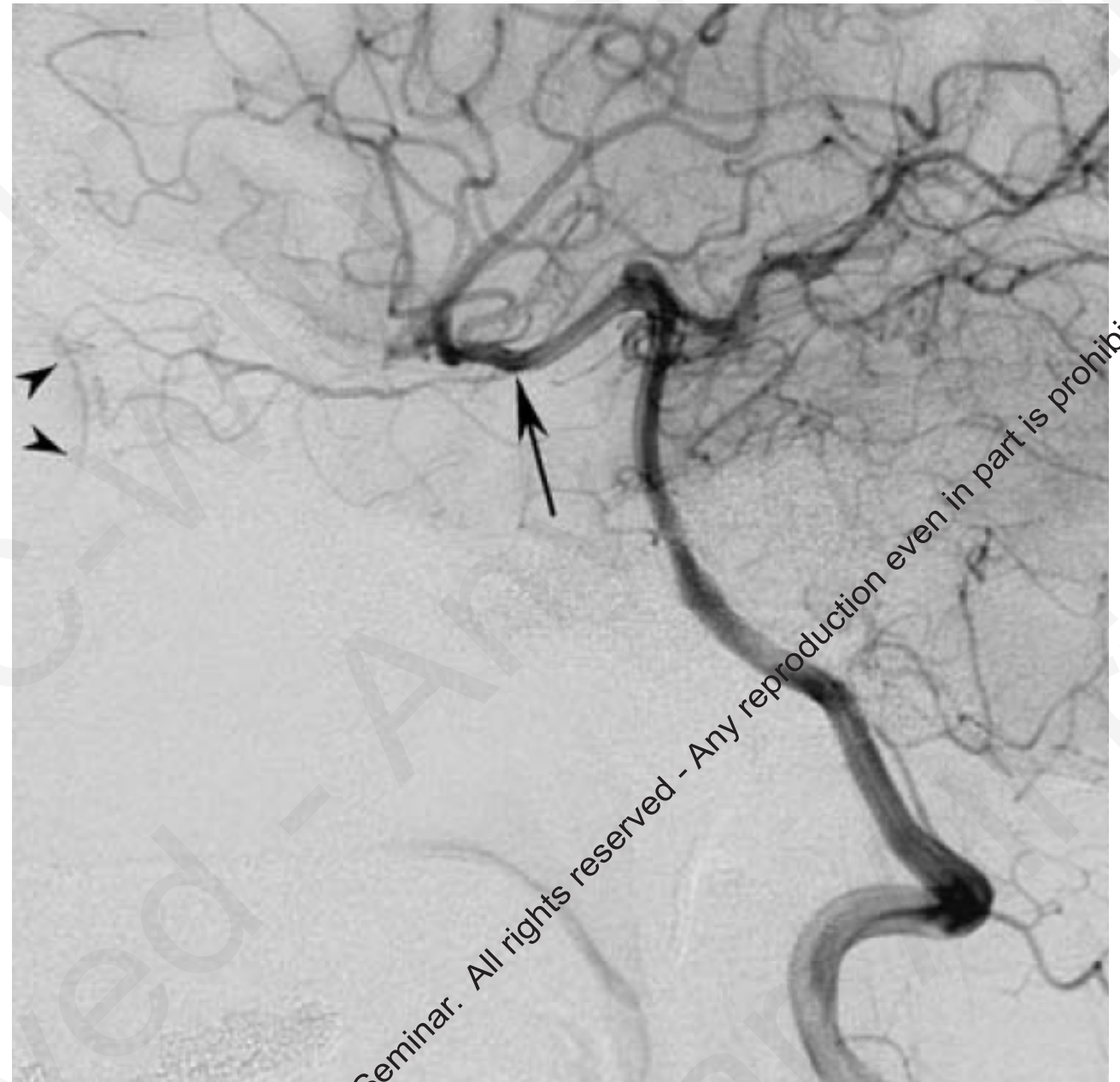
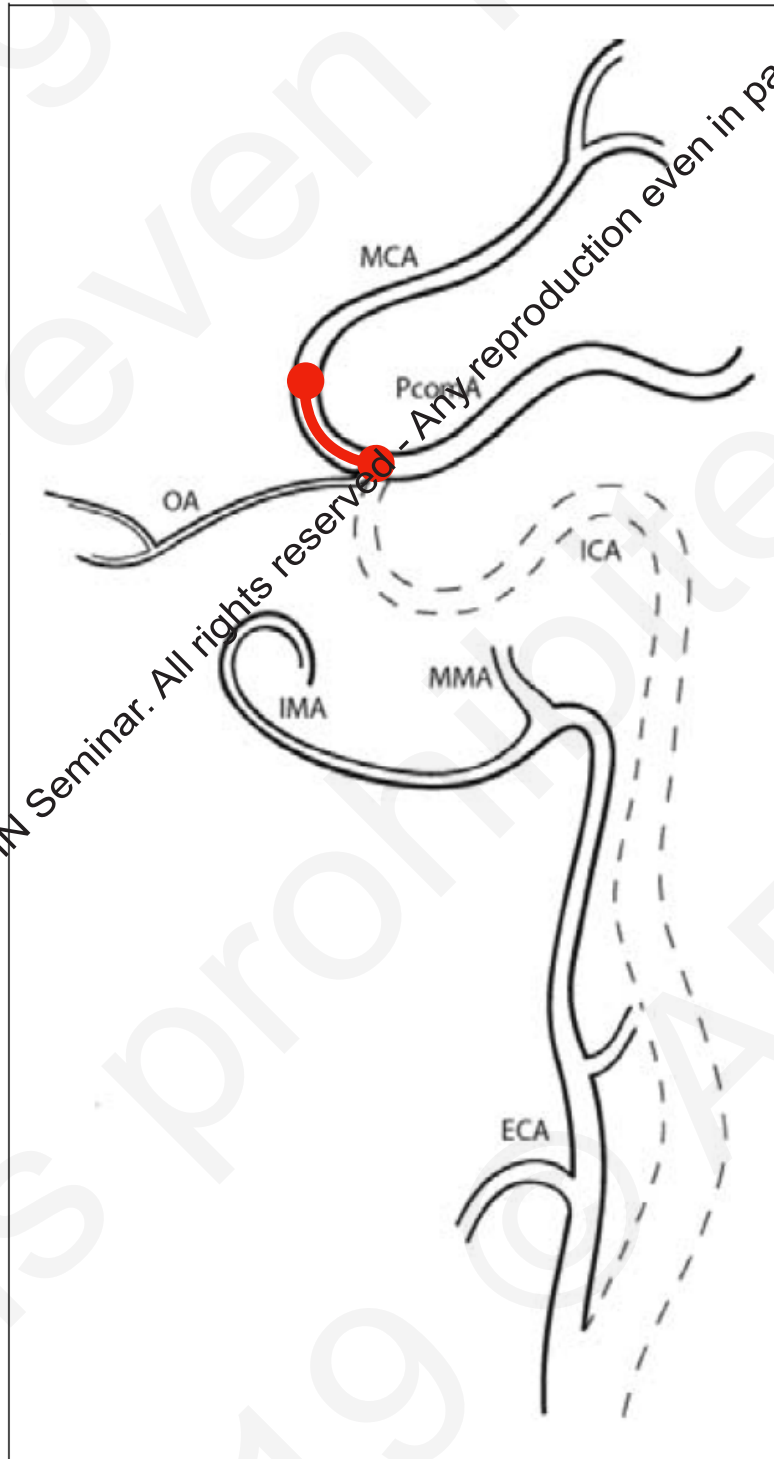

Right VAG

Naeini RM: AJR 2005



# Ophthalmic artery of the ~~p-com~~ origin

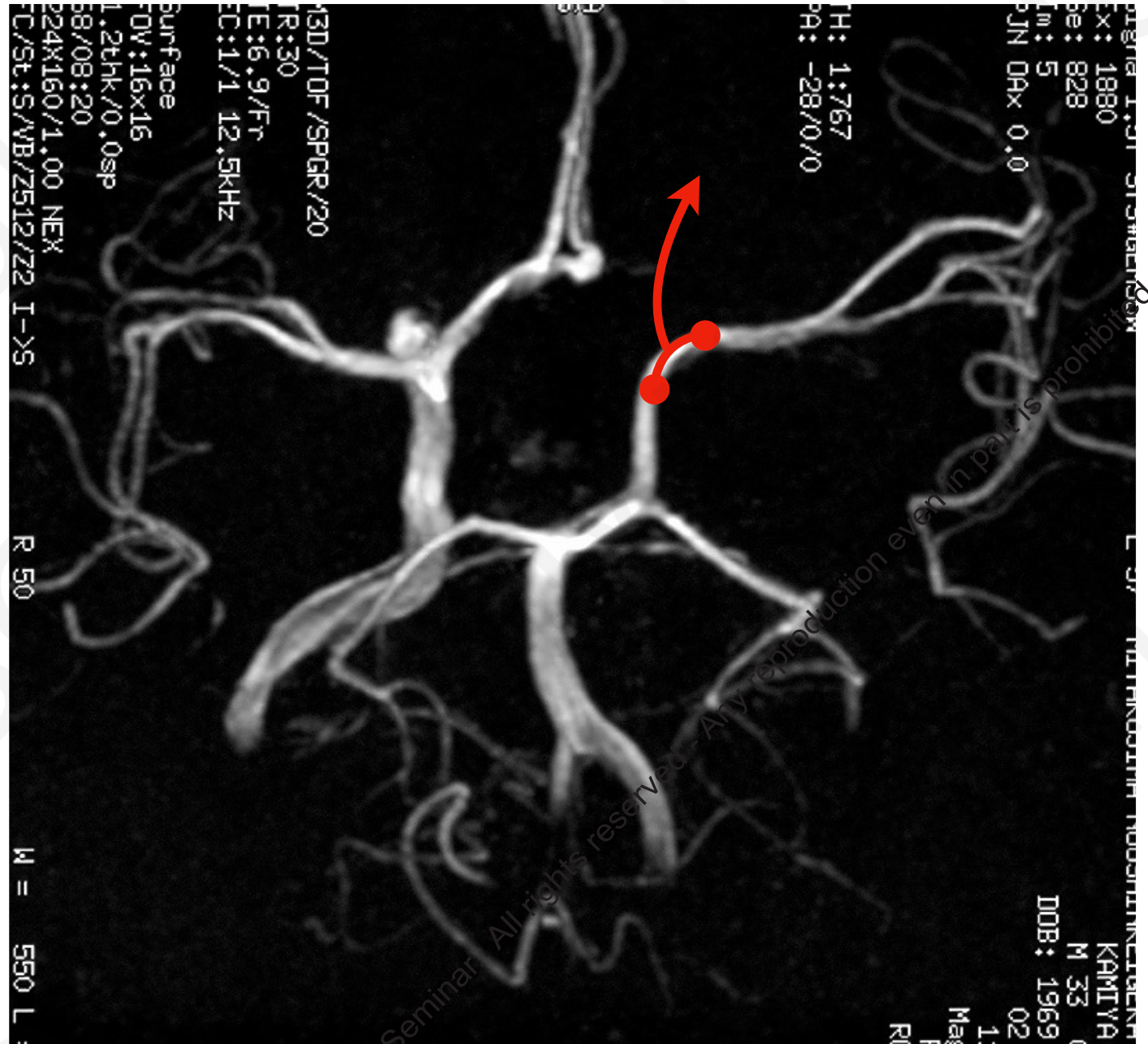


ICA segment (p-com a to IC top)

Naeini RM: AJR 2005



# Ophthalmic artery of the ~~MCA~~ origin



ICA segment (p-com a to IC top)

Left ICA agenesis

Lower LG: Ant Rec 1916

2019 © ABC - WIN Seminar. All rights reserved. Any reproduction even in part is prohibited.

2019 © ABC - WIN Seminar. All rights reserved. Any reproduction even in part is prohibited.

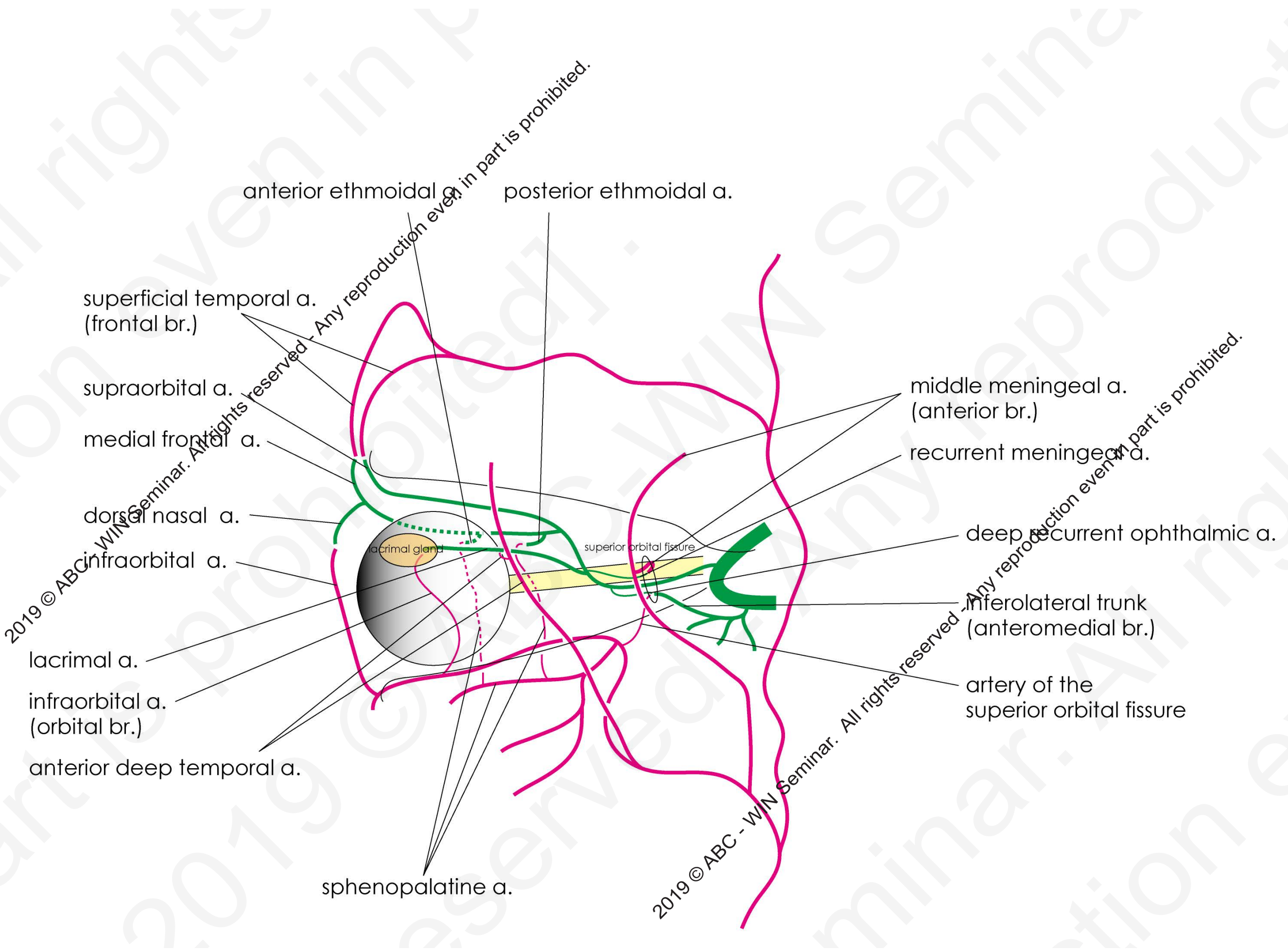
# ECA-Ophthalmic a (IC branches) anastomoses

dangerous anastomoses

useful anastomoses

courtesy of Ishiguro T (colleague)

Osaka City General Hospital



anterior ethmoidal a.

posterior ethmoidal a.

superficial temporal a.  
(frontal br.)

supraorbital a.

medial frontal a.

dorsal nasal a.

infraorbital a.

lacrimal a.

infraorbital a.  
(orbital br.)

anterior deep temporal a.

sphenopalatine a.

middle meningeal a.  
(anterior br.)

recurrent meningeal a.

deep recurrent ophthalmic a.

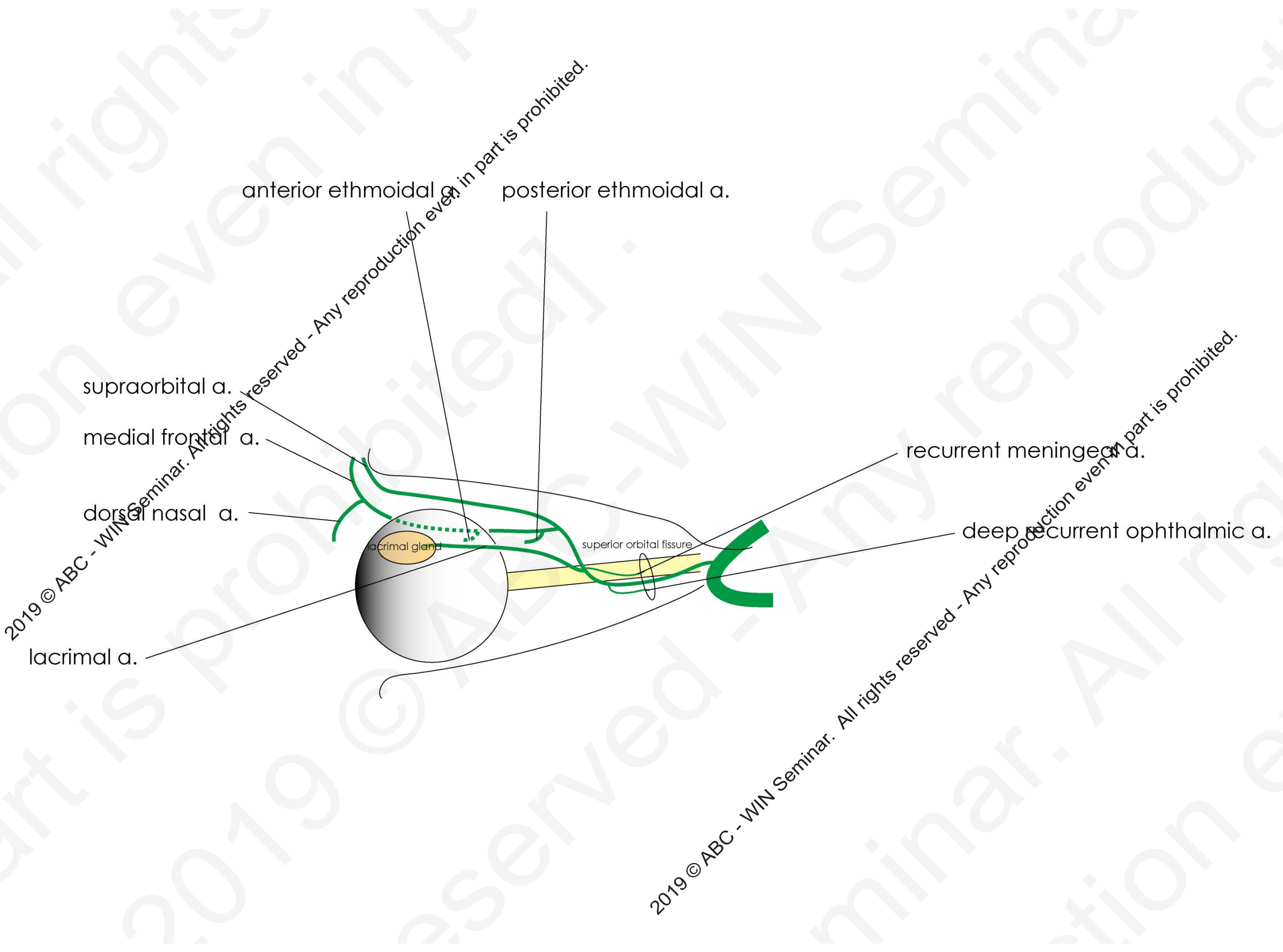
inferolateral trunk  
(anteromedial br.)

artery of the  
superior orbital fissure

2019 © ABC - WIN Seminar. All rights reserved. Any reproduction even in part is prohibited.

2019 © ABC - WIN Seminar. All rights reserved. Any reproduction even in part is prohibited.





anterior ethmoidal a.

posterior ethmoidal a.

supraorbital a.

medial frontal a.

dorsal nasal a.

lacrimal a.

lacrimal gland

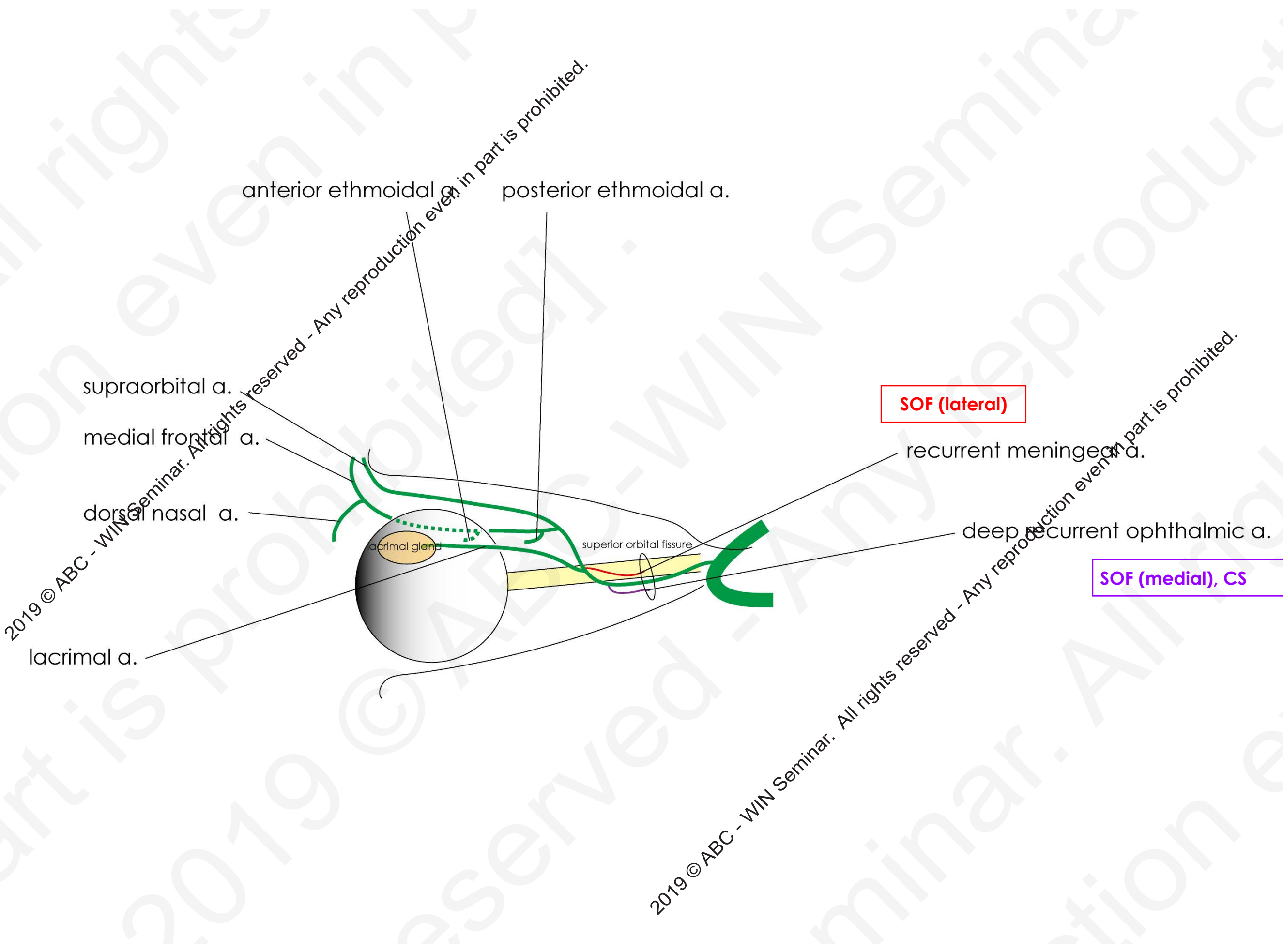
superior orbital fissure

recurrent meningeal a.

deep recurrent ophthalmic a.

2019 © ABC - WIN Seminar. All rights reserved - Any reproduction even in part is prohibited.

2019 © ABC - WIN Seminar. All rights reserved - Any reproduction even in part is prohibited.



anterior ethmoidal a.

posterior ethmoidal a.

supraorbital a.

medial frontal a.

dorsal nasal a.

lacrimal a.

lacrimal gland

superior orbital fissure

SOF (lateral)

recurrent meningeal a.

deep recurrent ophthalmic a.

SOF (medial), CS

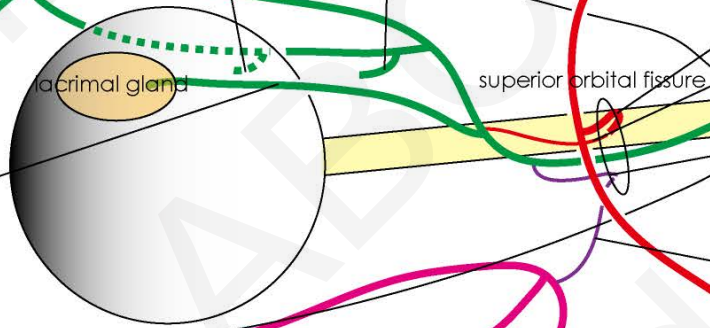
2019 © ABC - WIN Seminar. All rights reserved - Any reproduction even in part is prohibited.

2019 © ABC - WIN Seminar. All rights reserved - Any reproduction even in part is prohibited.

2019 © ABC - WIN Seminar. All rights reserved - Any reproduction even in part is prohibited.

anterior ethmoidal a.      posterior ethmoidal a.

supraorbital a.  
medial frontal a.  
dorsal nasal a.



lacrimal a.  
infraorbital a.

sphenopalatine a.

**SOF (lateral)**

middle meningeal a.  
(anterior br.)  
recurrent meningeal a.

deep recurrent ophthalmic a.  
artery of the  
superior orbital fissure

**SOF (medial), CS**

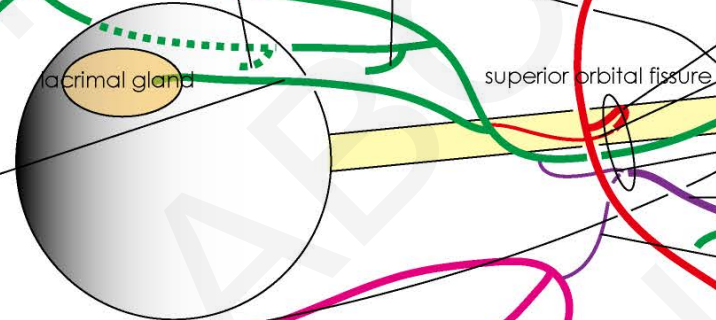
2019 © ABC - WIN Seminar. All rights reserved - Any reproduction even in part is prohibited.



2019 © ABC - WIN Seminar. All rights reserved - Any reproduction even in part is prohibited.

anterior ethmoidal a.      posterior ethmoidal a.

supraorbital a.  
medial frontal a.  
dorsal nasal a.



lacrimal a.  
infraorbital a.

sphenopalatine a.

**SOF (lateral)**

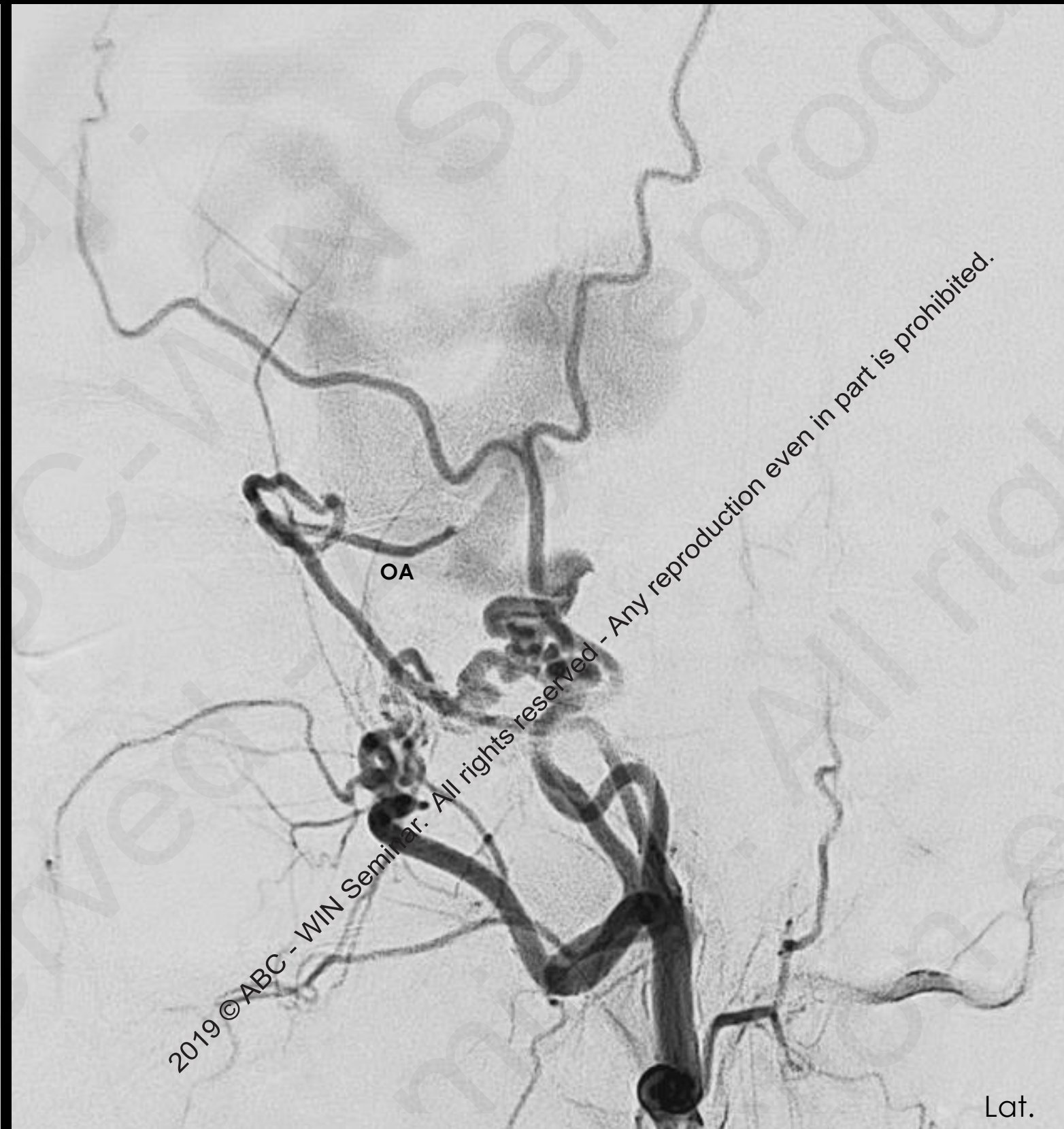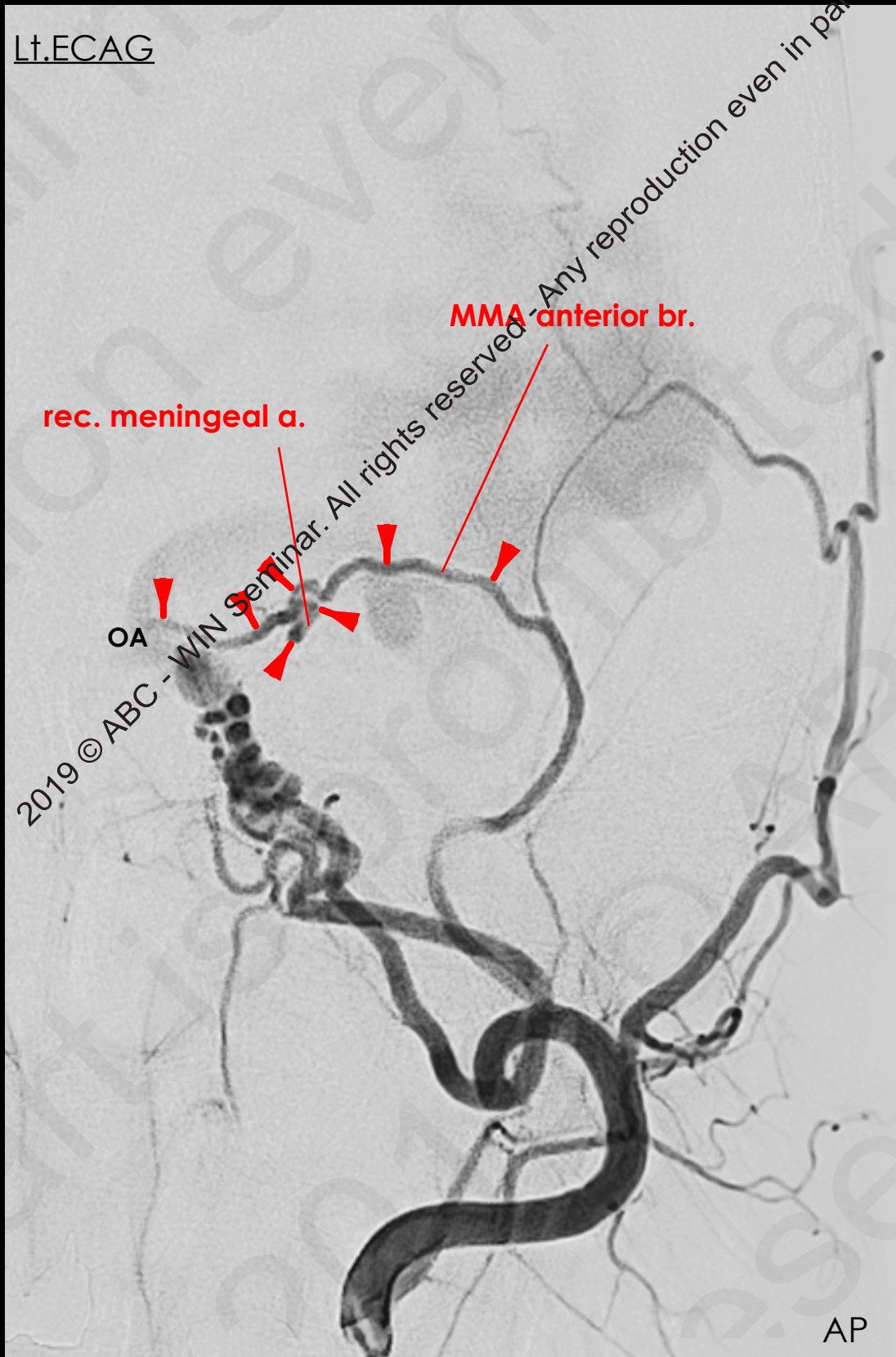
middle meningeal a. (anterior br.)  
recurrent meningeal a.

deep recurrent ophthalmic a.  
inferolateral trunk (anteromedial br.)  
artery of the superior orbital fissure

**SOF (medial), CS**

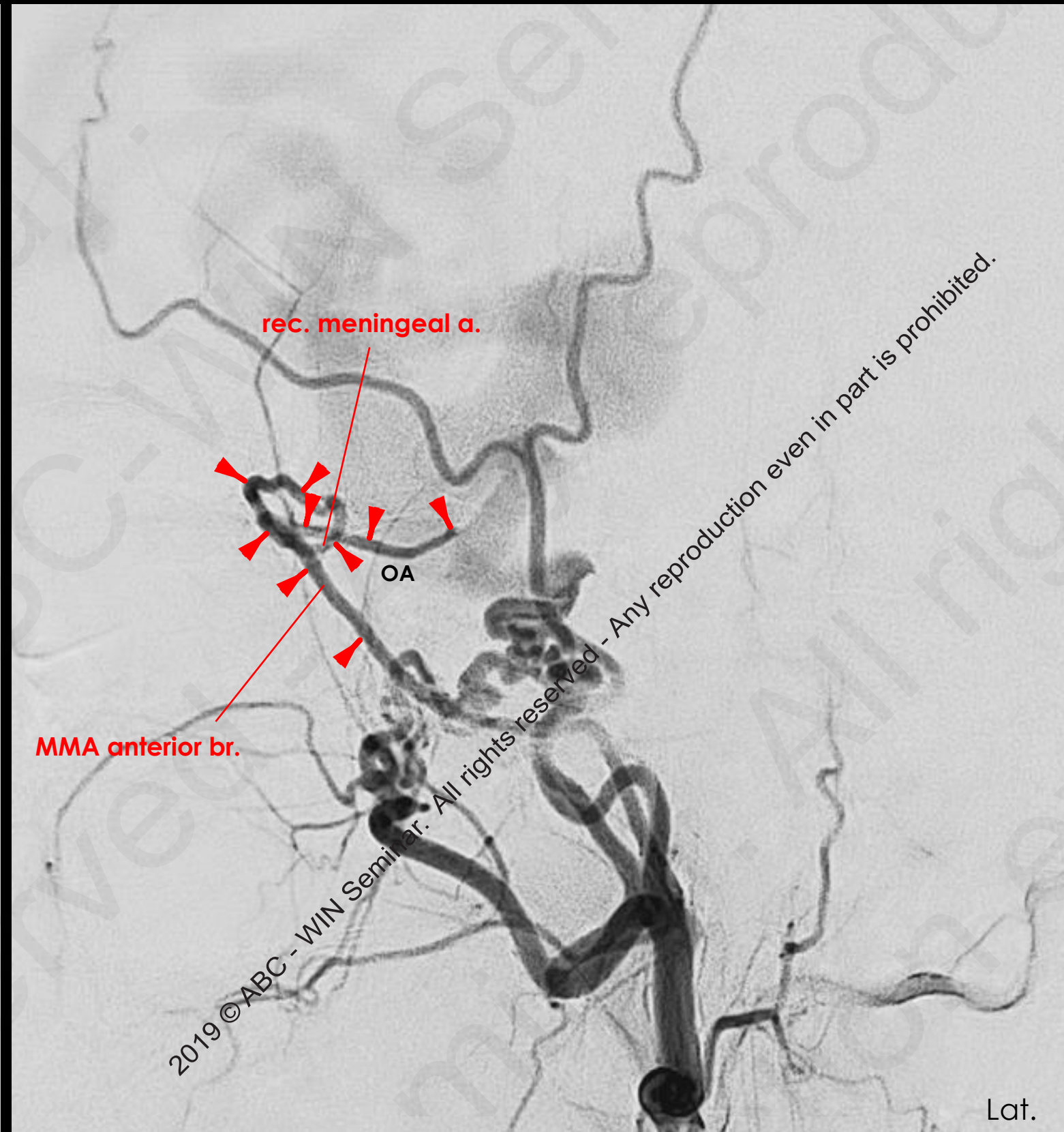
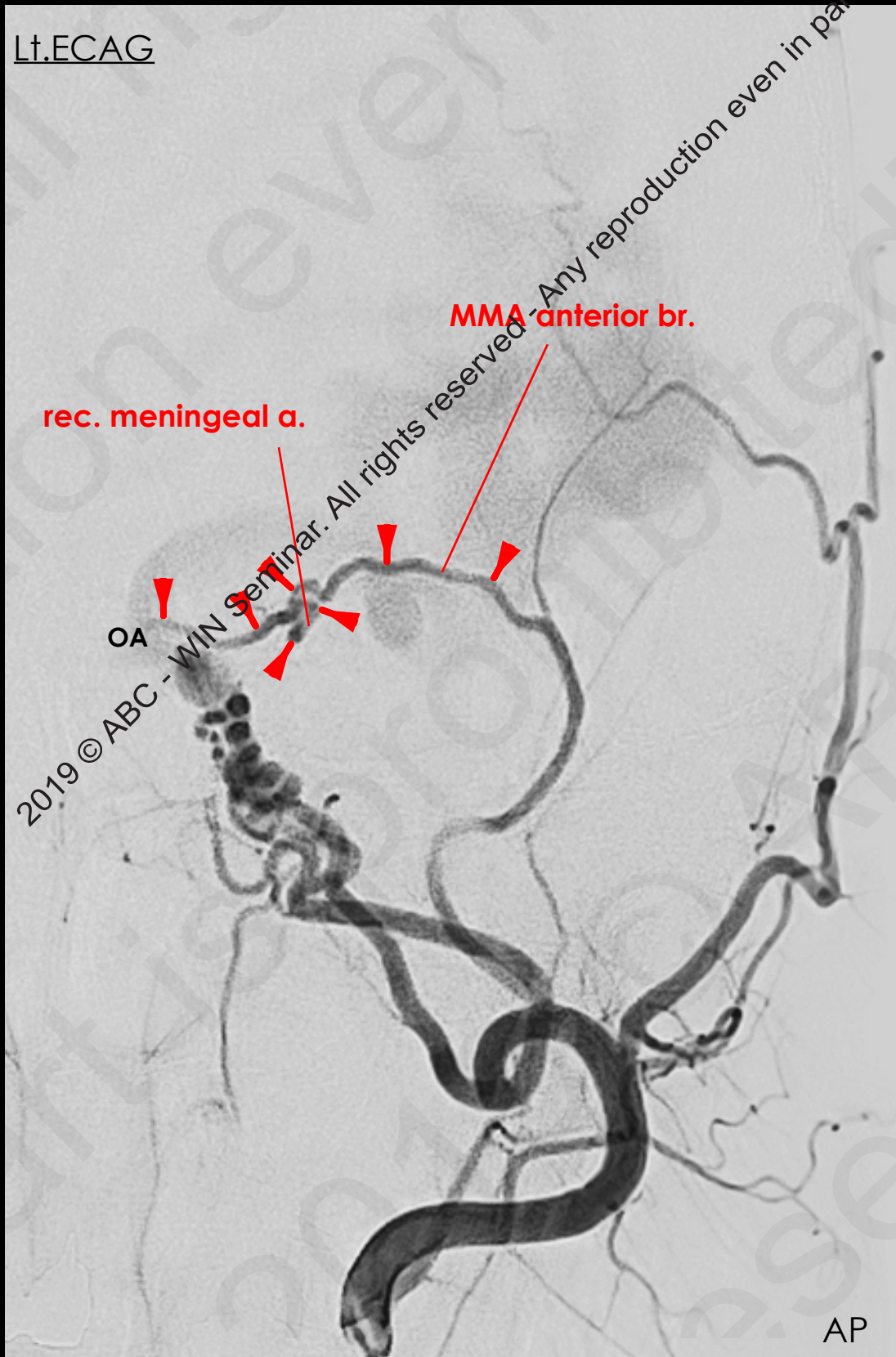
2019 © ABC - WIN Seminar. All rights reserved - Any reproduction even in part is prohibited.

# superficial recurrent meningeal a. – MMA anterior br.



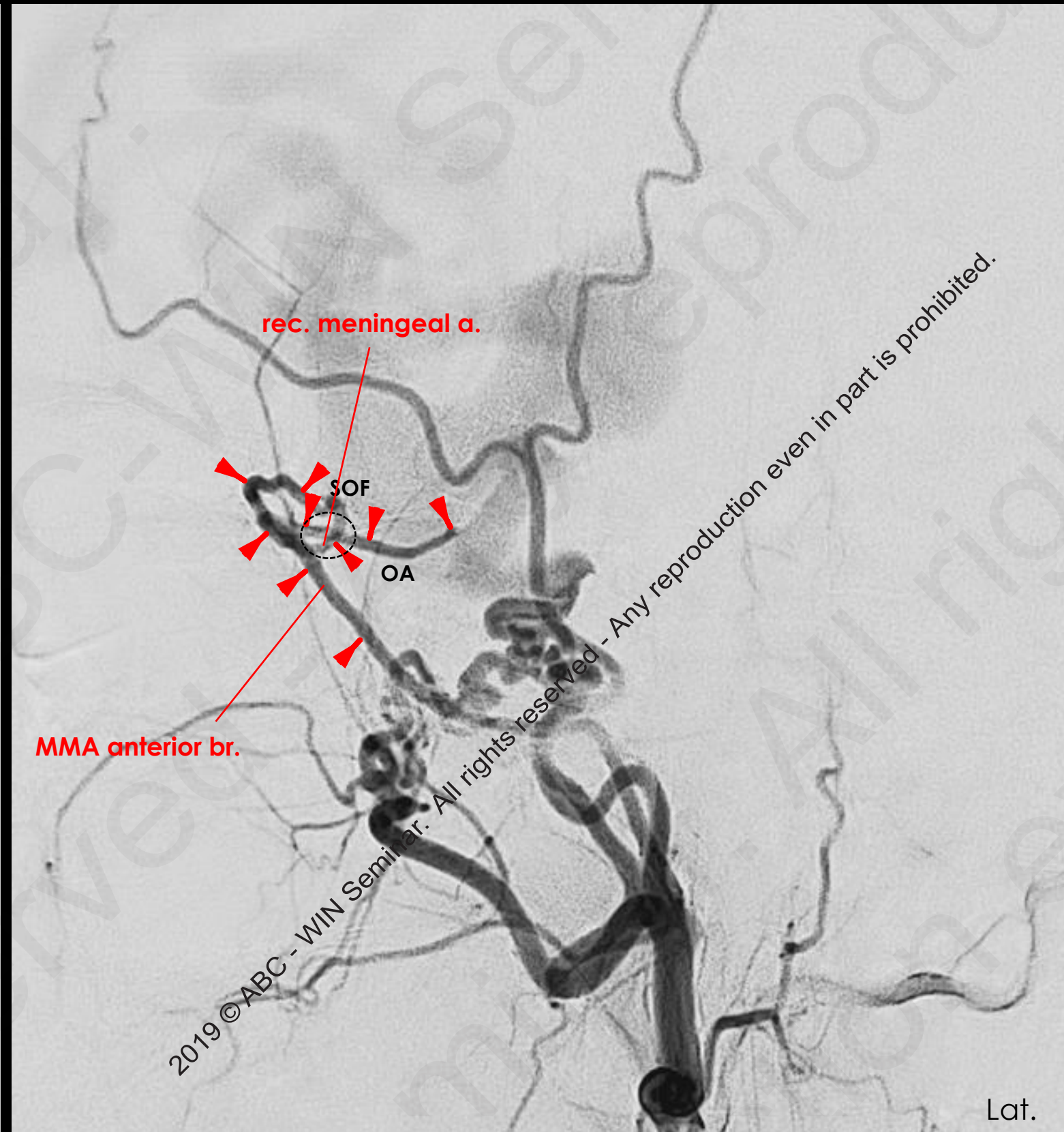
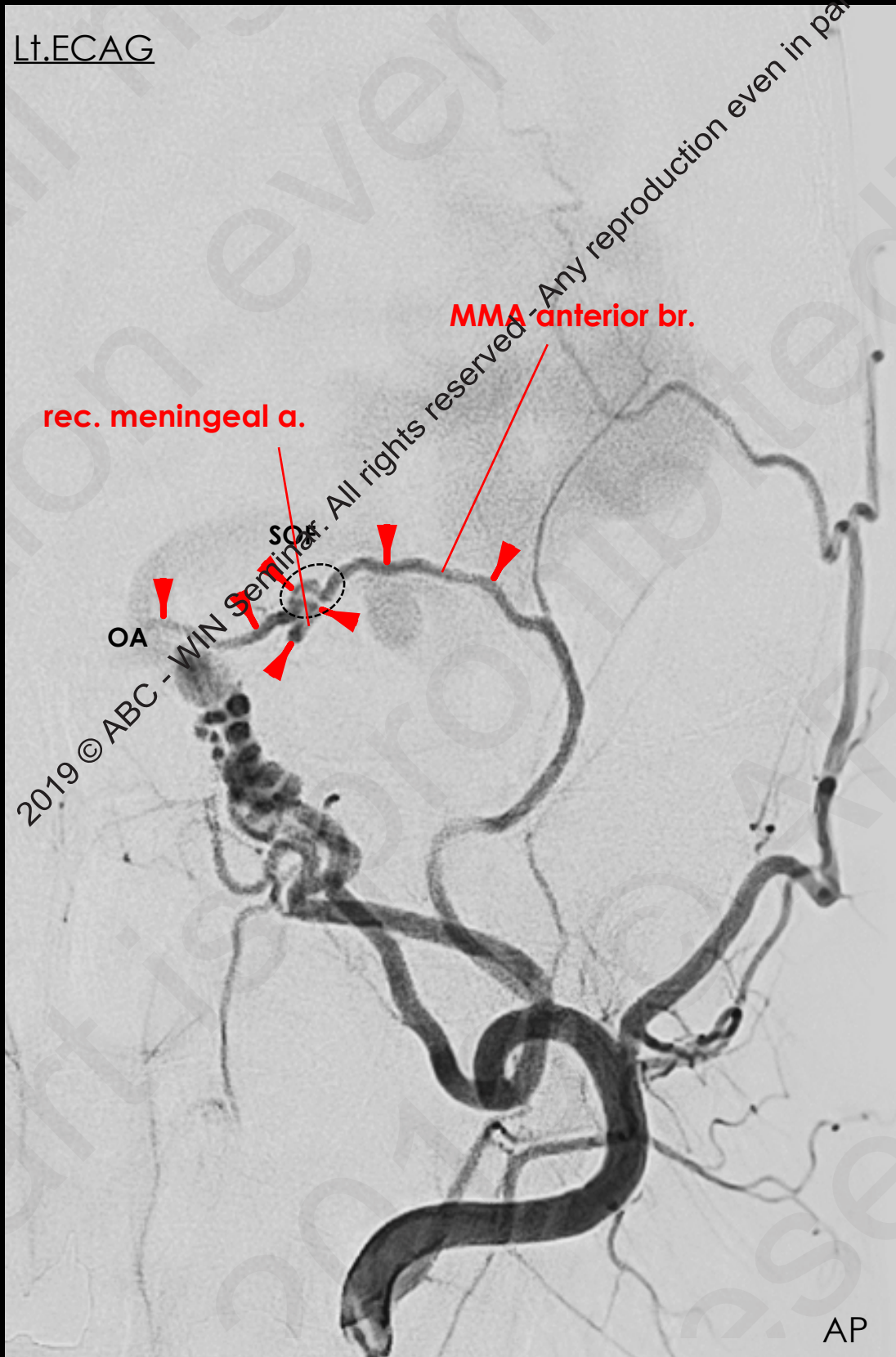


# superficial recurrent meningeal a. – MMA anterior br.



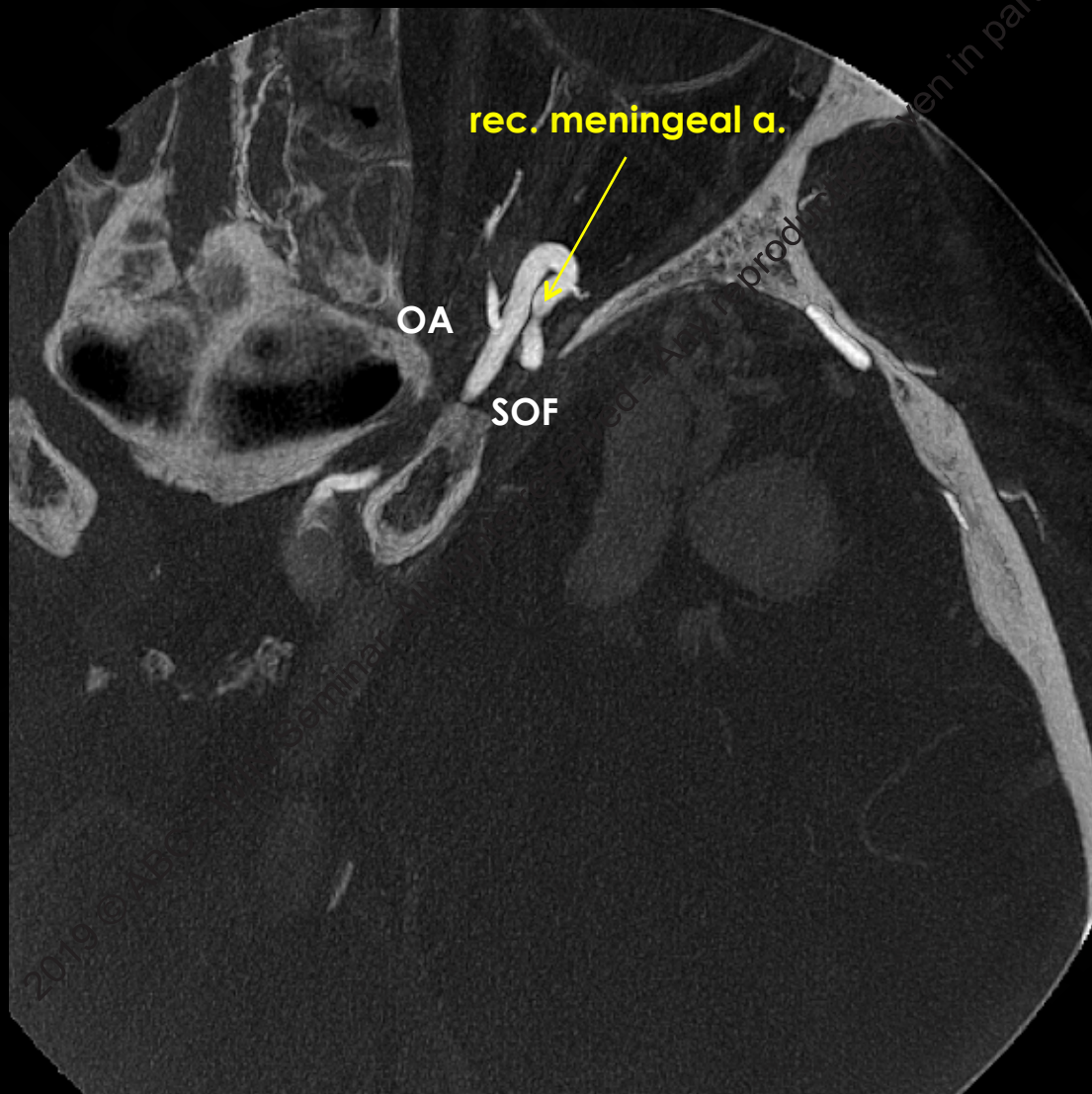


# superficial recurrent meningeal a. – MMA anterior br.

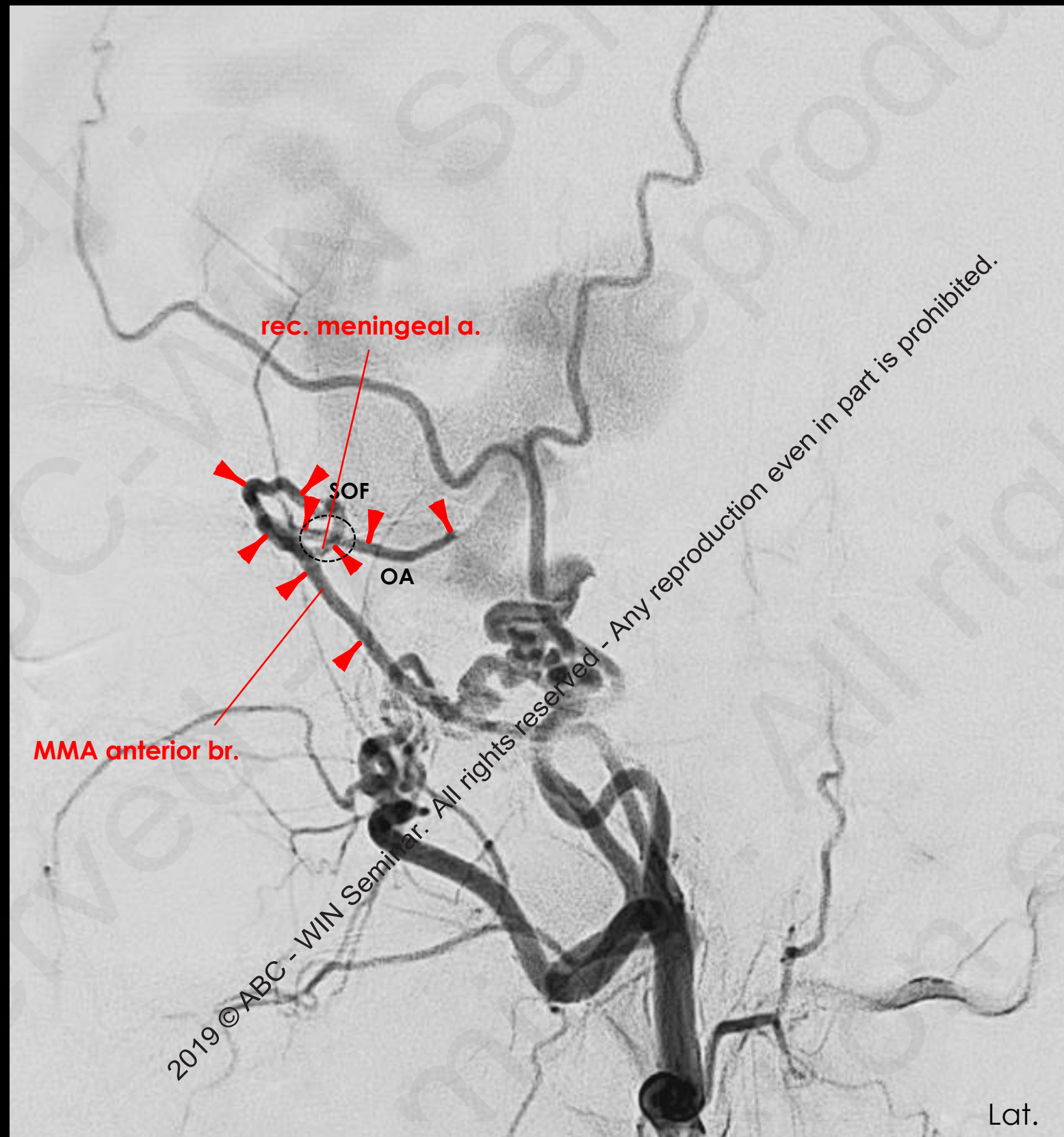




# superficial recurrent meningeal a. – MMA anterior br.

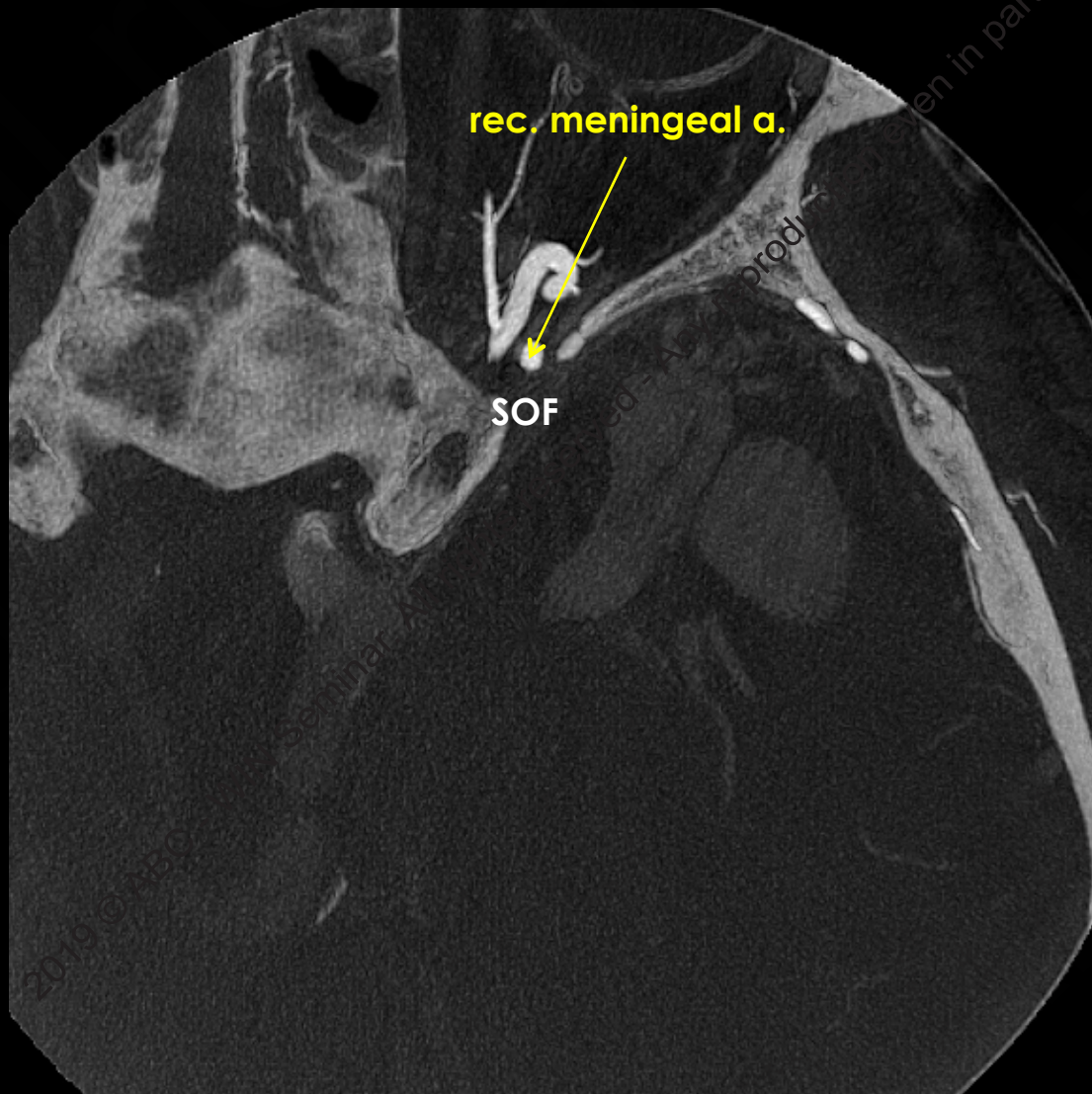


cone beam CT  
axial

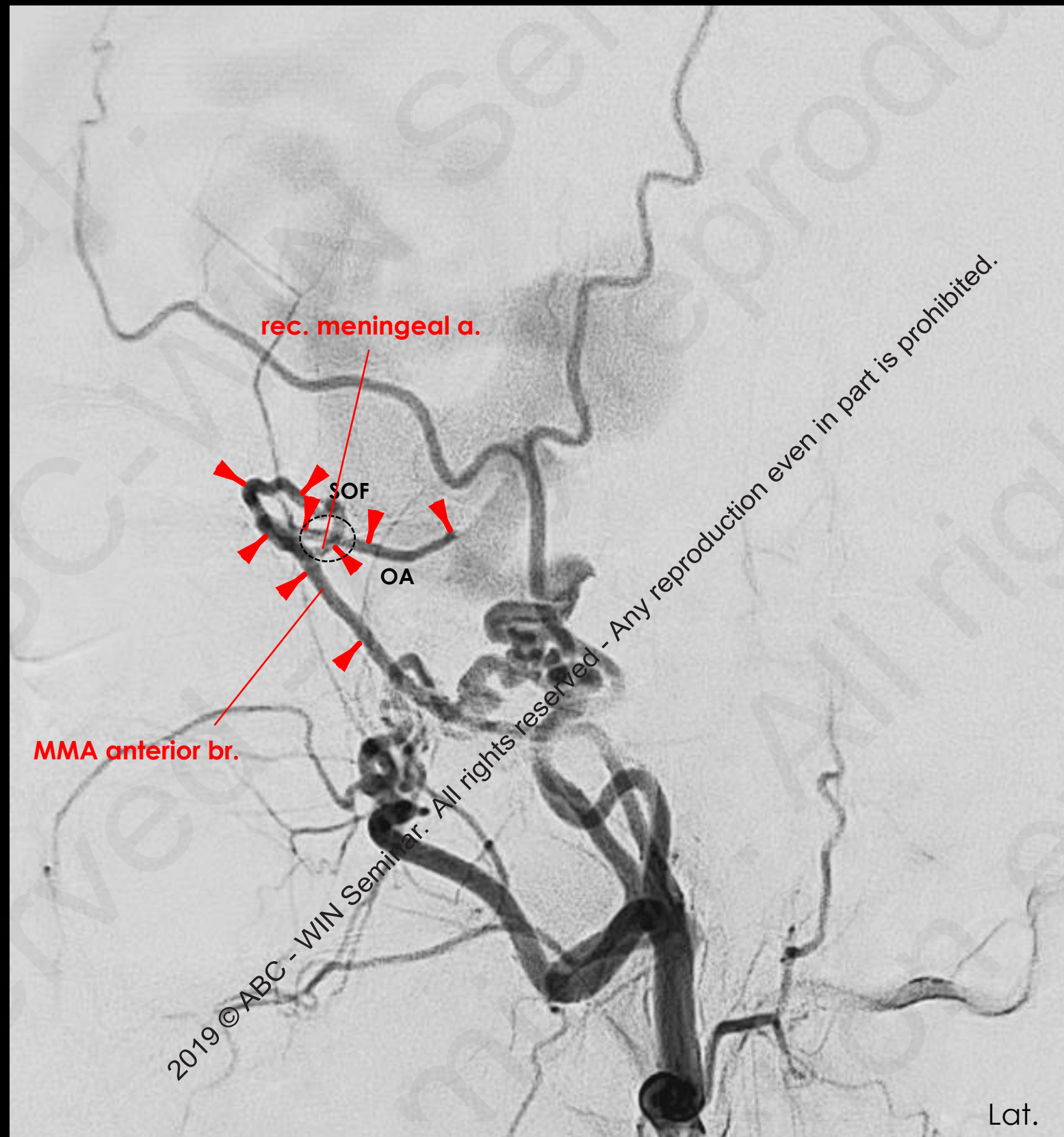




# superficial recurrent meningeal a. – MMA anterior br.

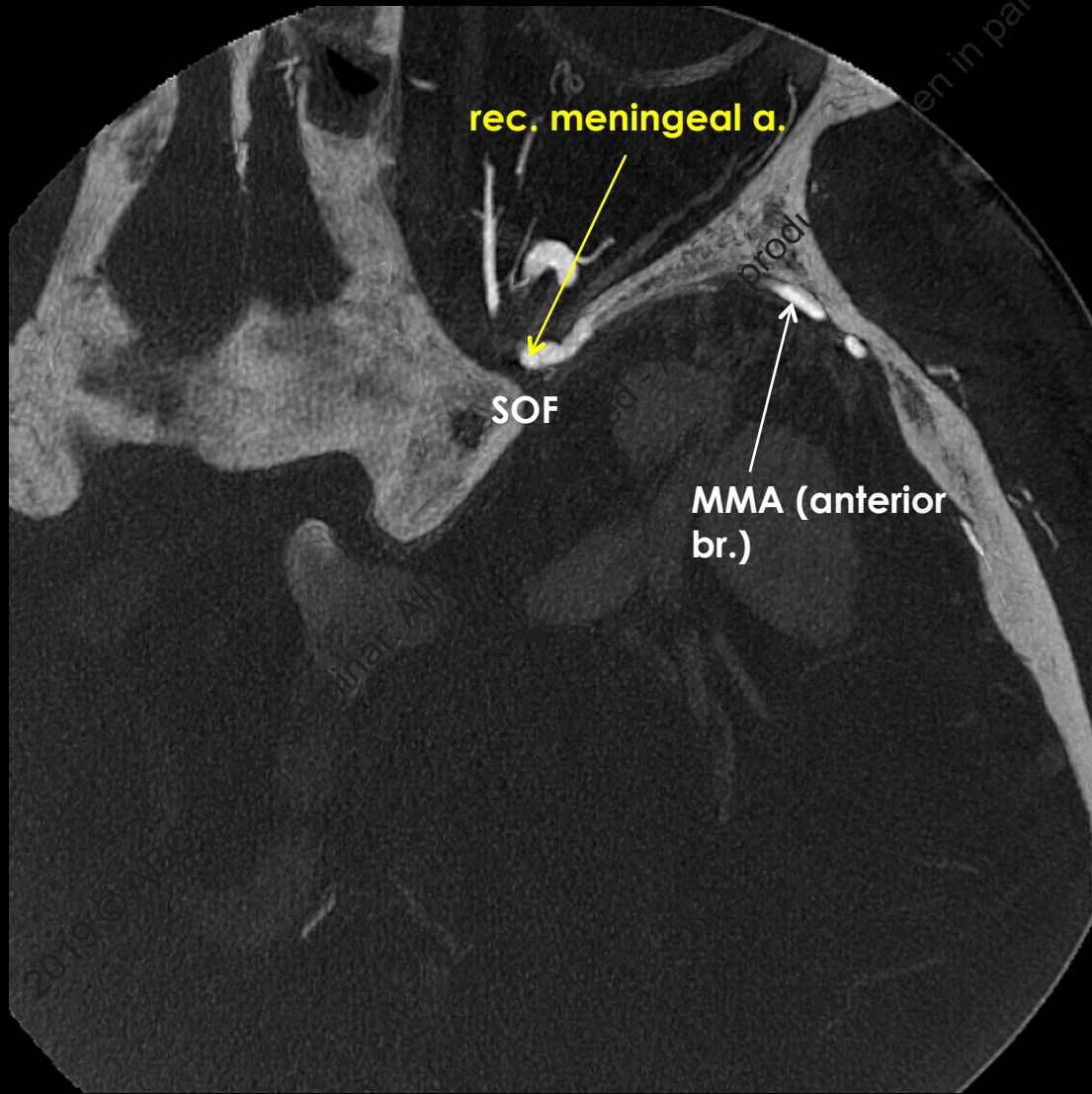


cone beam CT  
axial

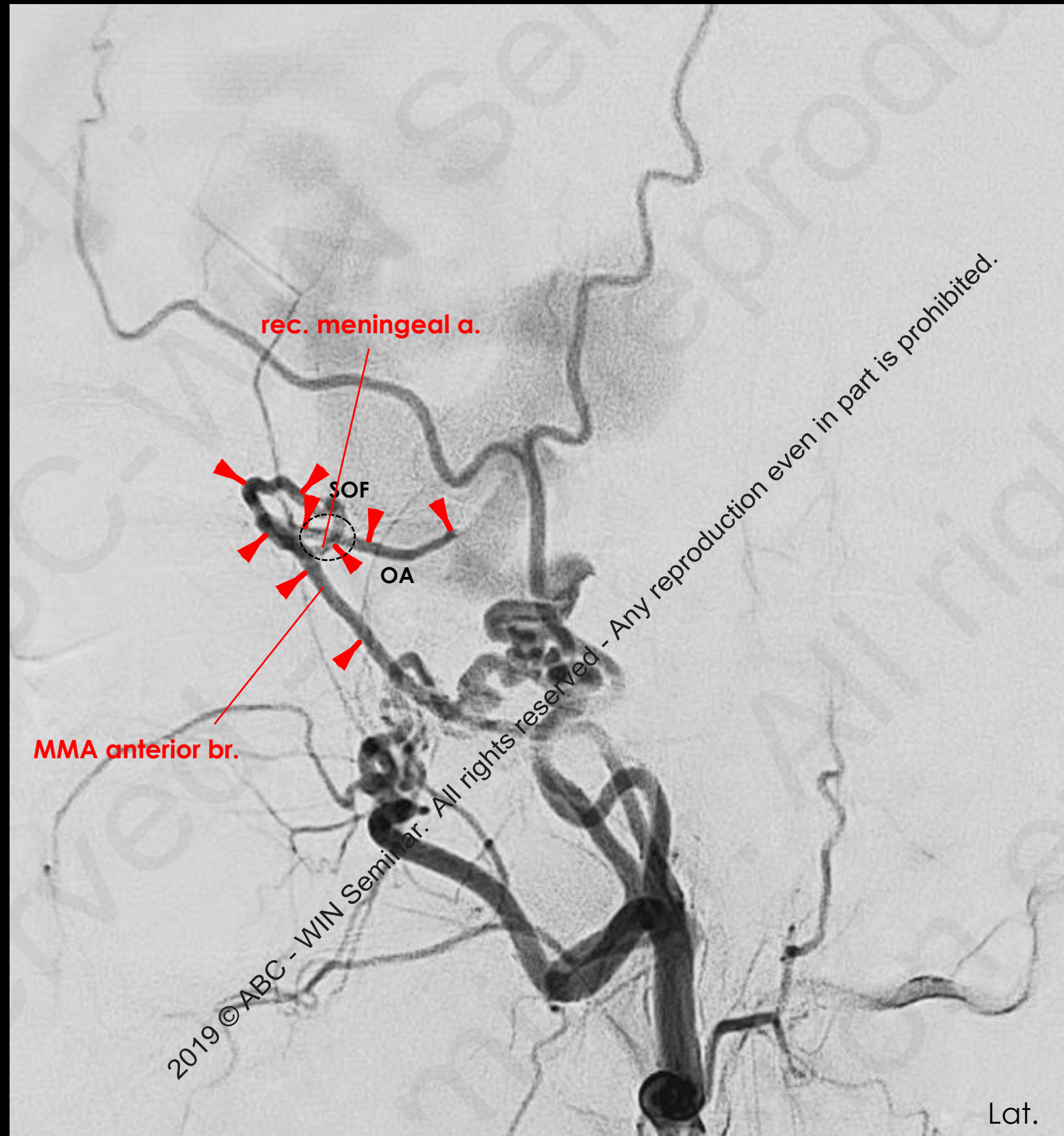




# superficial recurrent meningeal a. – MMA anterior br.

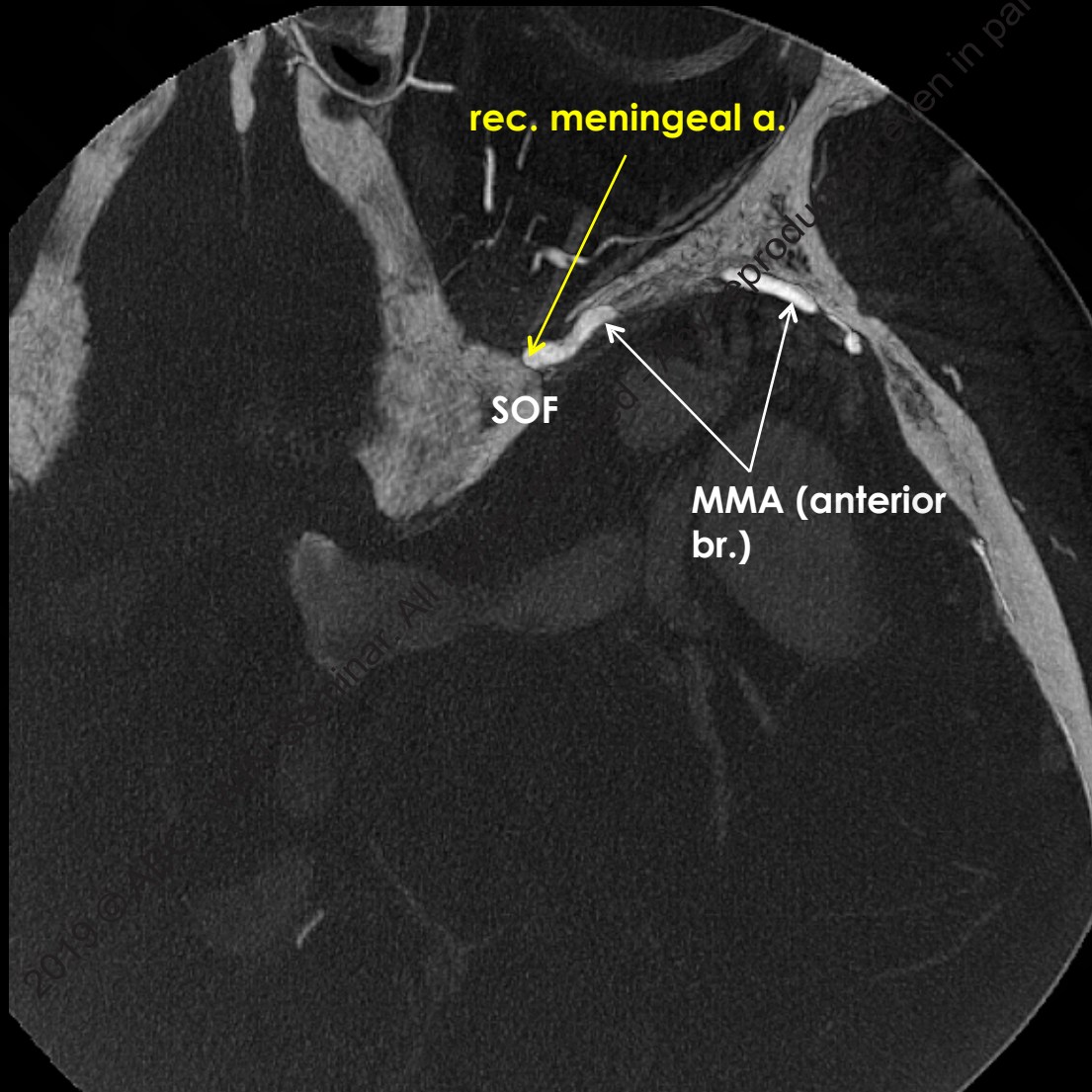


cone beam CT  
axial

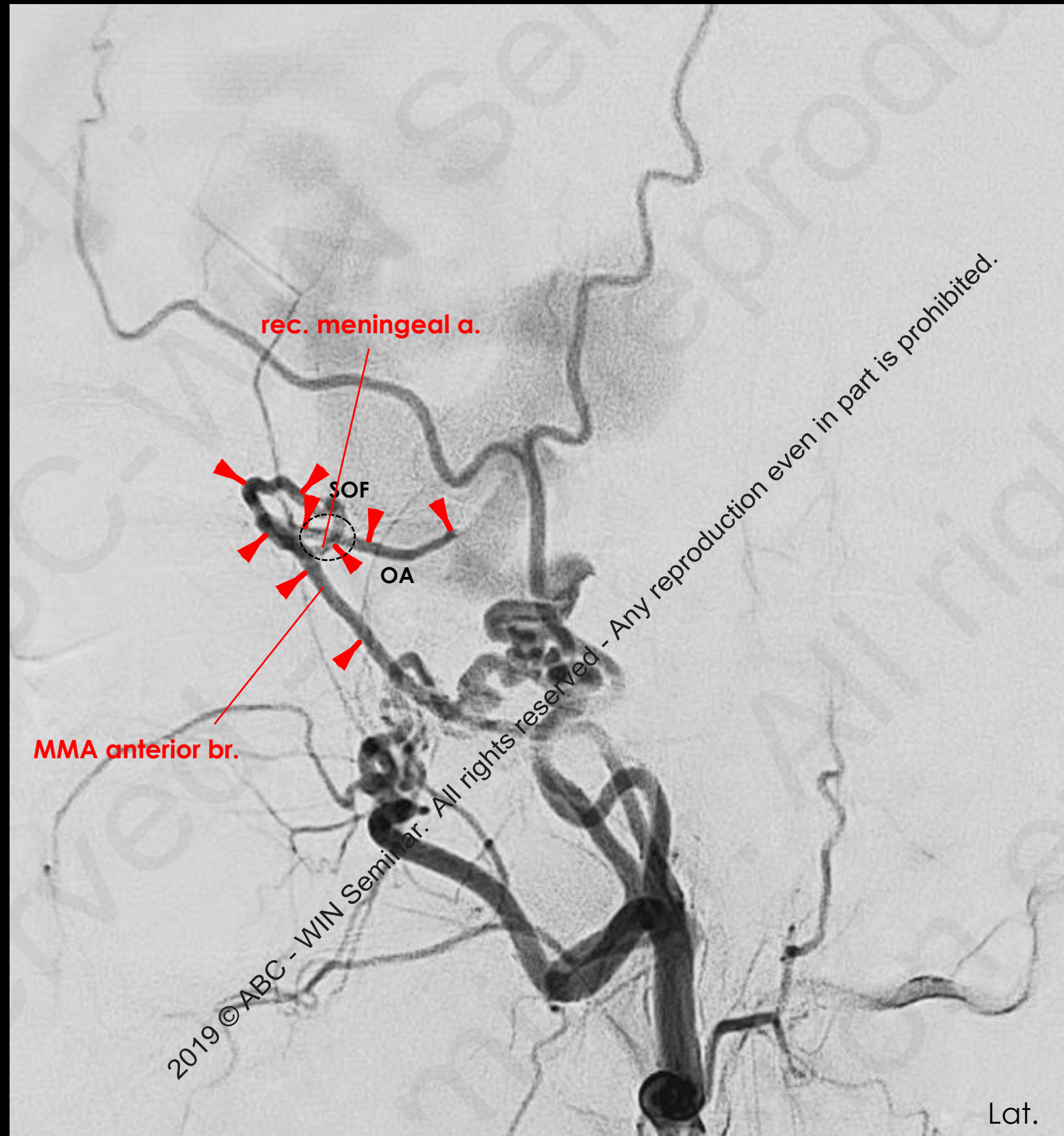




# superficial recurrent meningeal a. – MMA anterior br.

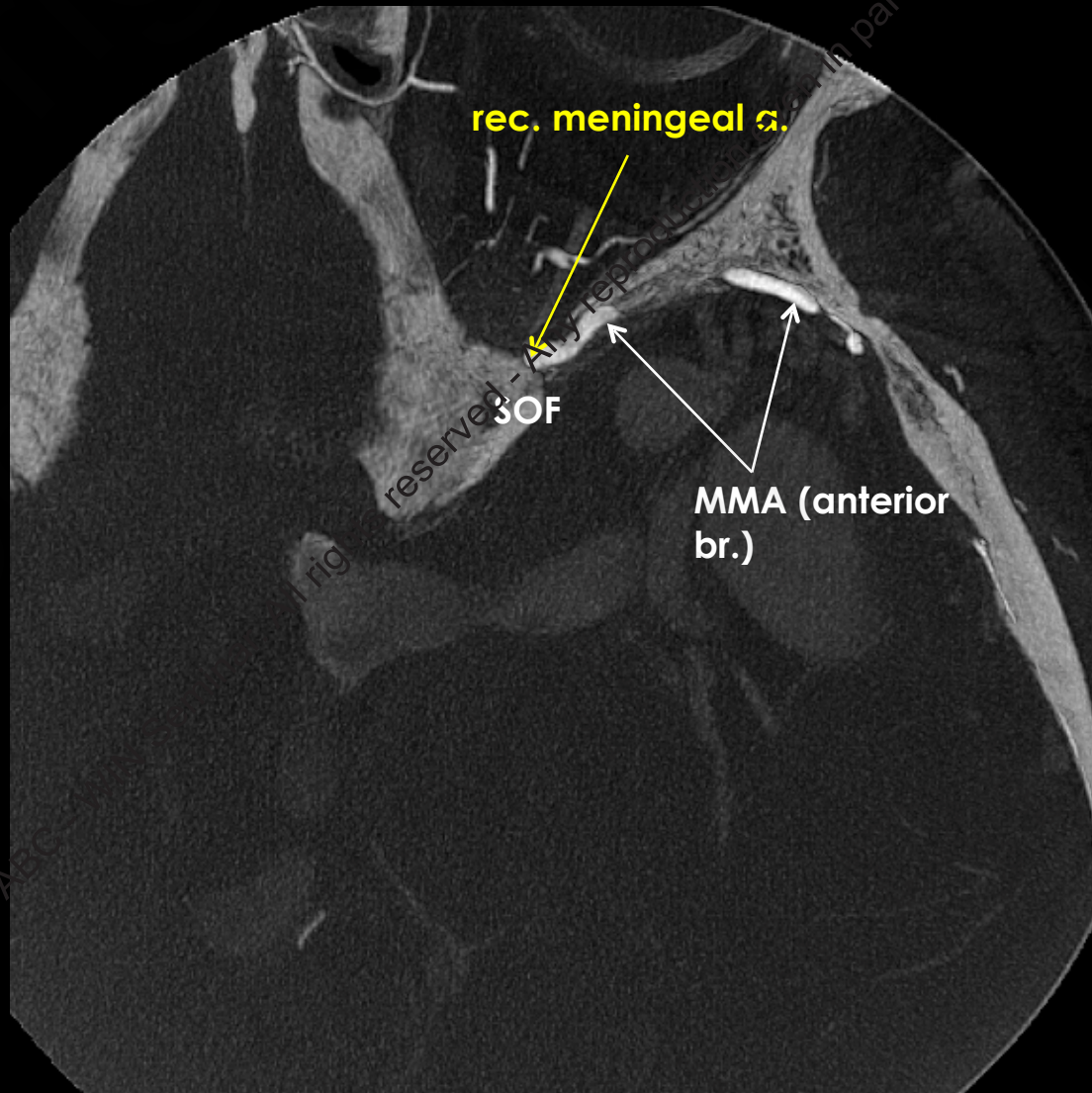


cone beam CT  
axial

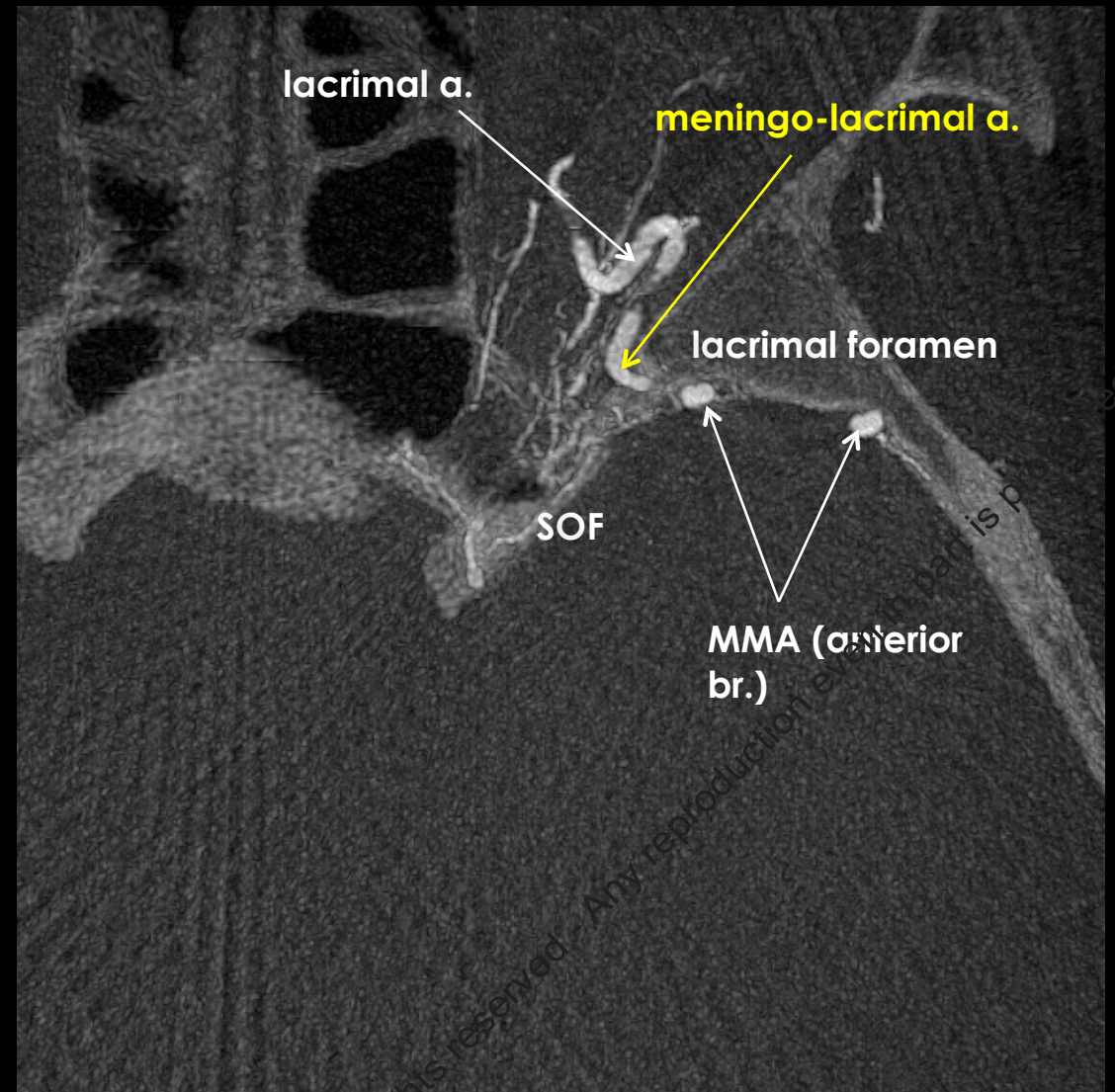




# superficial recurrent meningeal a. – MMA anterior br.



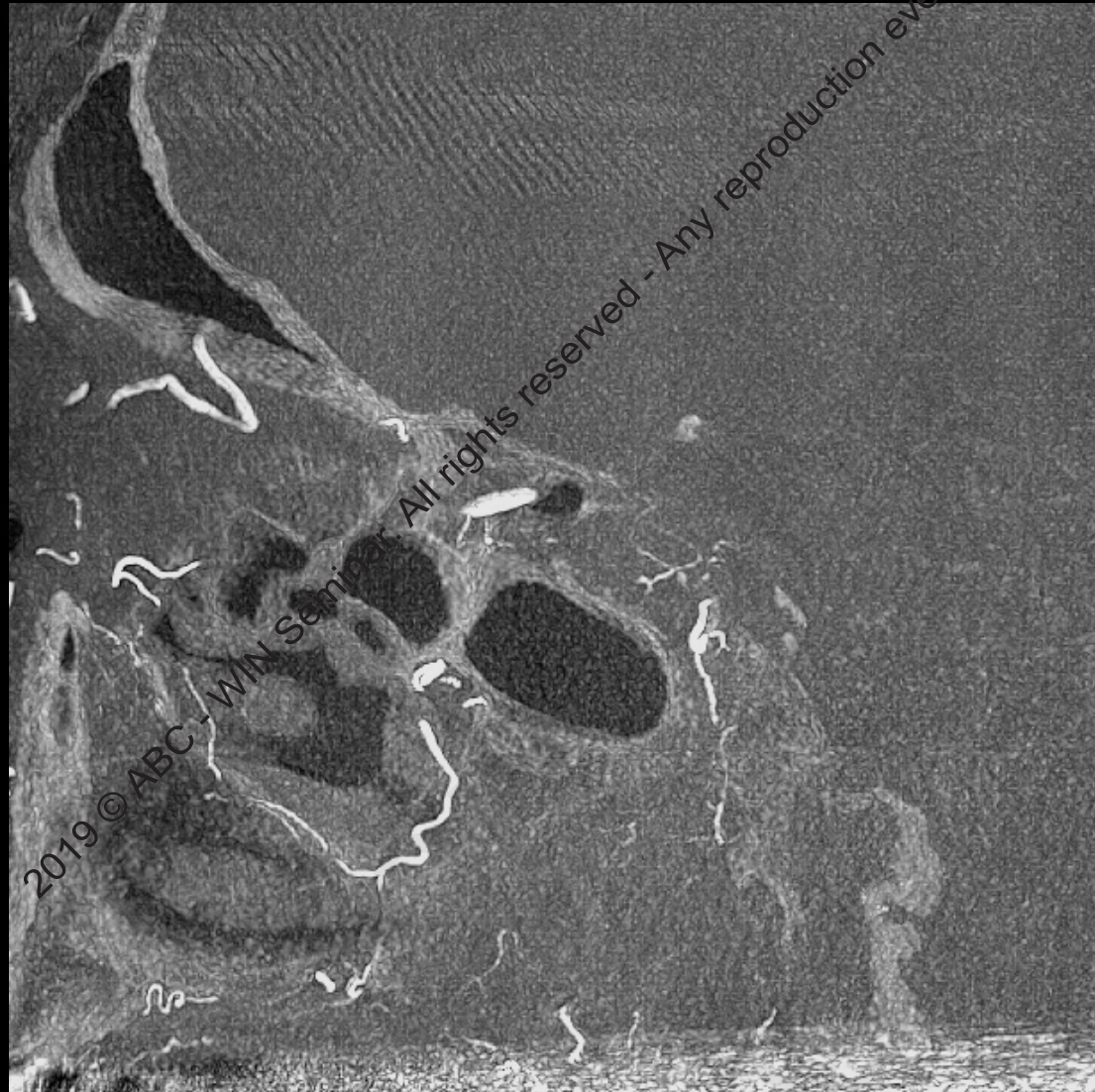cone beam CT  
axial



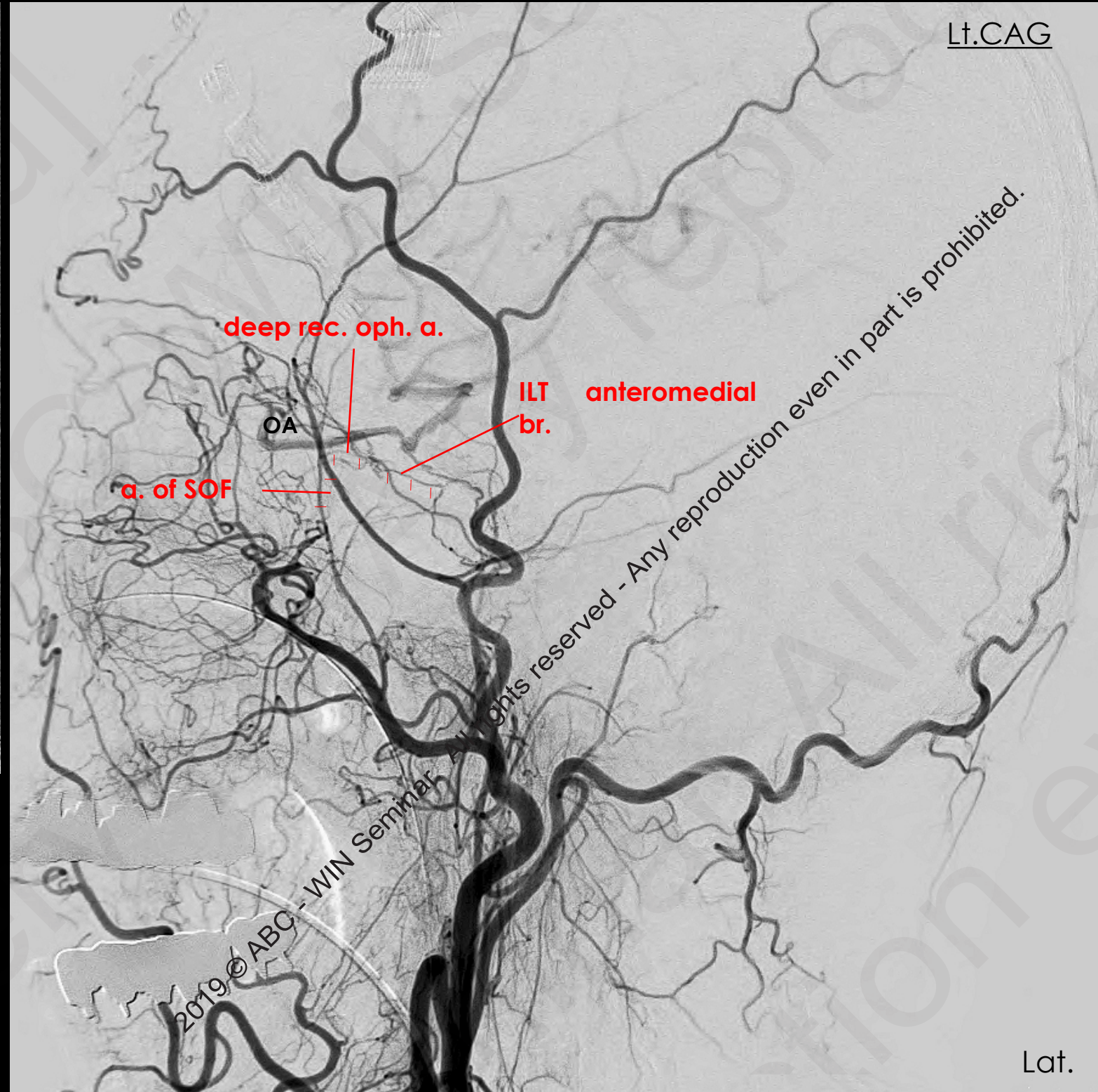
3DRA MPR  
axial image



# deep recurrent ophthalmic a. - artery of SOF - ILT anteromedial br.



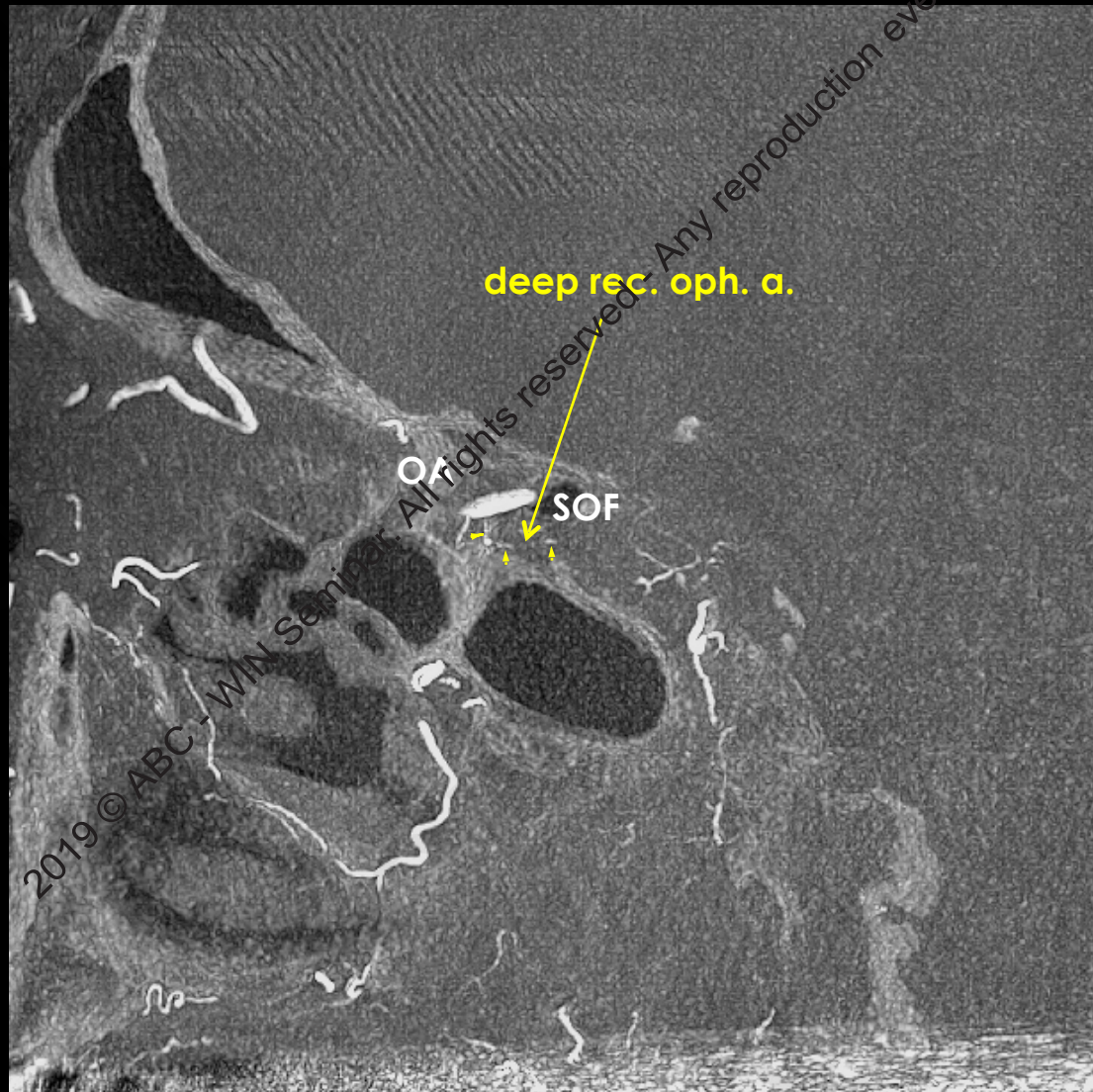
3DRA slab MIP  
sagittal



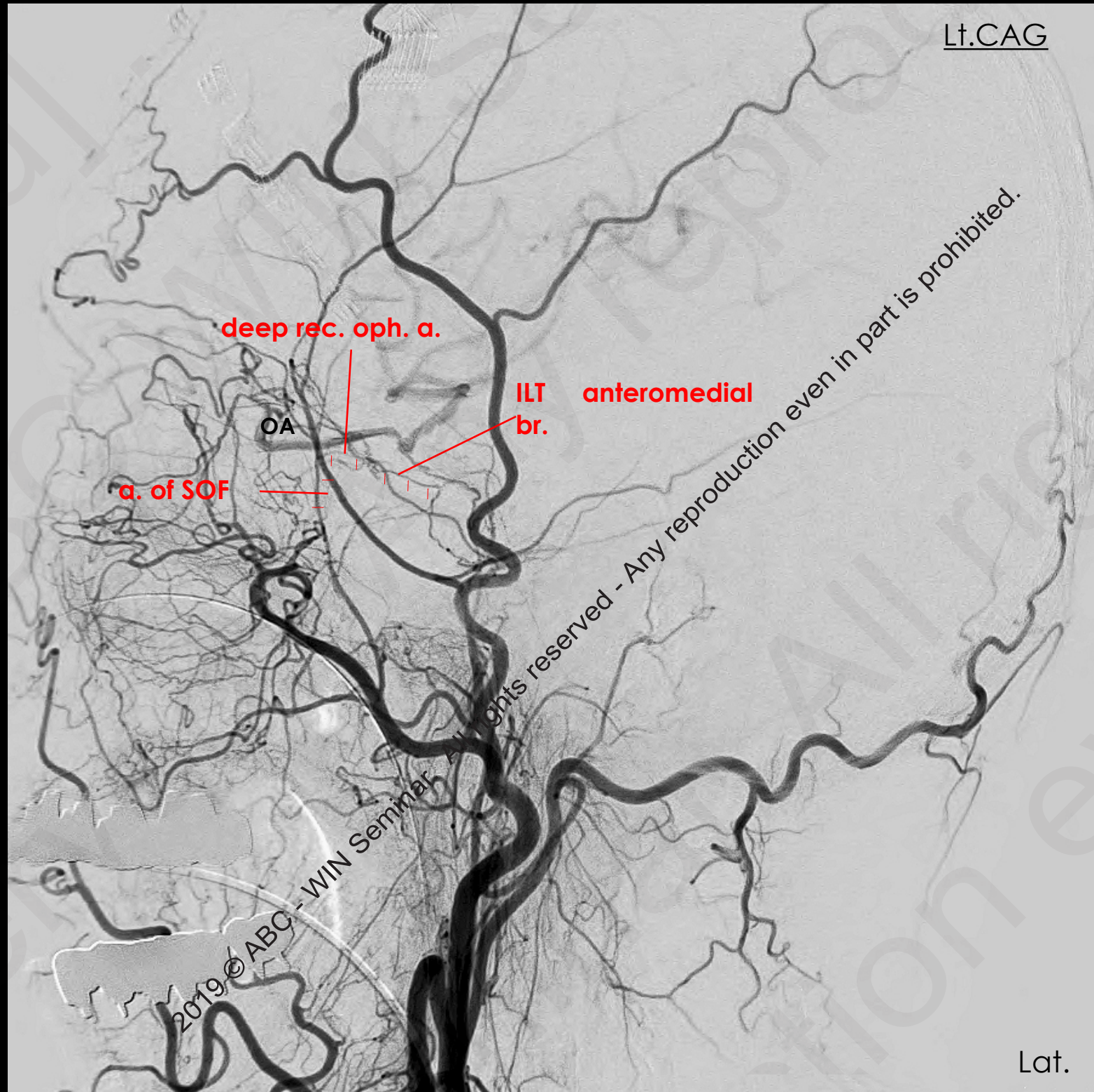


# deep recurrent ophthalmic a. - artery of SOF

## - ILT anteromedial br.



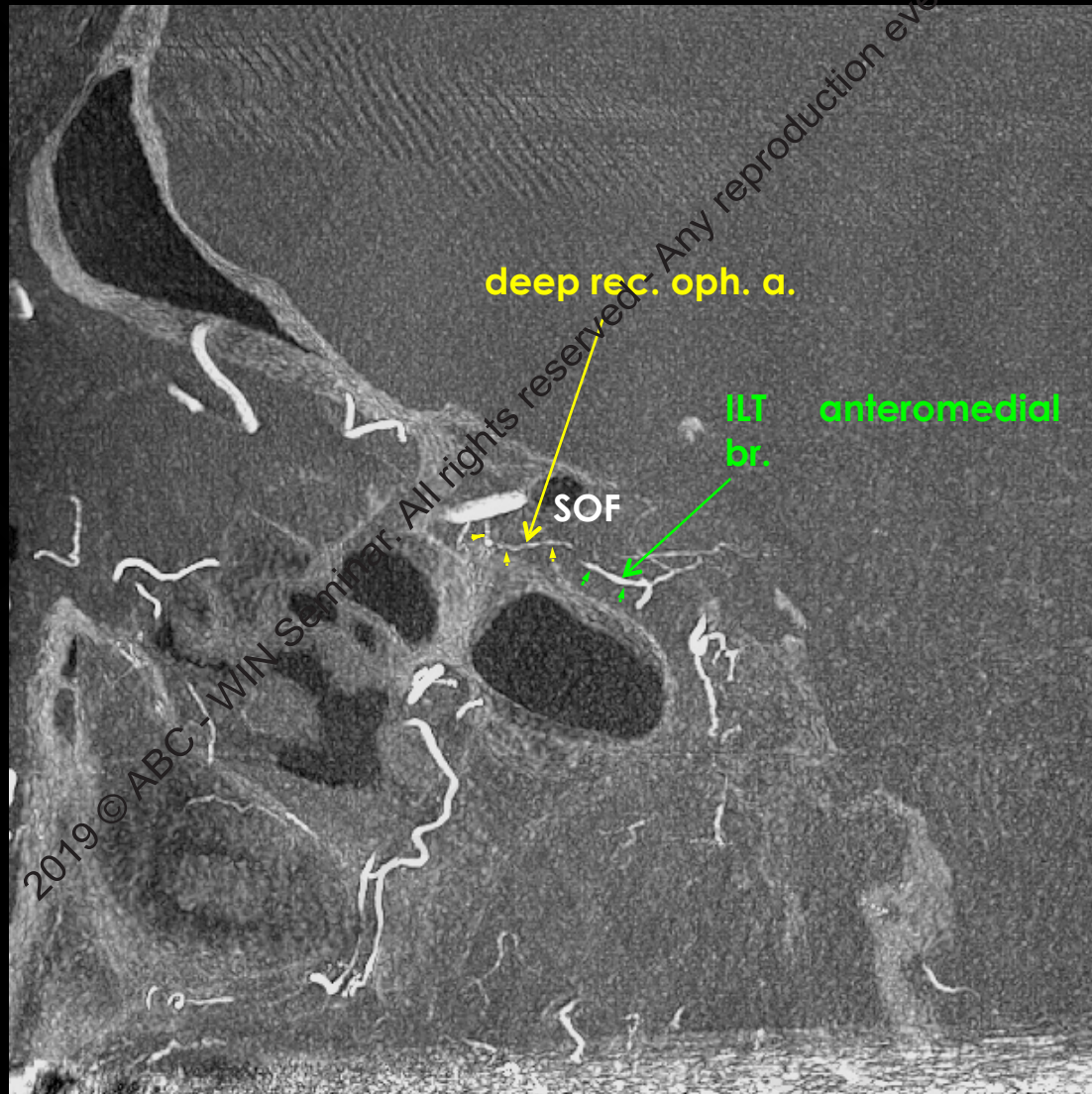
3DRA slab MIP  
sagittal



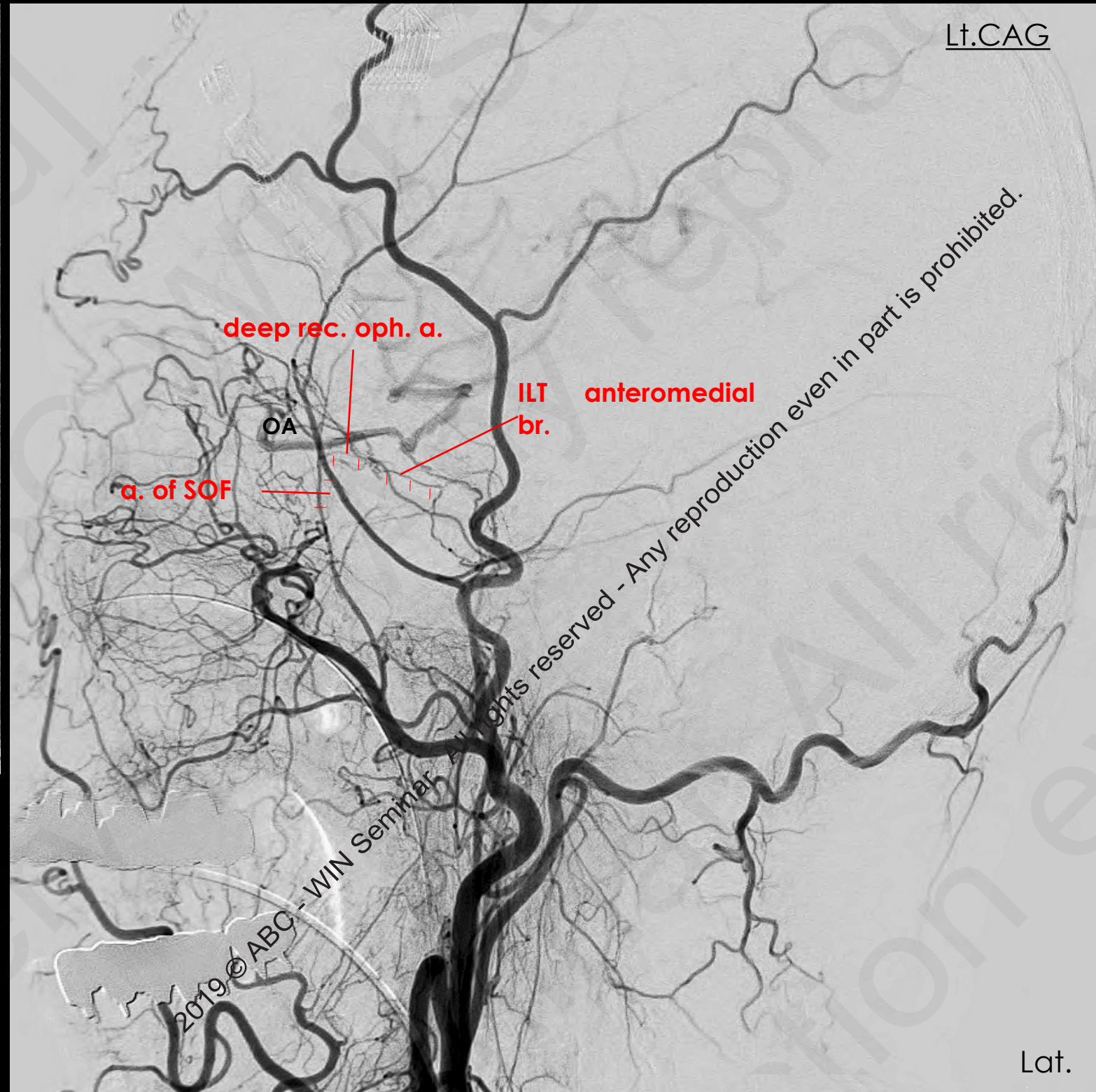


# deep recurrent ophthalmic a. - artery of SOF

## - ILT anteromedial br.



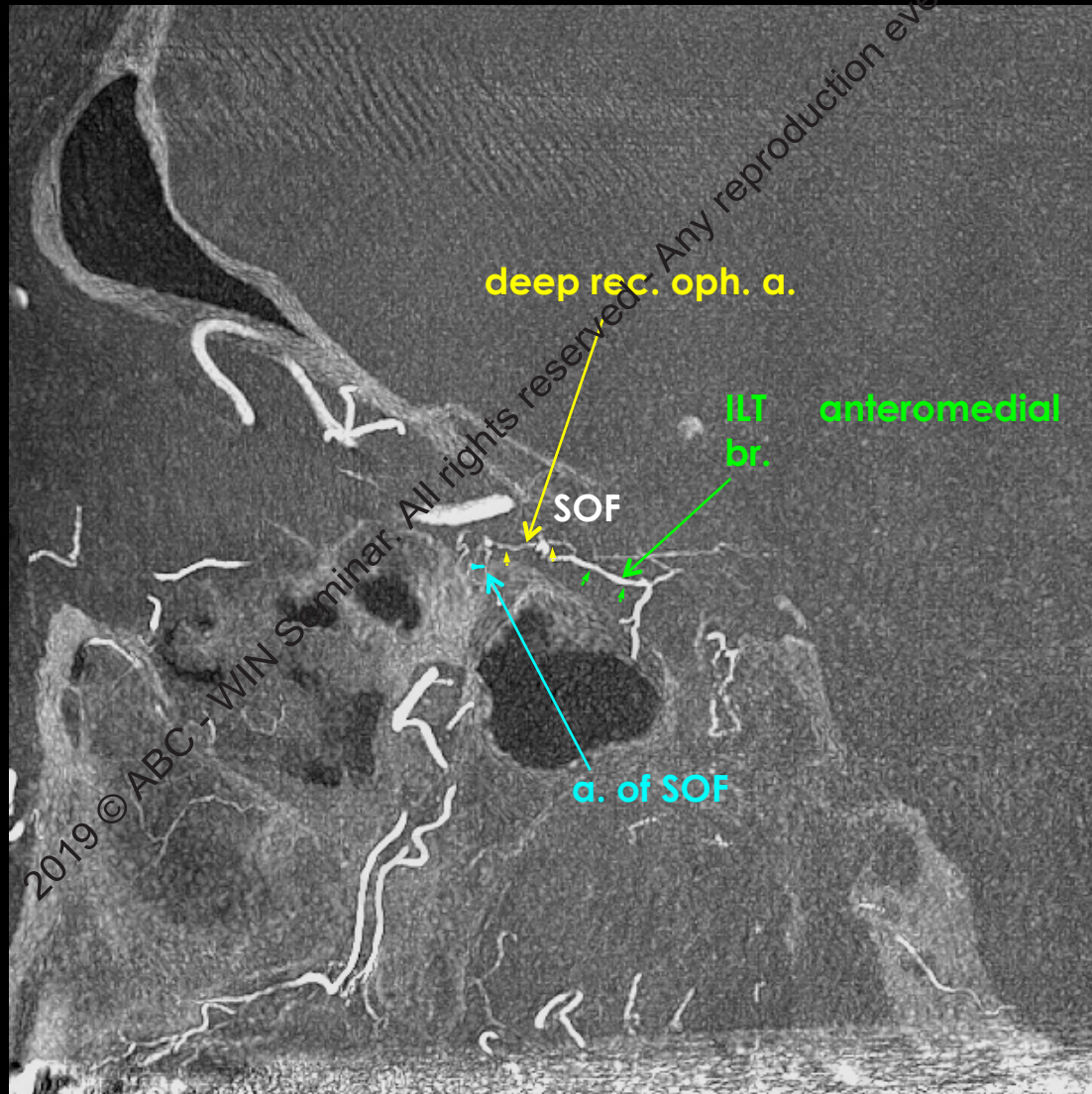
3DRA slab MIP  
sagittal



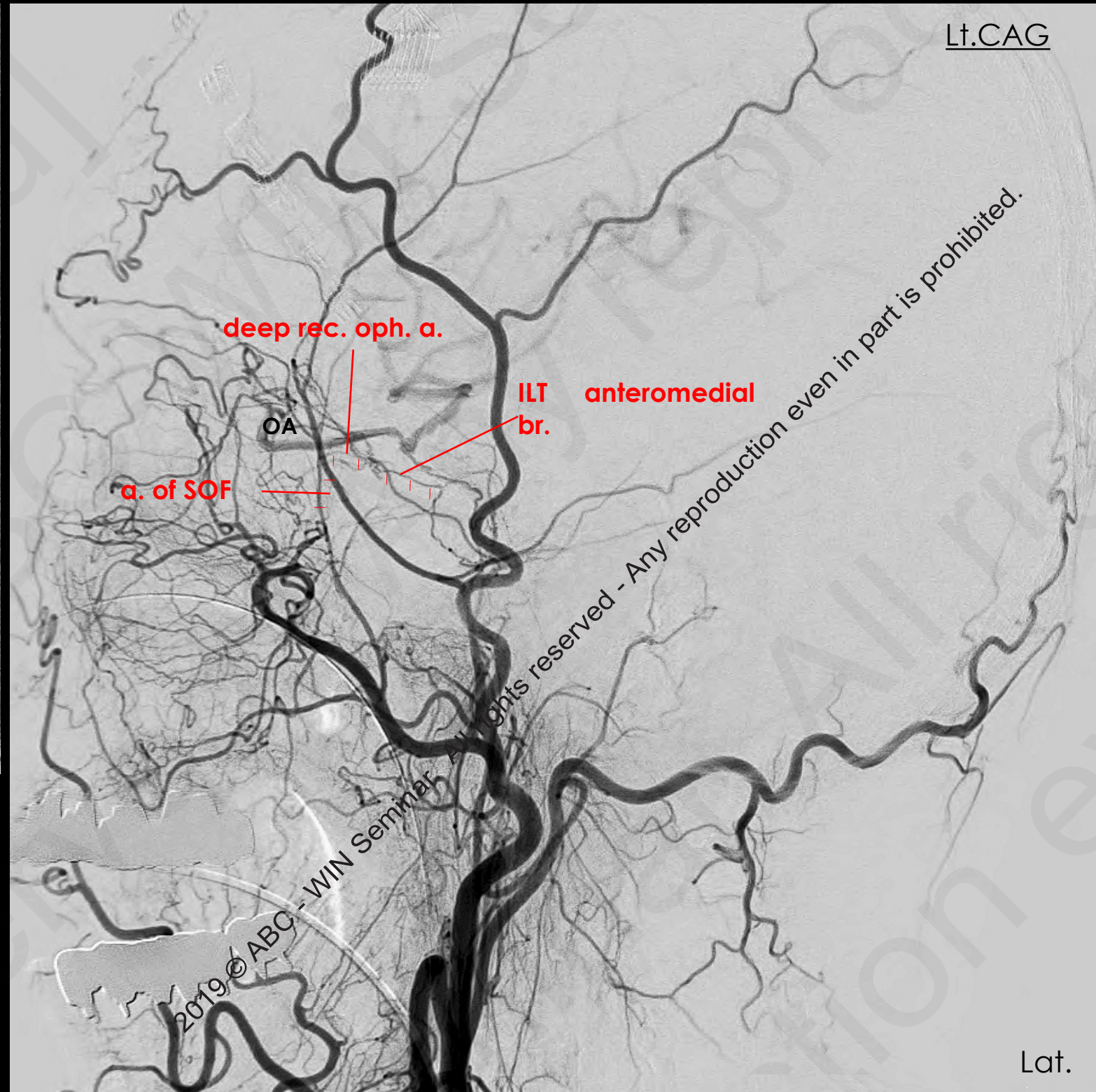


# deep recurrent ophthalmic a. - artery of SOF

## - ILT anteromedial br.

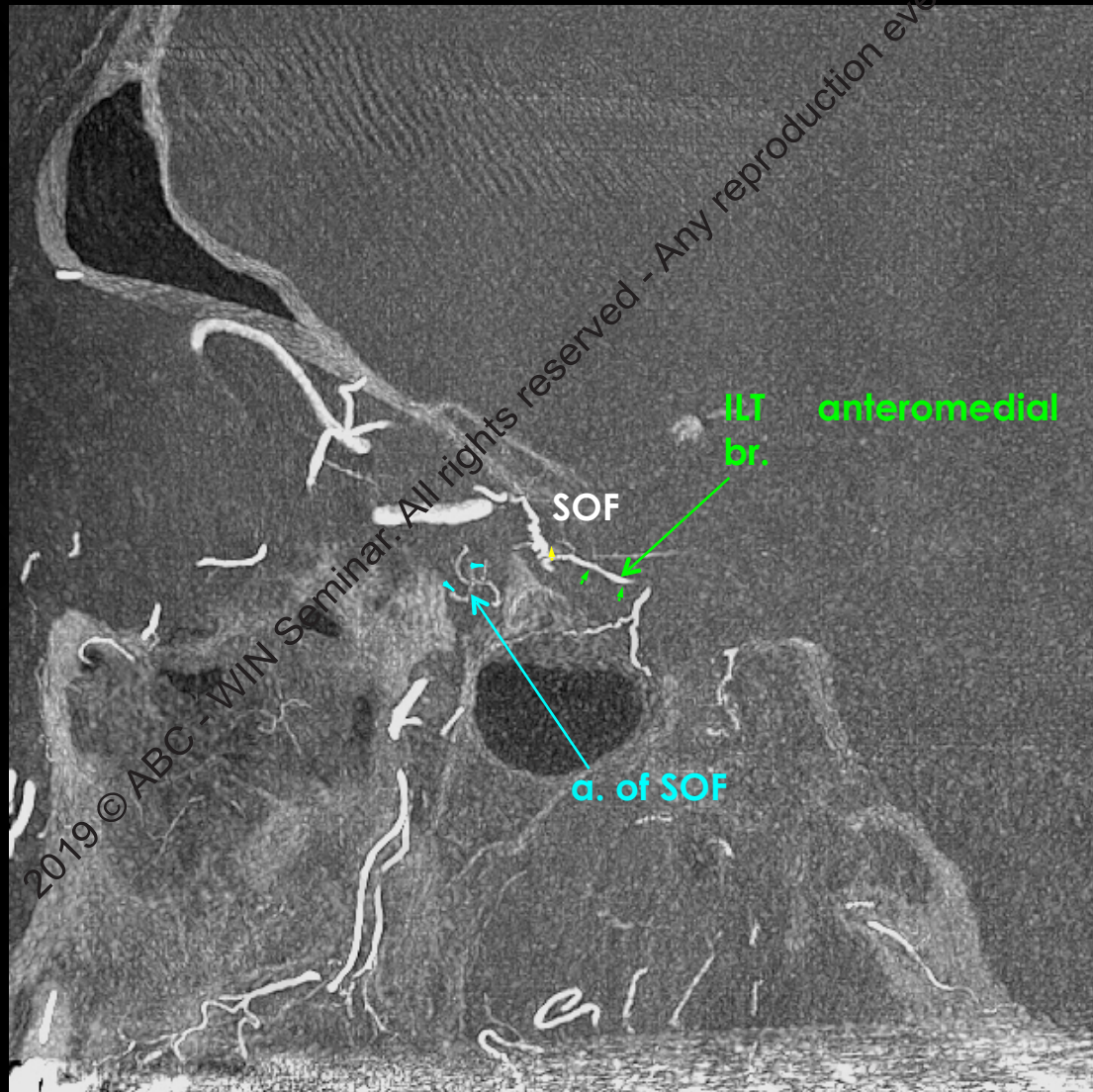


3DRA slab MIP  
sagittal

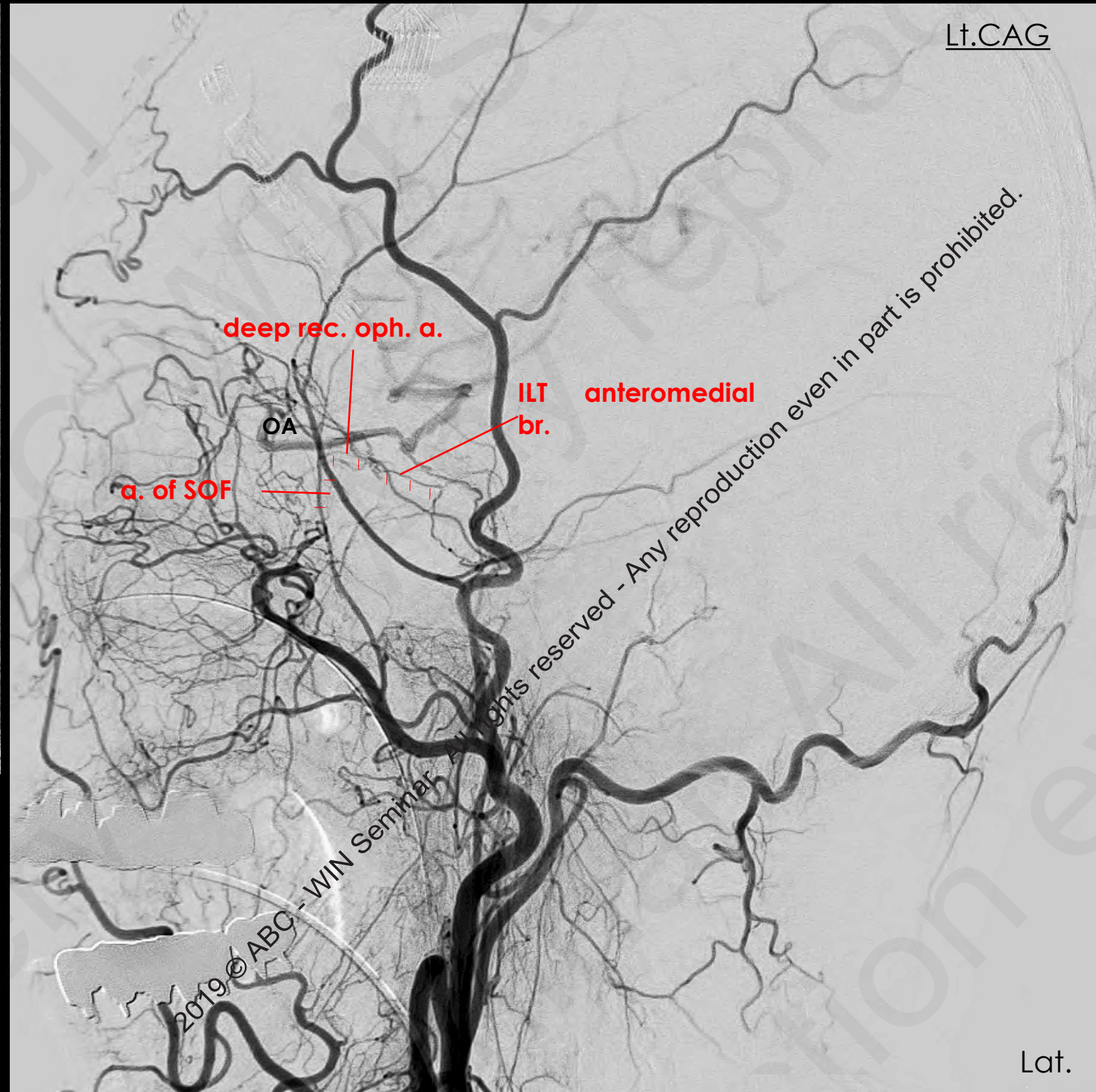




# deep recurrent ophthalmic a. - artery of SOF - ILT anteromedial br.

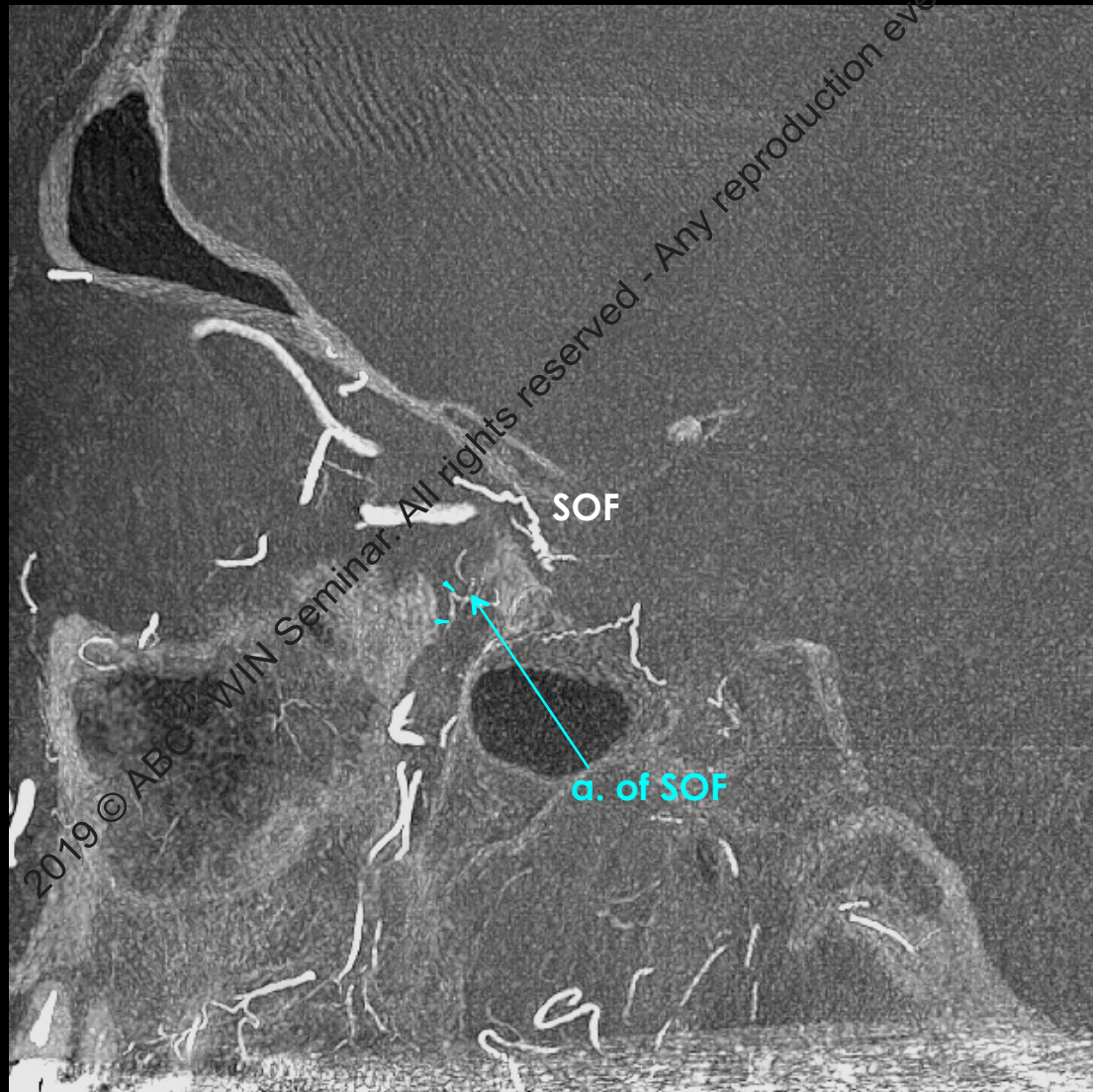


3DRA slab MIP  
sagittal

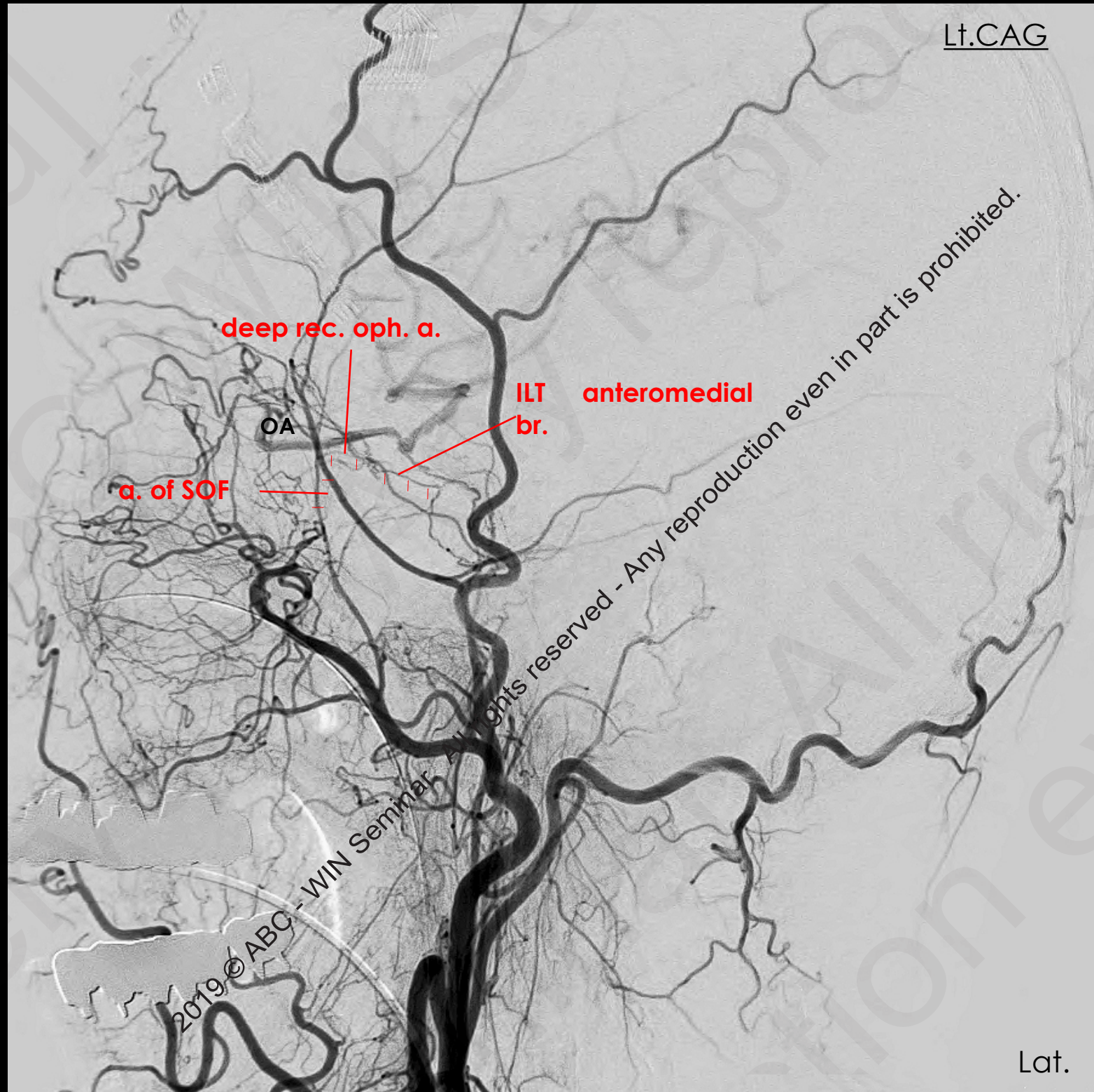




# deep recurrent ophthalmic a. - artery of SOF - ILT anteromedial br.

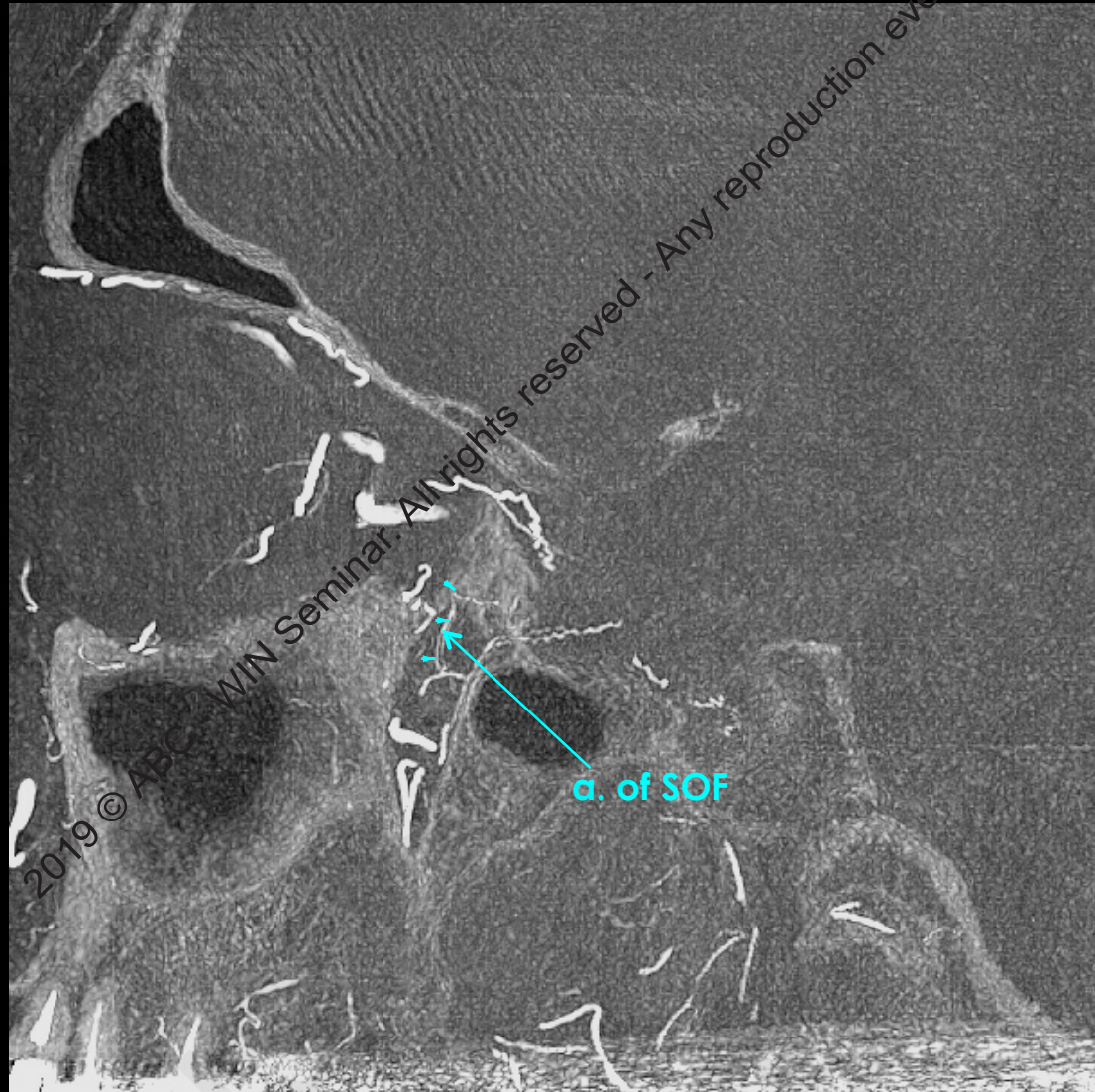

3DRA slab MIP  
sagittal

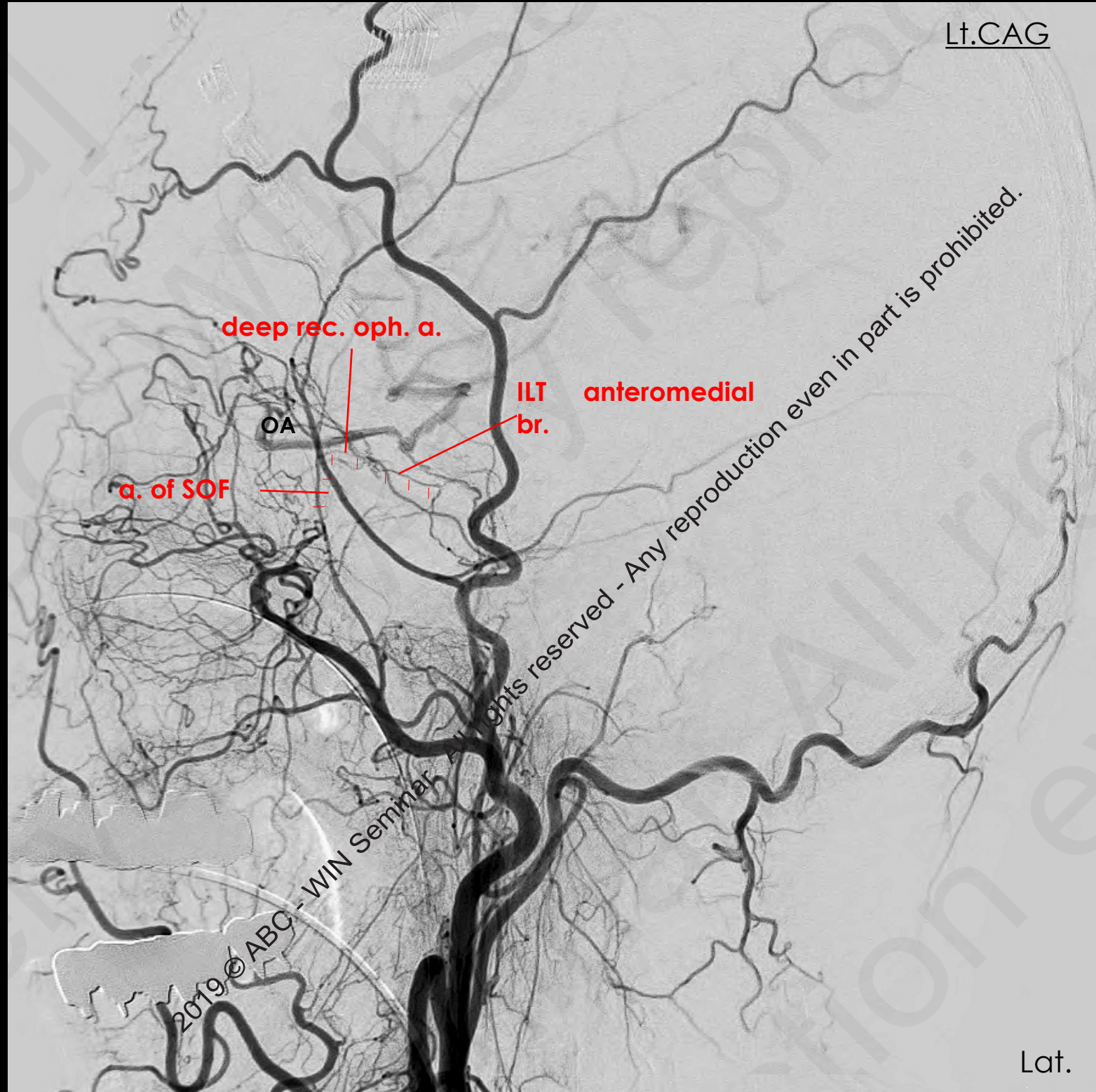




# deep recurrent ophthalmic a. - artery of SOF - ILT anteromedial br.



3DRA slab MIP  
sagittal





**ethmoid sinus**

anterior ethmoidal a.      posterior ethmoidal a.

supraorbital a.  
medial frontal a.  
dorsal nasal a.

**SOF (lateral)**

middle meningeal a. (anterior br.)  
recurrent meningeal a.

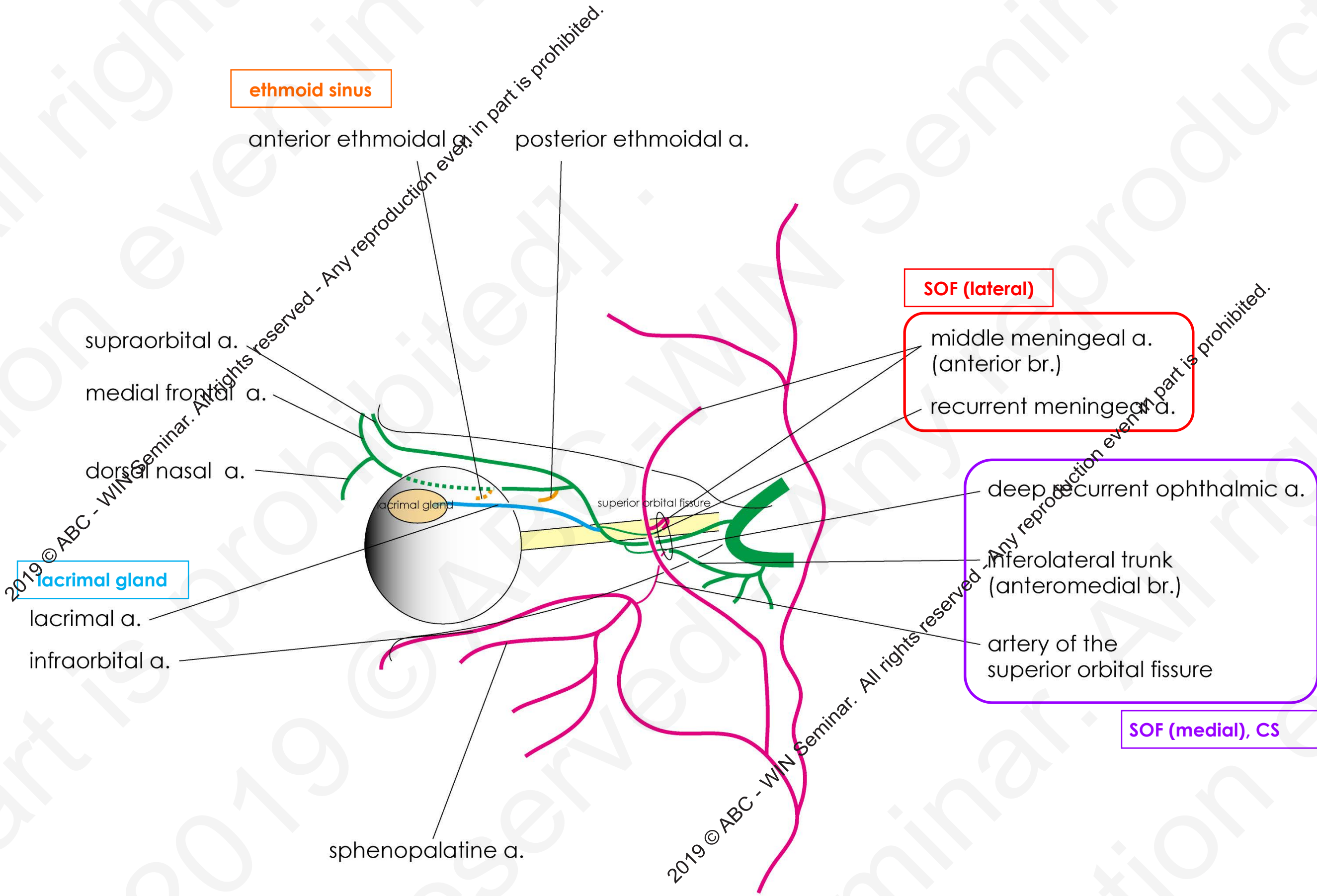
deep recurrent ophthalmic a.  
inferolateral trunk (anteromedial br.)  
artery of the superior orbital fissure

**lacrimal gland**

lacrimal a.  
infraorbital a.

**SOF (medial), CS**

sphenopalatine a.



2019 © ABC - WIN Seminar. All rights reserved. Any reproduction even in part is prohibited.

2019 © ABC - WIN Seminar. All rights reserved. Any reproduction even in part is prohibited.

**ethmoid sinus**

anterior ethmoidal a.      posterior ethmoidal a.

supraorbital a.  
medial frontal a.  
dorsal nasal a.

lacrimal a.  
infraorbital a.  
(orbital br.)  
anterior deep temporal a.

**lacrimal gland**

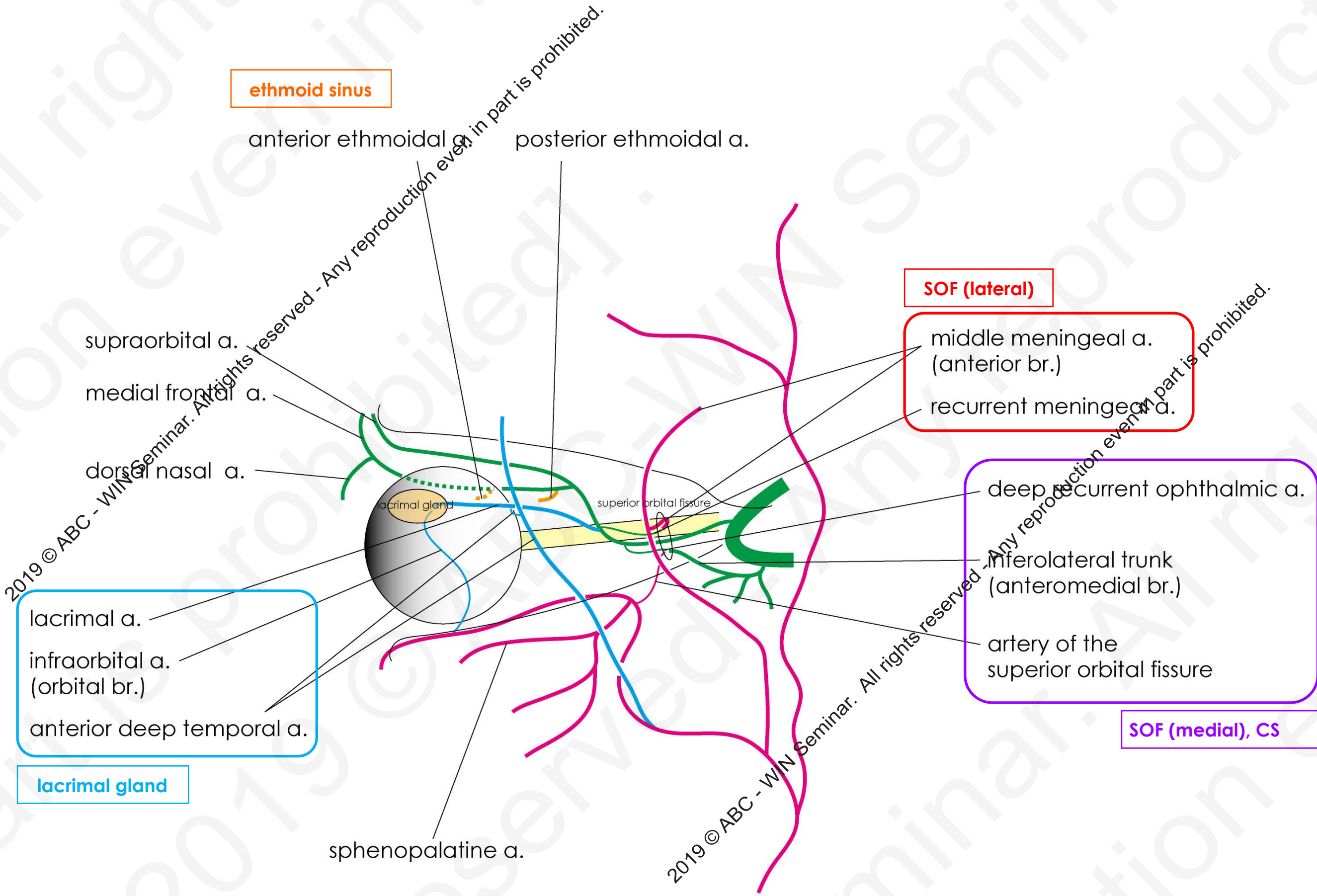
sphenopalatine a.

**SOF (lateral)**

middle meningeal a.  
(anterior br.)  
recurrent meningeal a.

deep recurrent ophthalmic a.  
inferolateral trunk  
(anteromedial br.)  
artery of the  
superior orbital fissure

**SOF (medial), CS**



2019 © ABC - WIN Seminar. All rights reserved - Any reproduction even in part is prohibited.

2019 © ABC - WIN Seminar. All rights reserved - Any reproduction even in part is prohibited.



**ethmoid sinus**

anterior ethmoidal a.      posterior ethmoidal a.

supraorbital a.  
medial frontal a.  
dorsal nasal a.

lacrimal a.  
infraorbital a.  
(orbital br.)  
anterior deep temporal a.

**lacrimal gland**

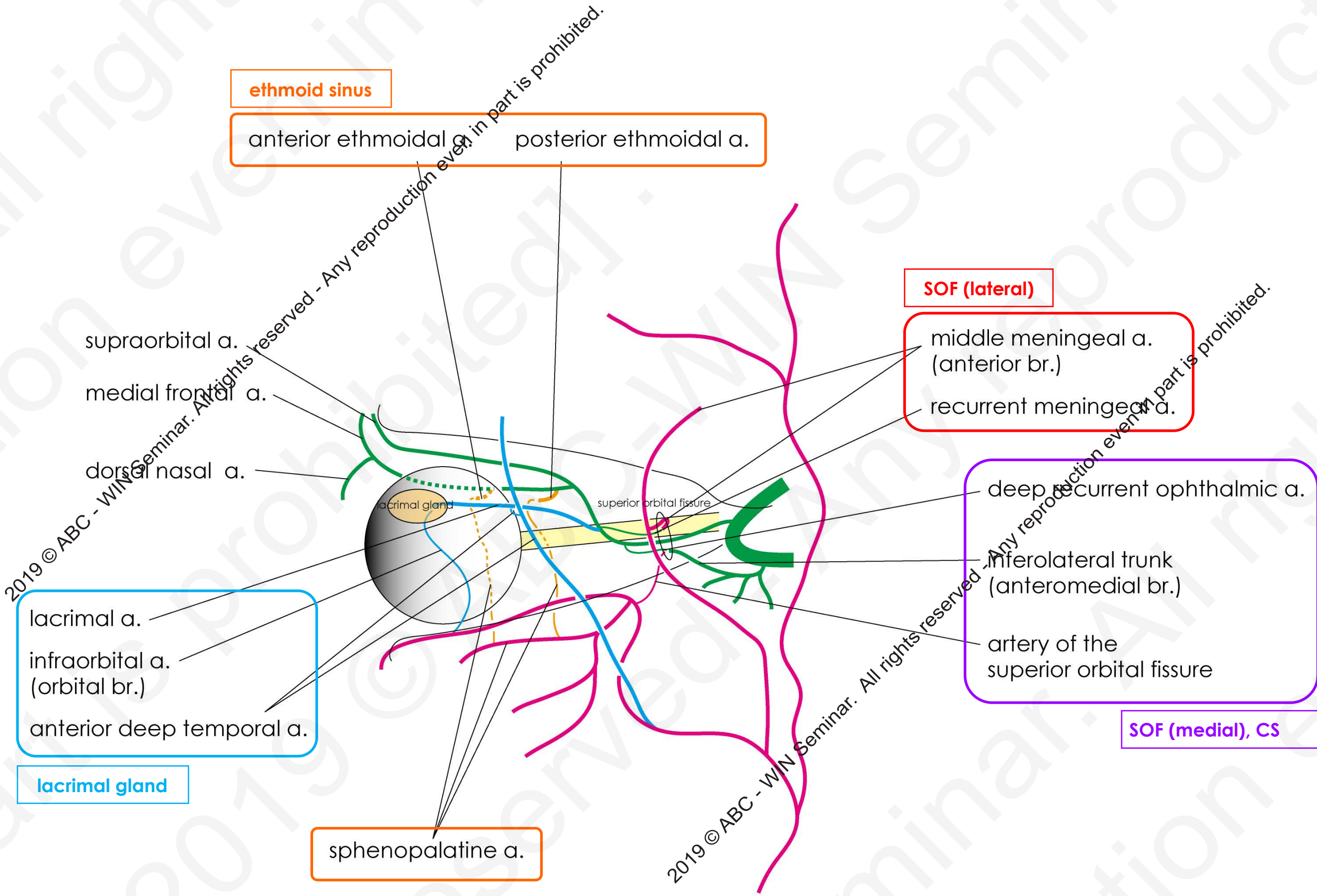
sphenopalatine a.

**SOF (lateral)**

middle meningeal a.  
(anterior br.)  
recurrent meningeal a.

deep recurrent ophthalmic a.  
inferolateral trunk  
(anteromedial br.)  
artery of the  
superior orbital fissure

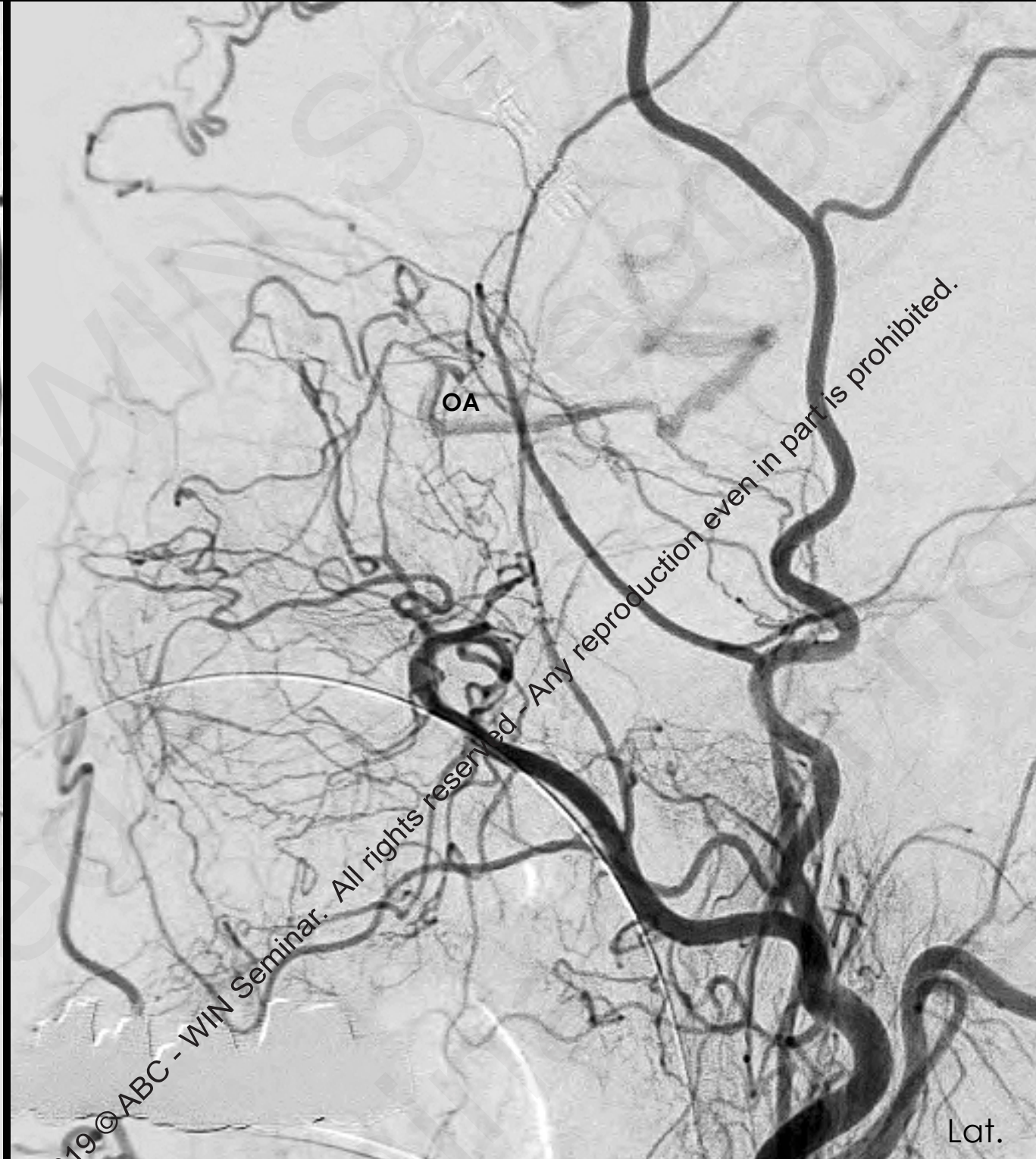
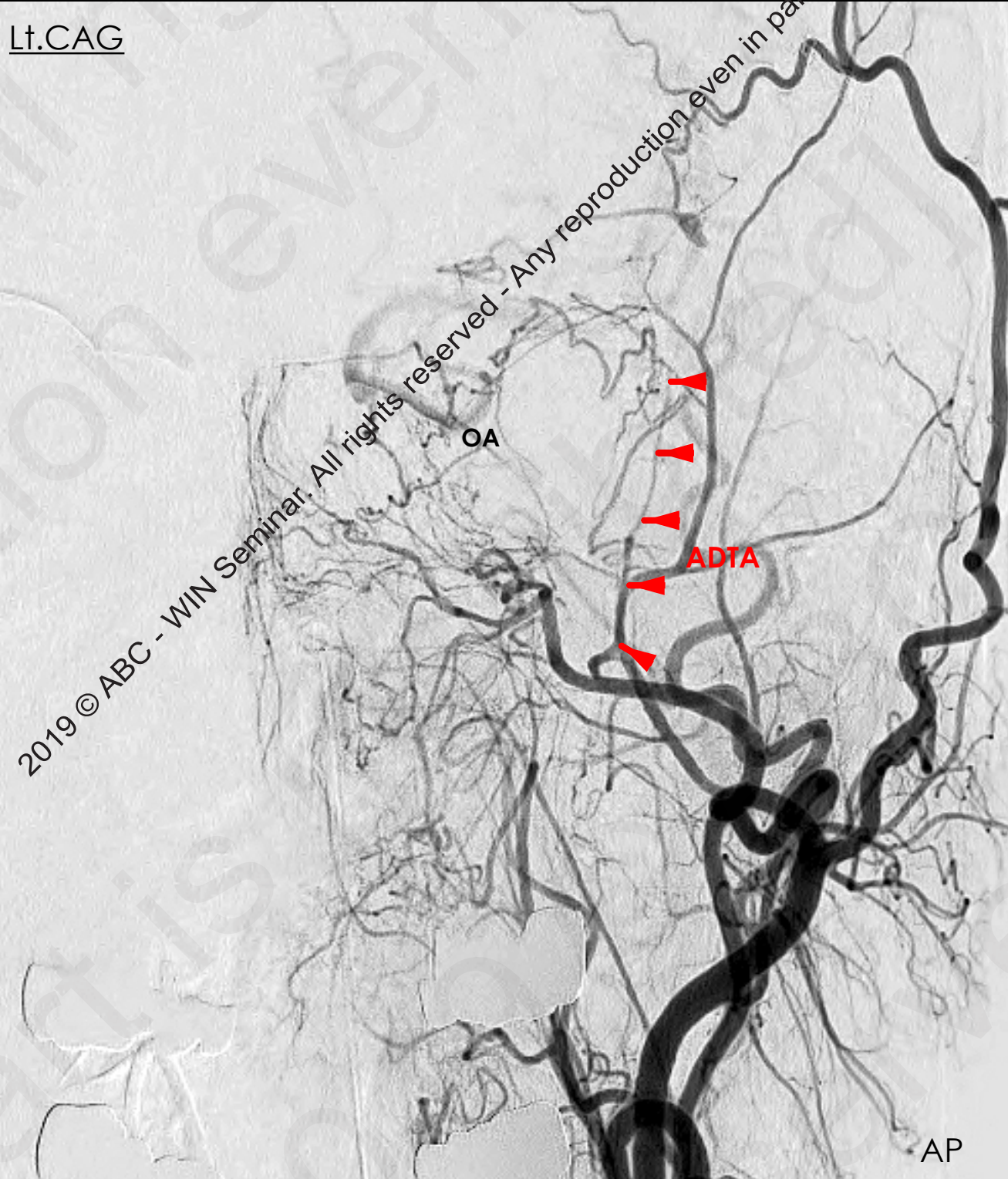**SOF (medial), CS**





# lacrimal a. - ant. deep temporal a.

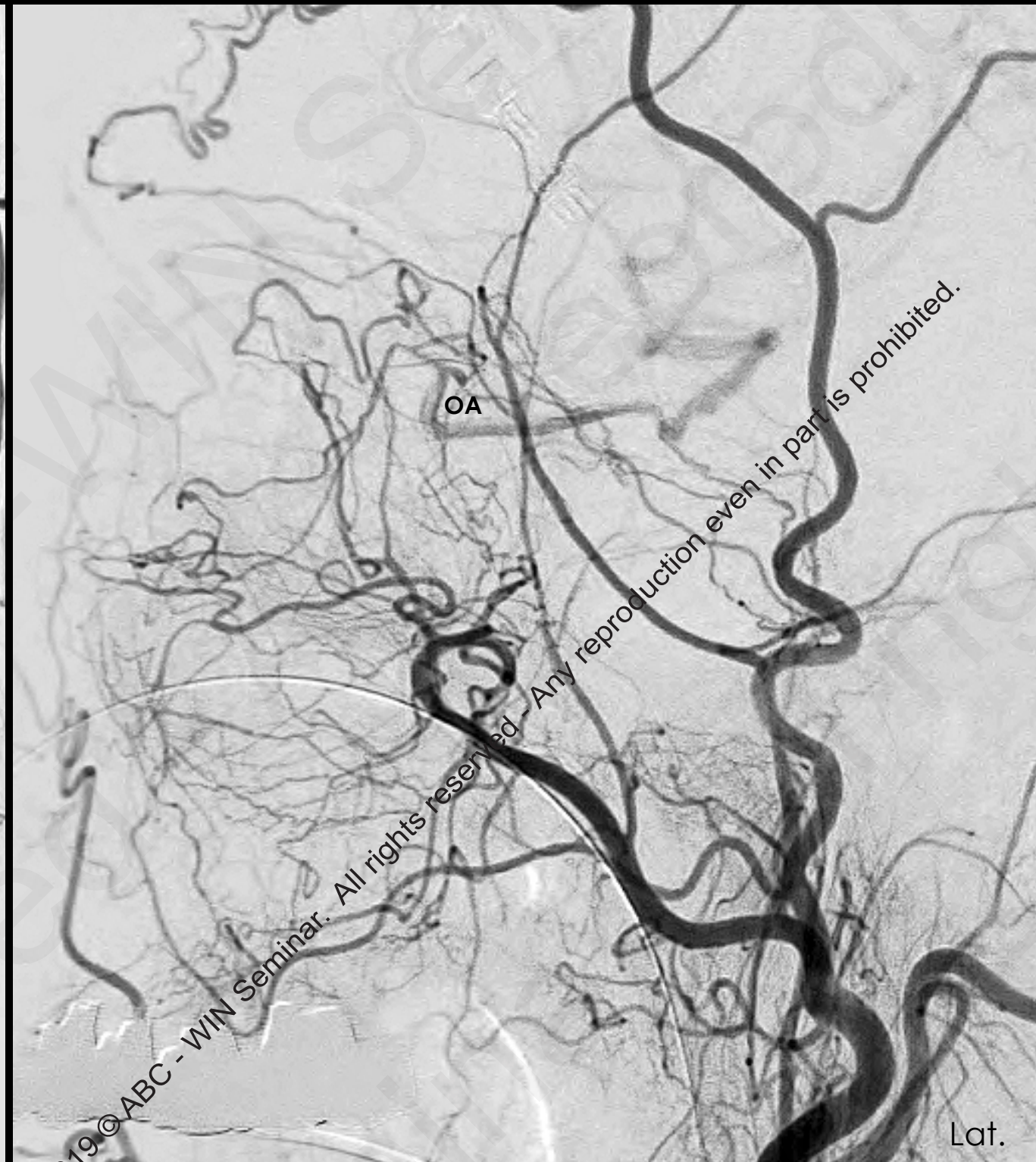
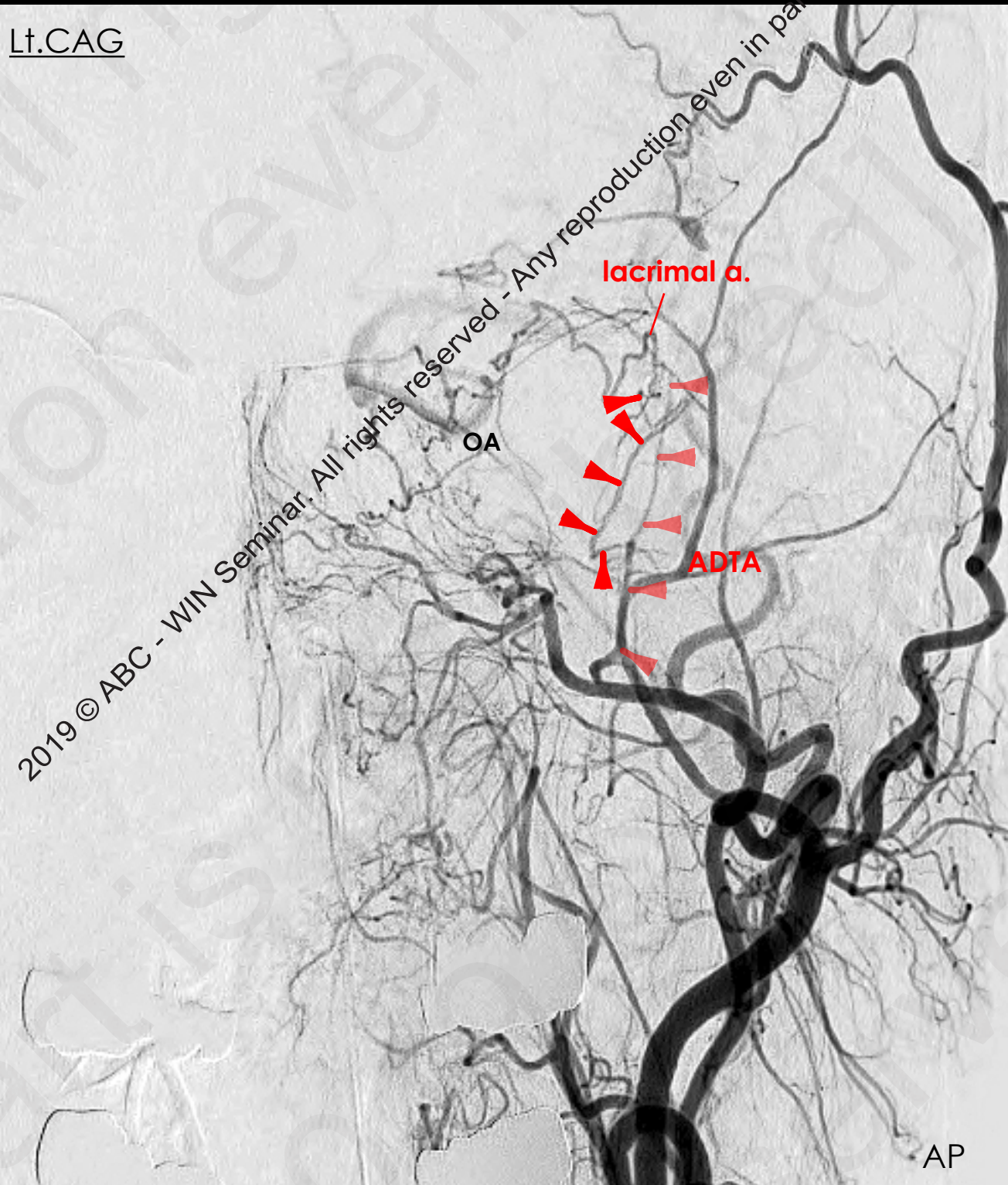Lt.CAG





# lacrimal a. - ant. deep temporal a.

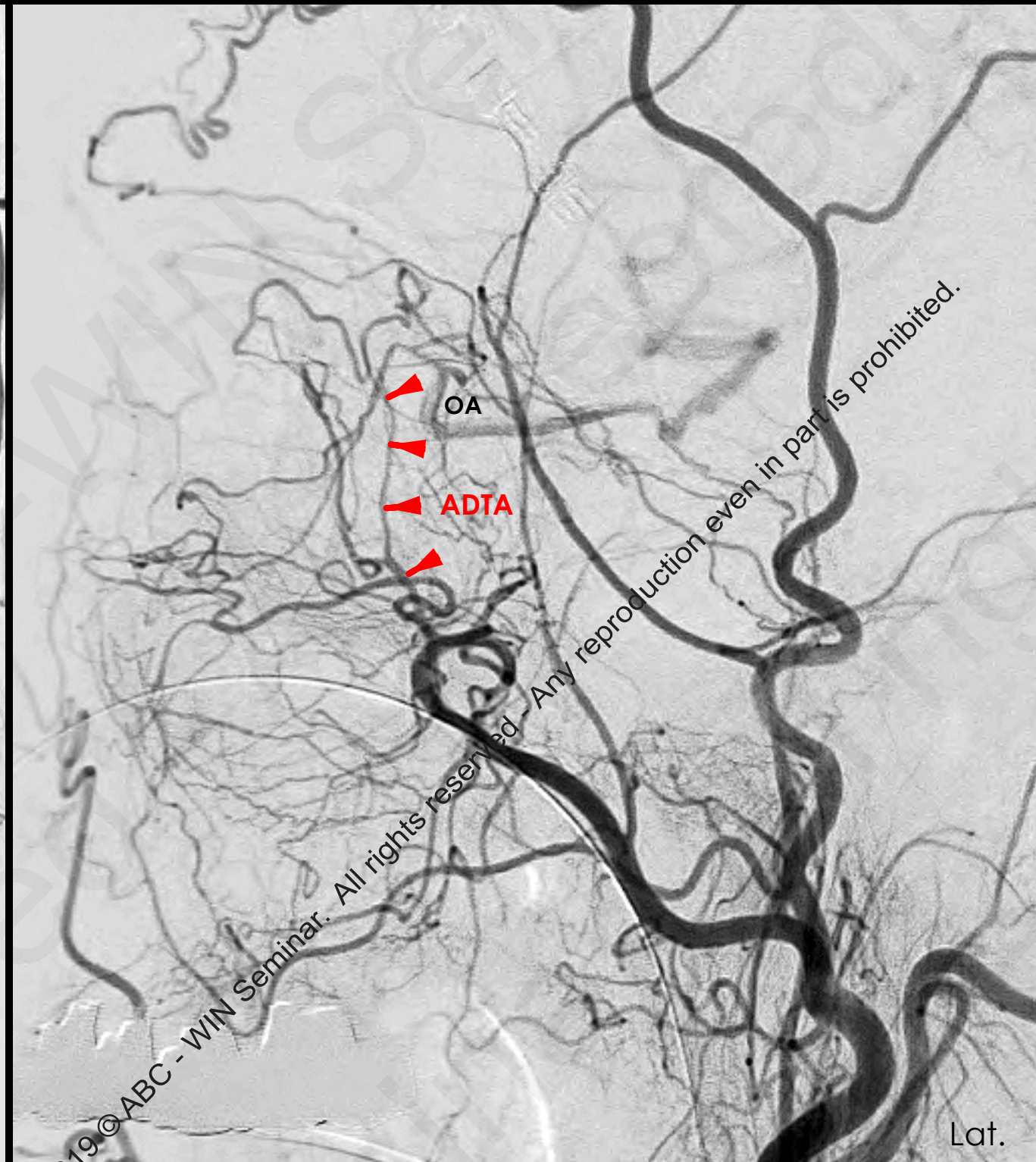
Lt.CAG





# lacrimal a. - ant. deep temporal a.

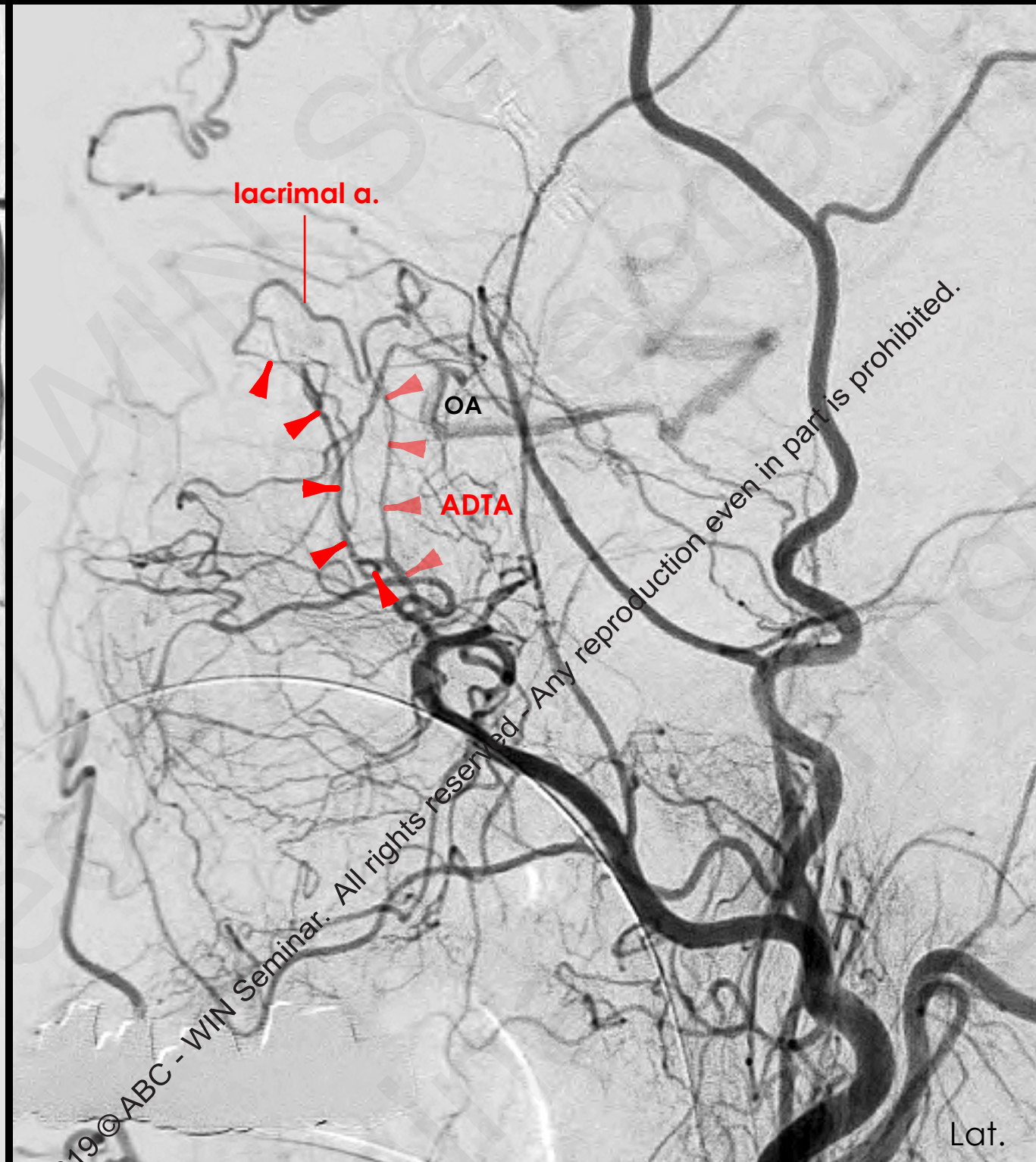
Lt.CAG





# lacrimal a. - ant. deep temporal a.

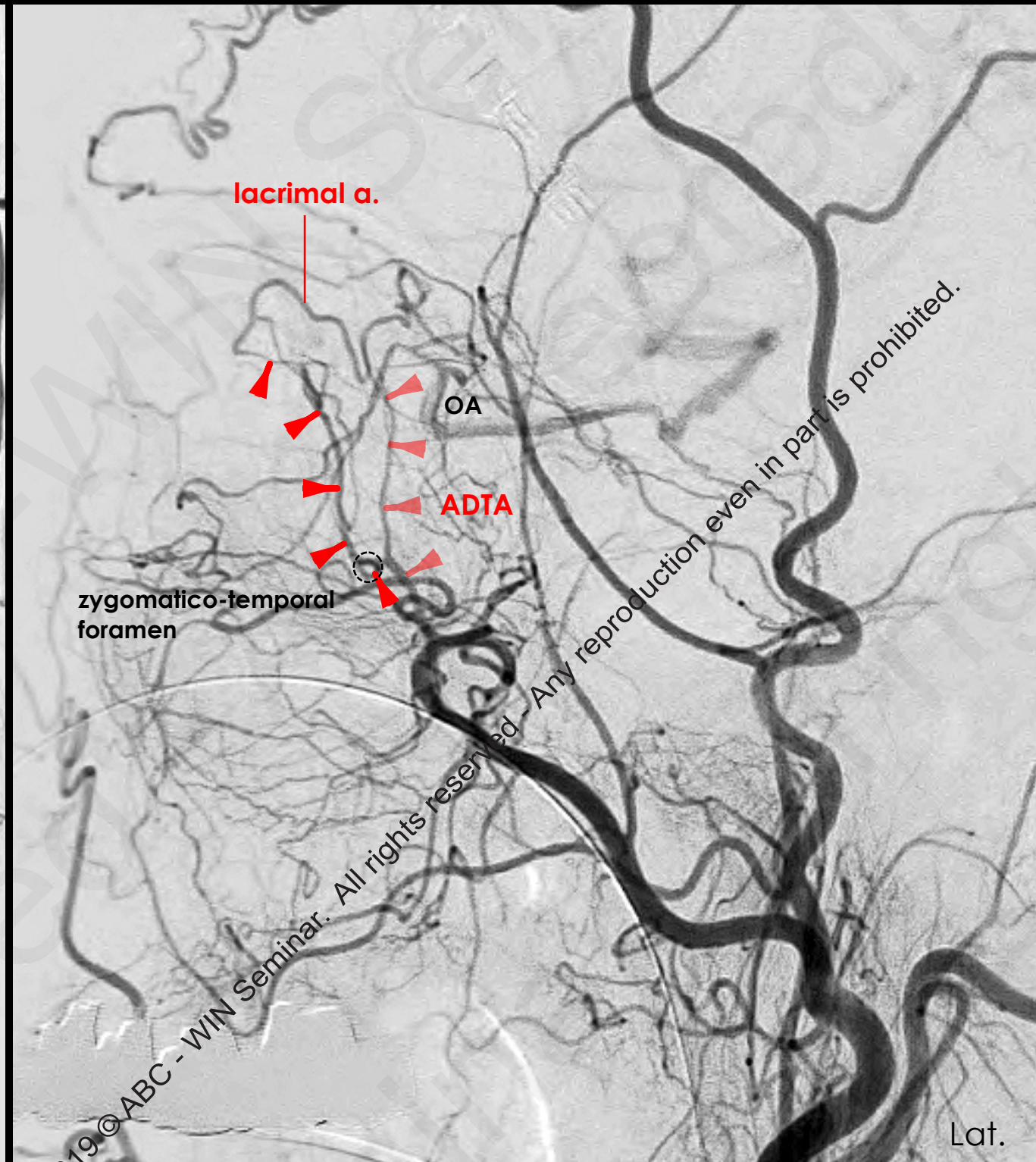
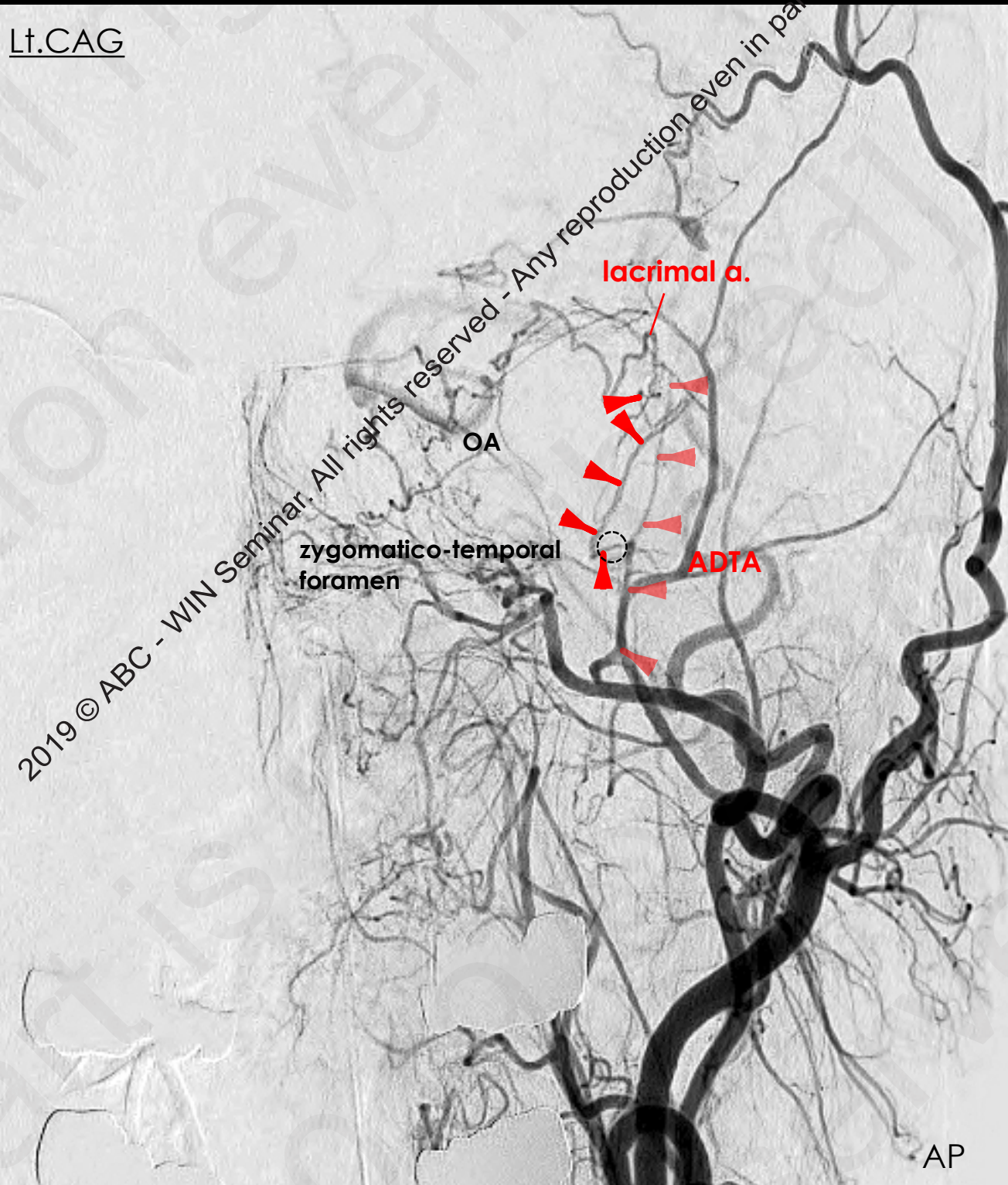
Lt.CAG





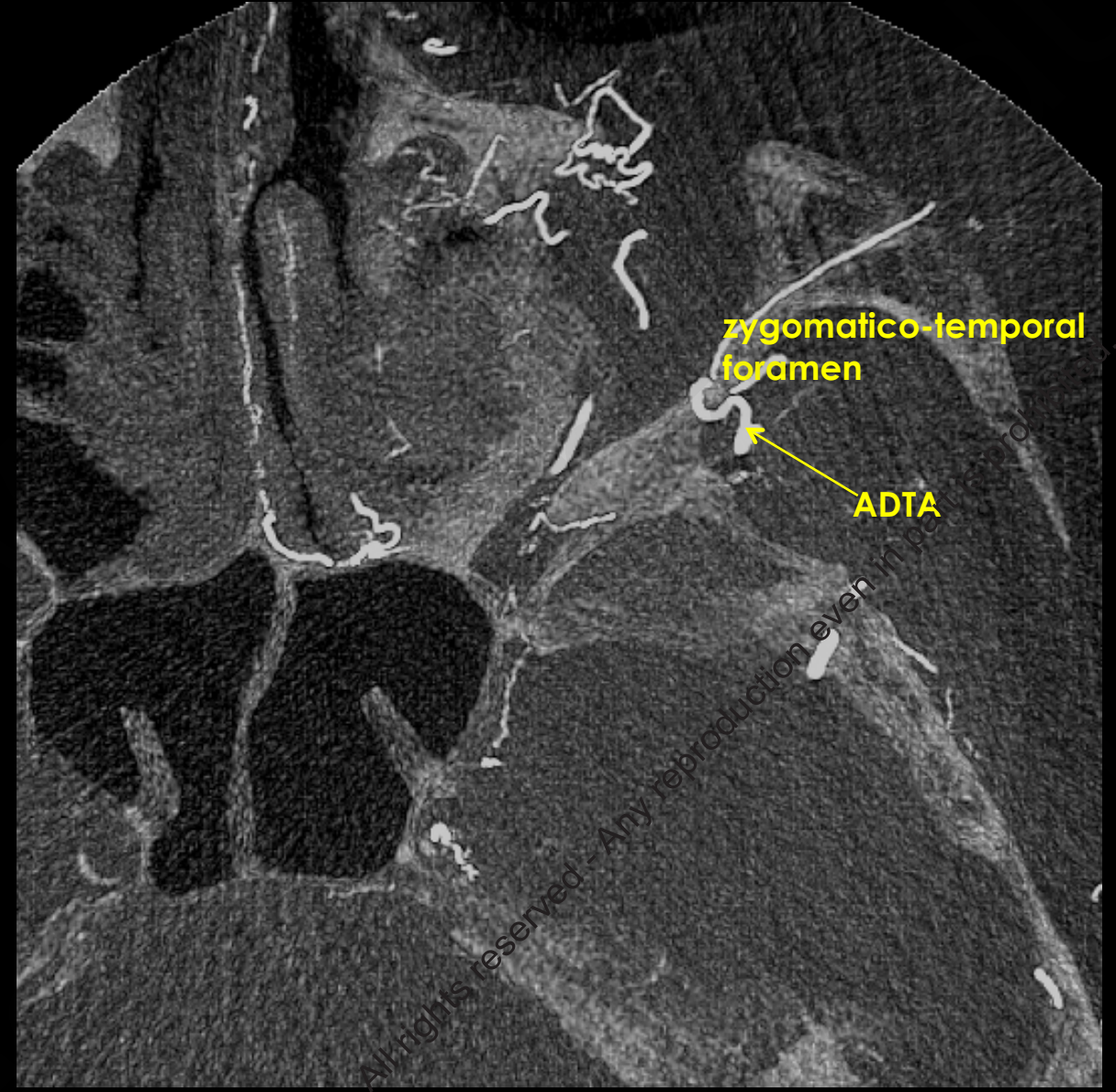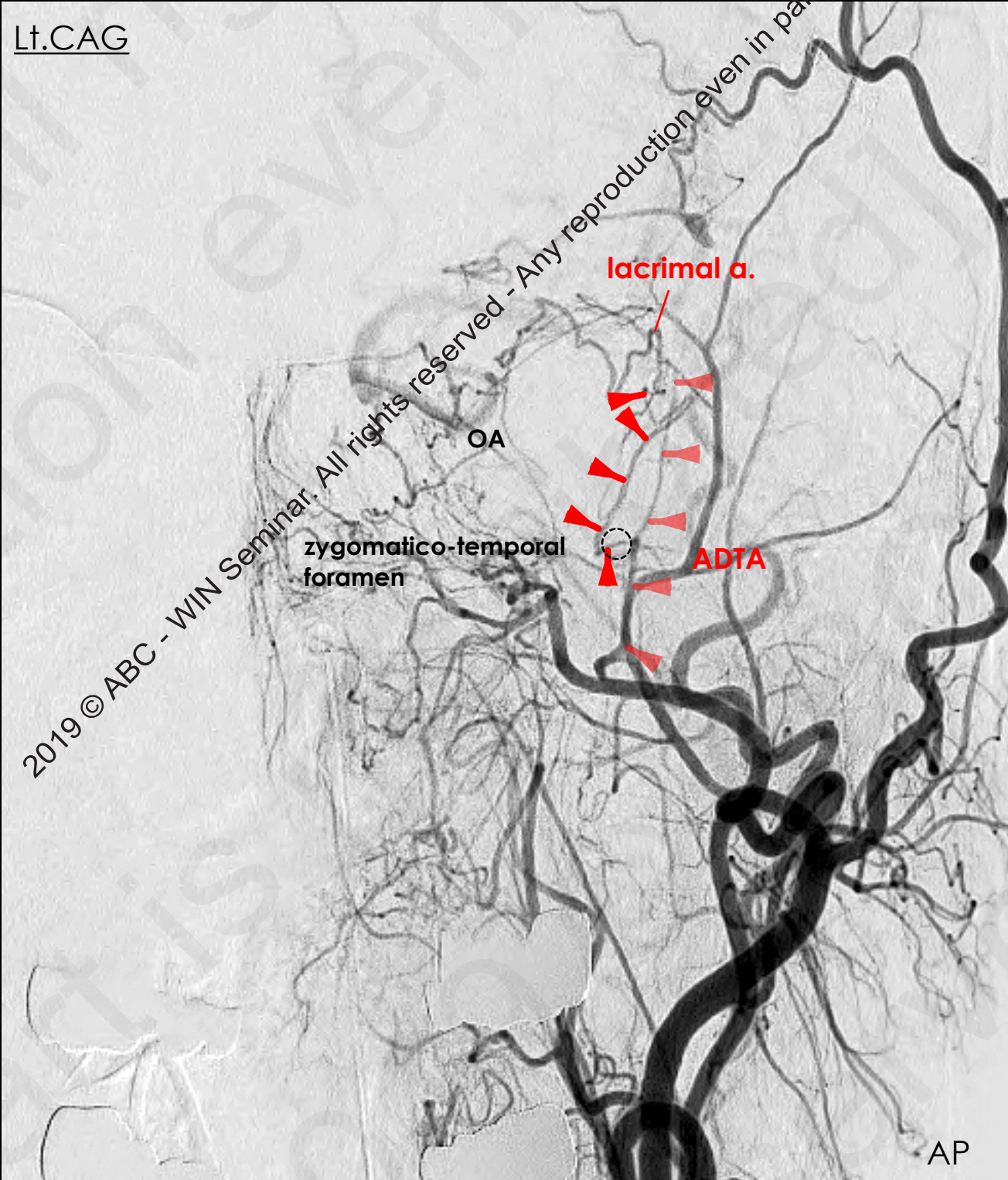
# lacrimal a. - ant. deep temporal a.

Lt.CAG





# lacrimal a. - ant. deep temporal a.

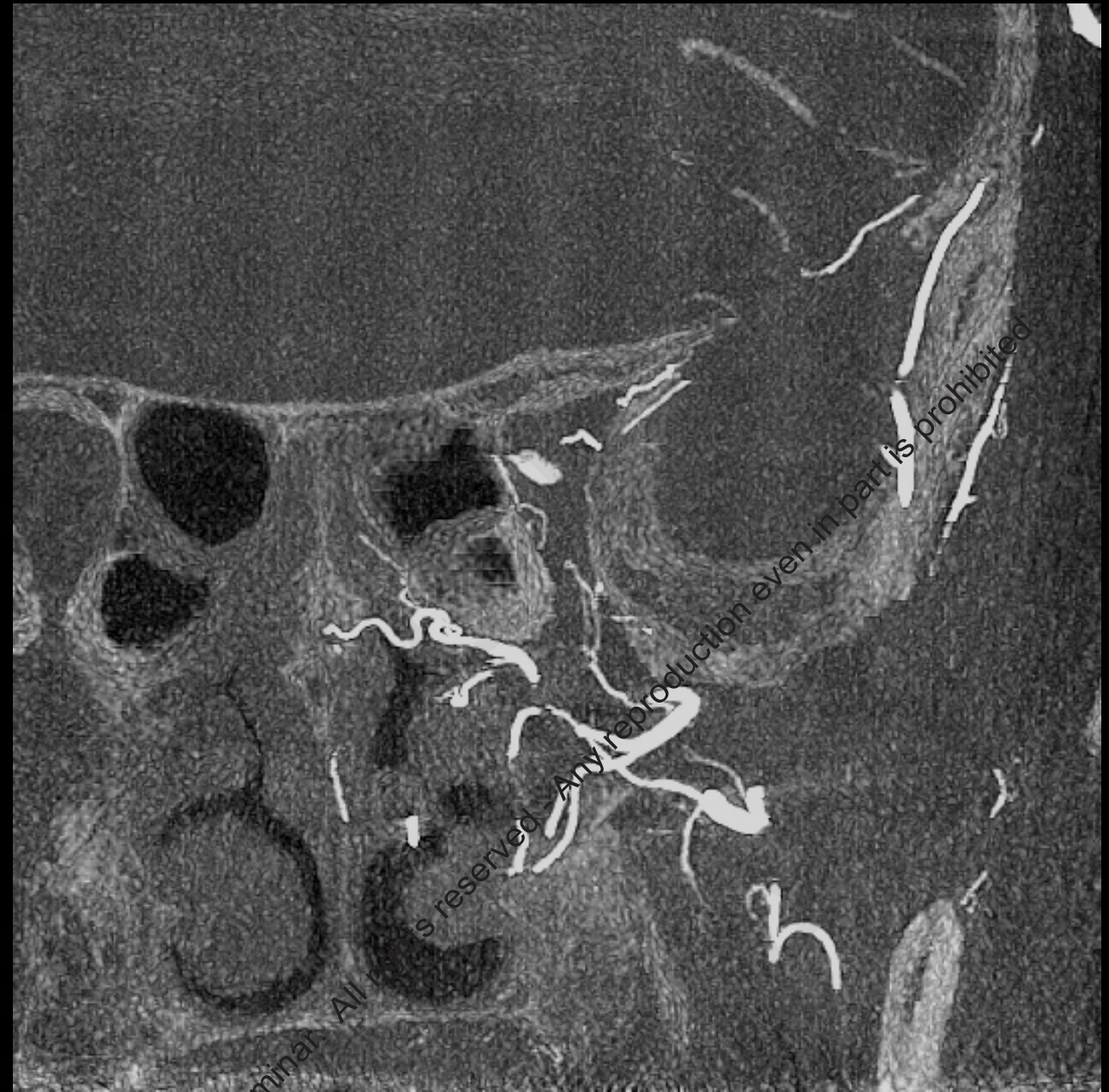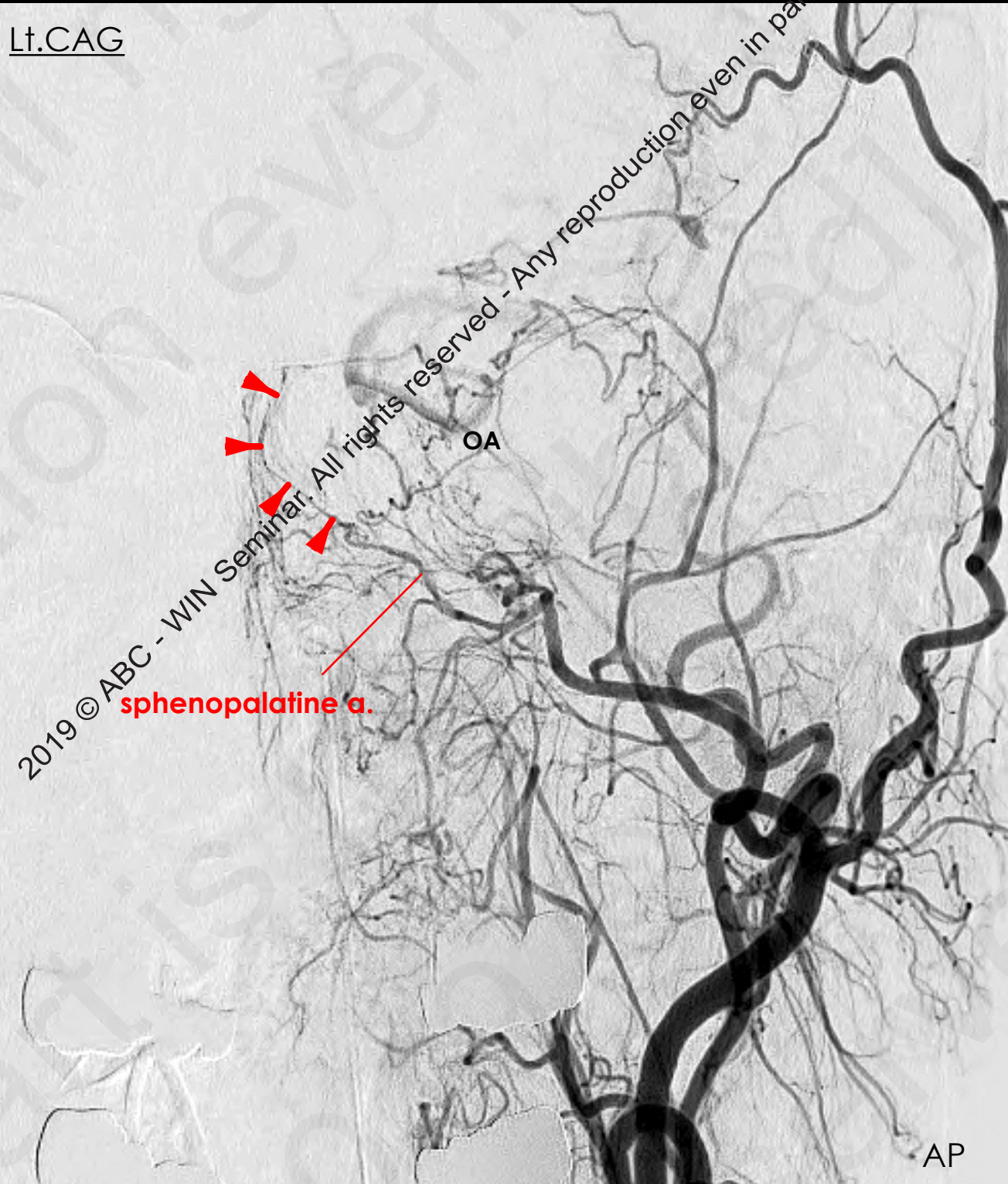


3DRA slab MIP  
axial



# ant. & post. ethmoidal a. – sphenopalatine a.

Lt.CAG

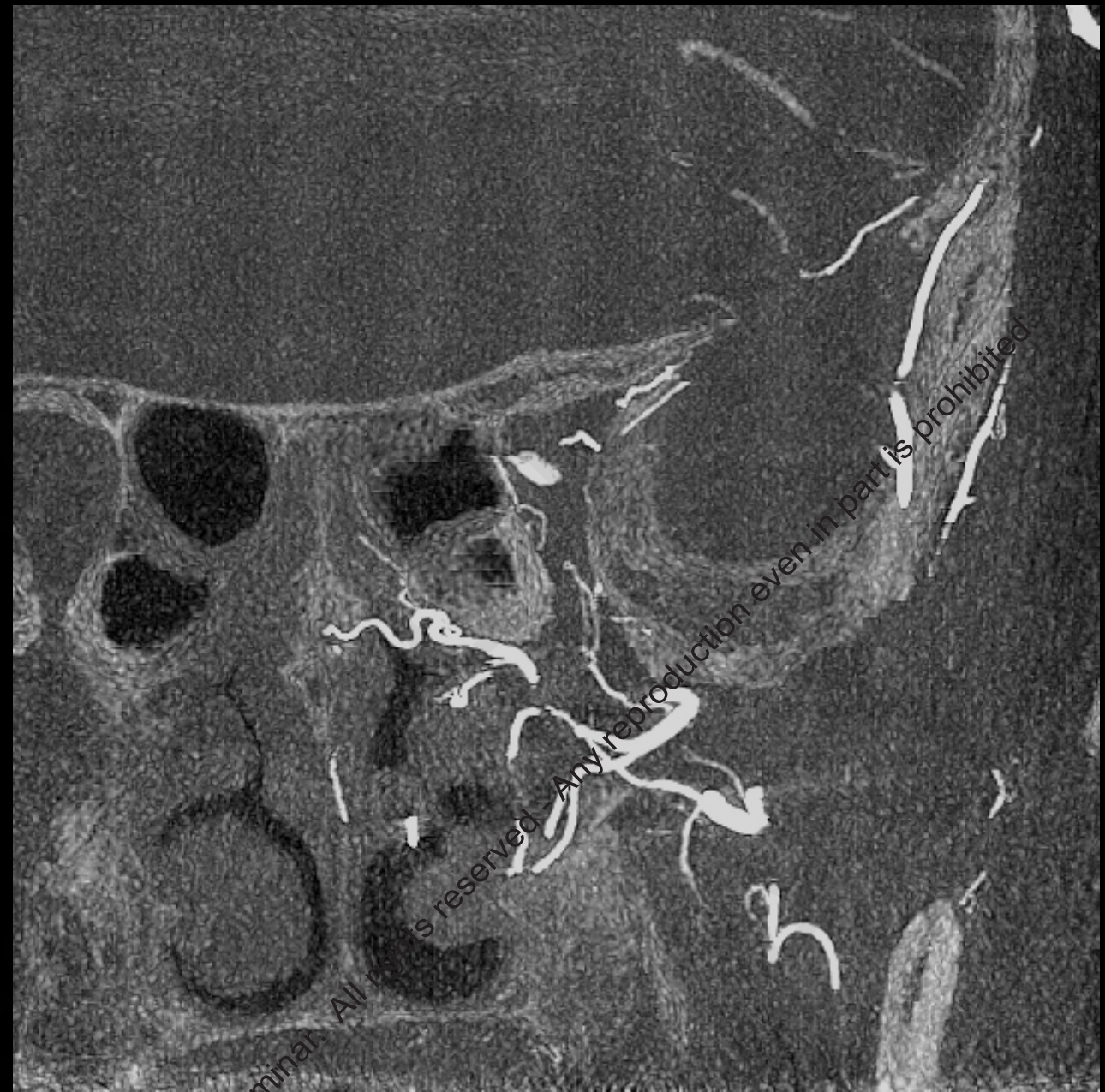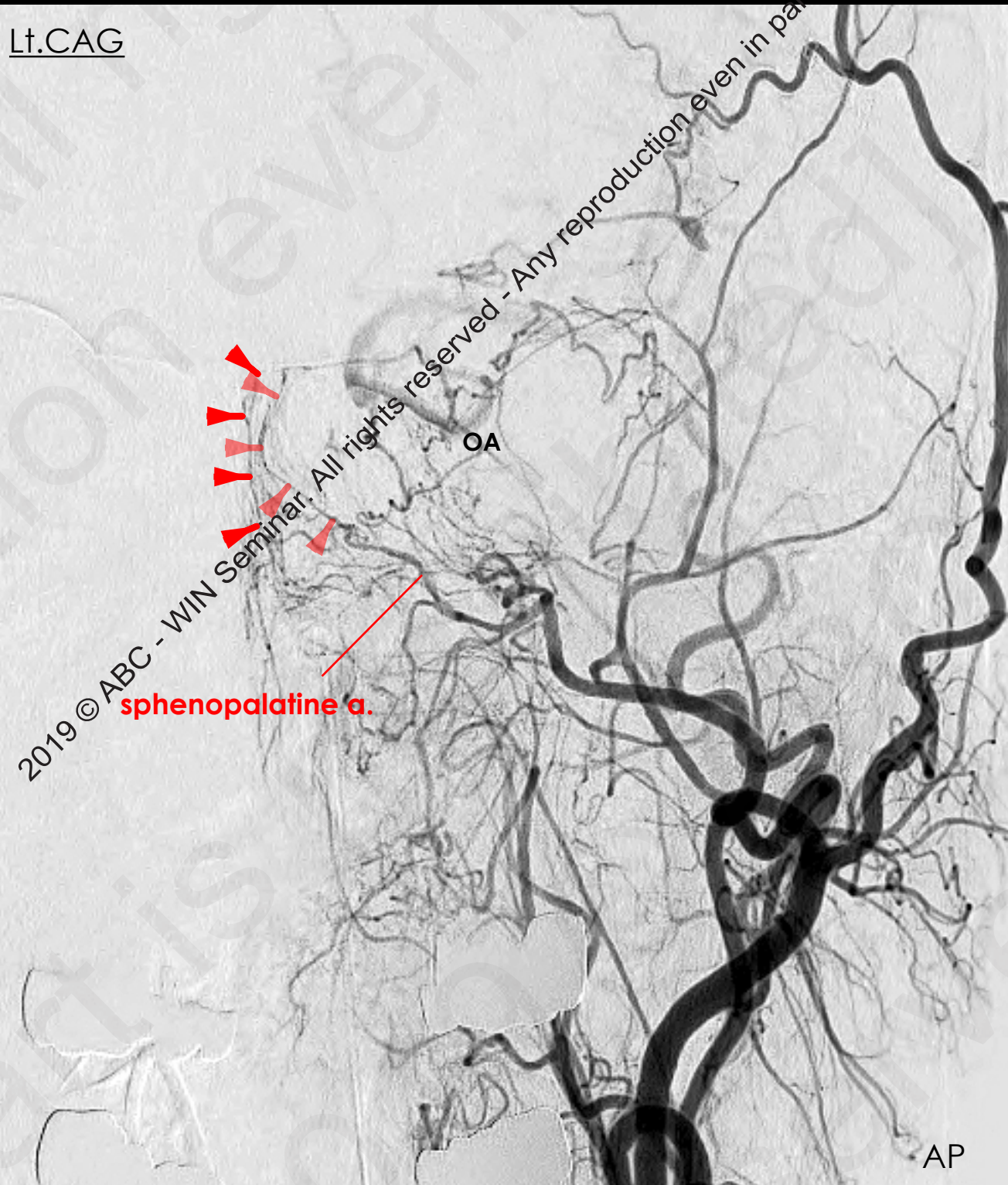


3DRA slab MIP  
coronal



# ant. & post. ethmoidal a. – sphenopalatine a.

Lt.CAG

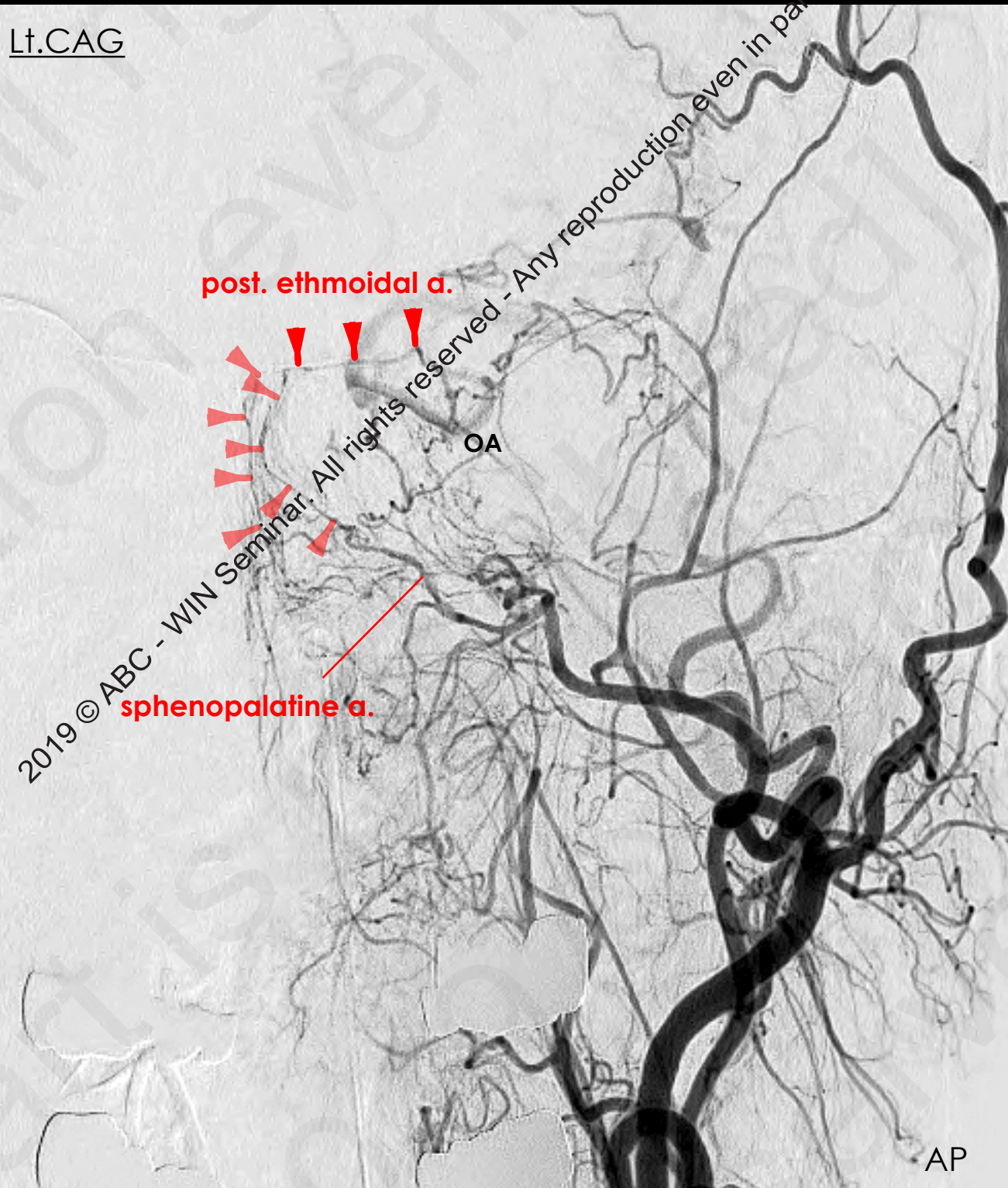


3DRA slab MIP  
coronal

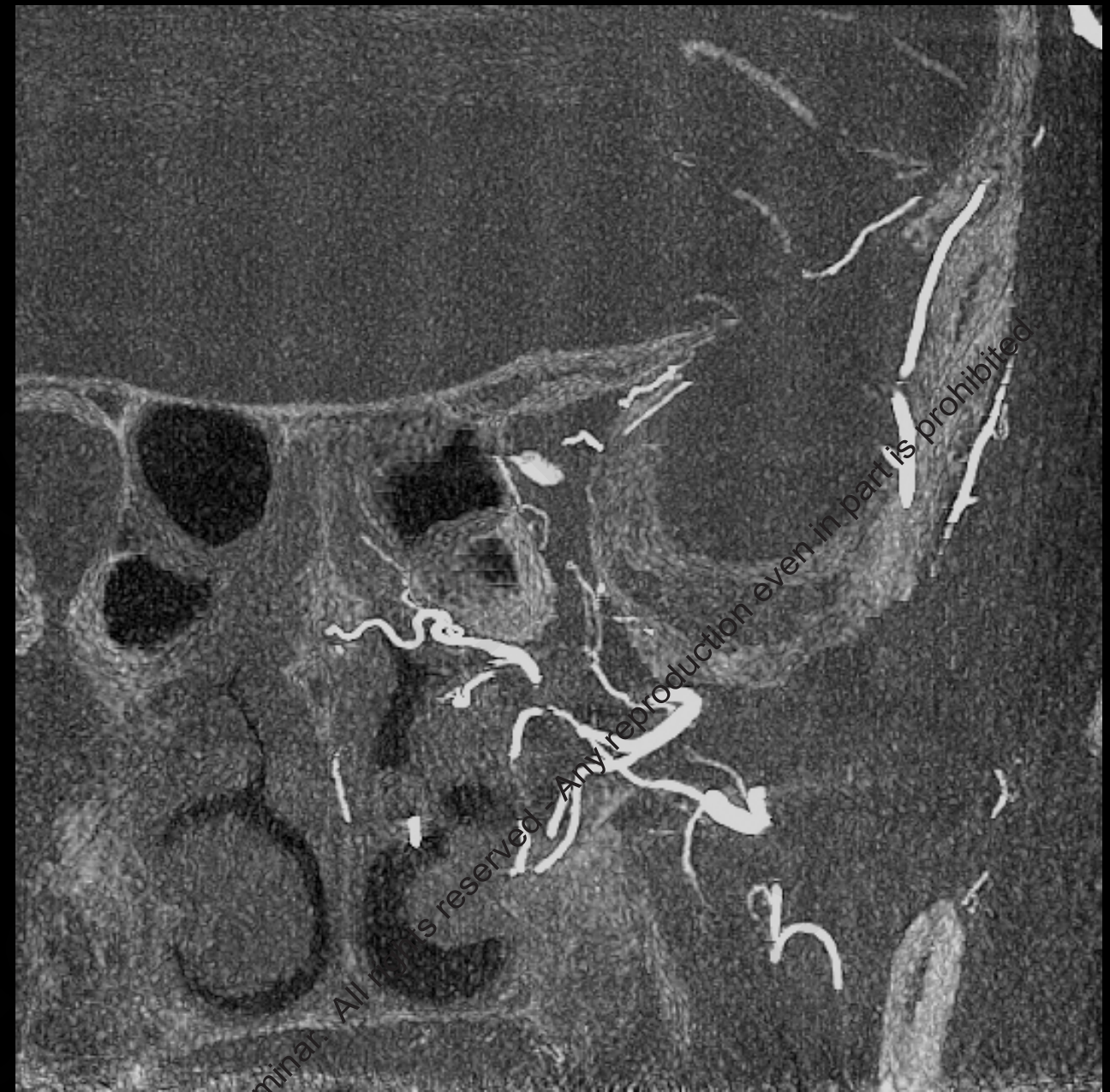

# ant. & post. ethmoidal a. – sphenopalatine a.

Lt.CAG



AP

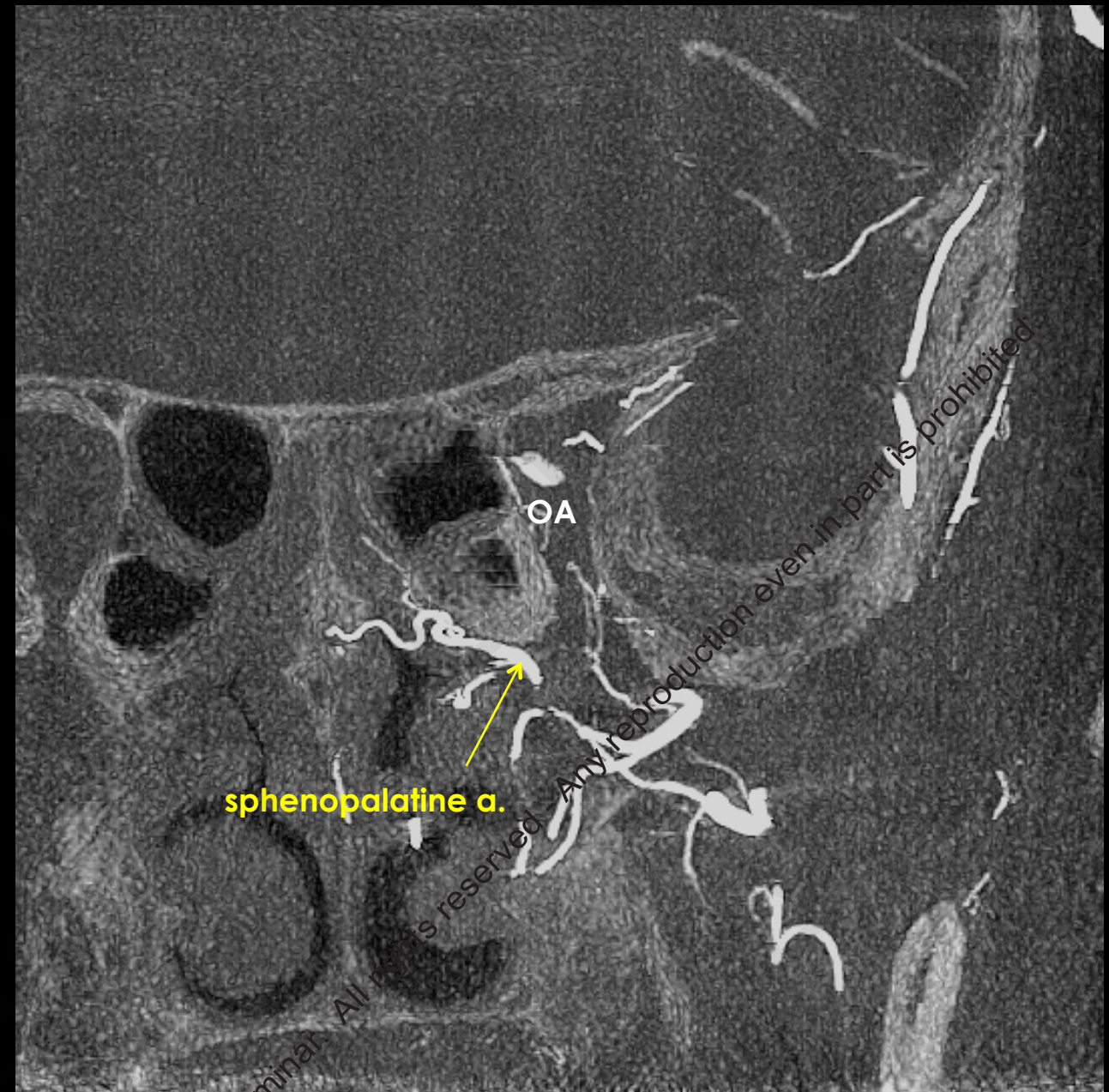
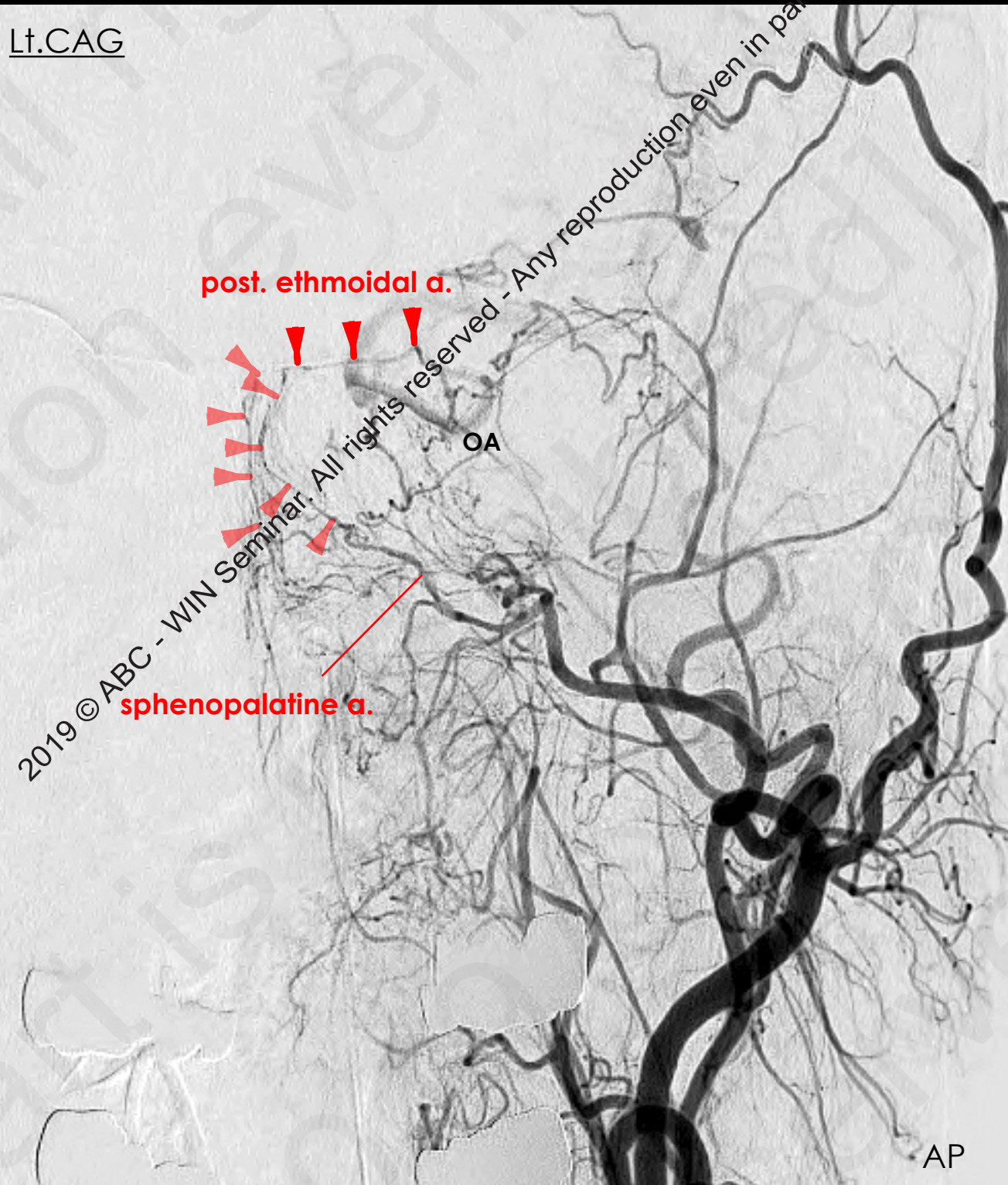


3DRA slab MIP  
coronal



# ant. & post. ethmoidal a. – sphenopalatine a.

Lt.CAG

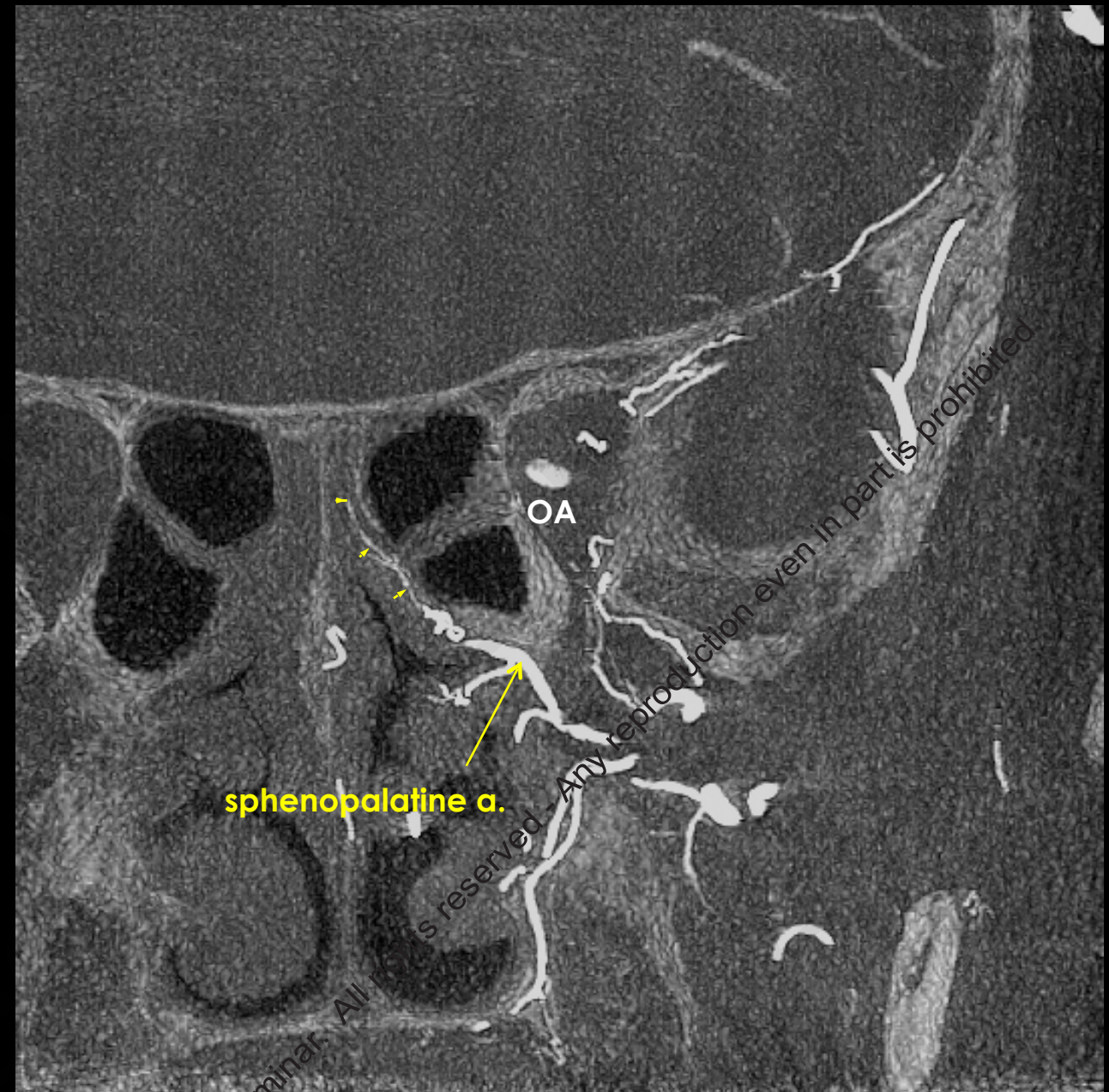
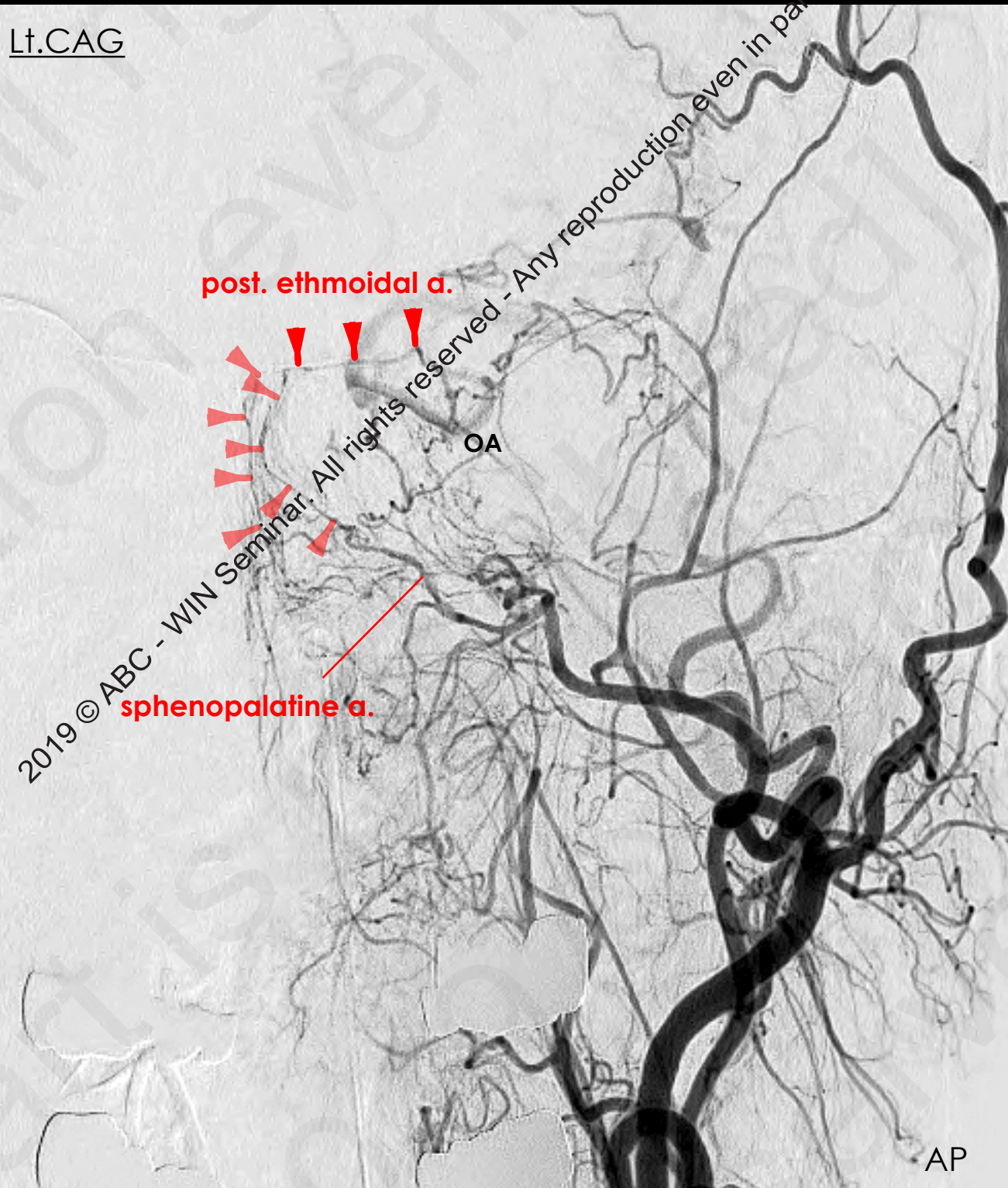


3DRA slab MIP  
coronal



# ant. & post. ethmoidal a. – sphenopalatine a.

Lt.CAG



3DRA slab MIP  
coronal



# ant. & post. ethmoidal a. – sphenopalatine a.

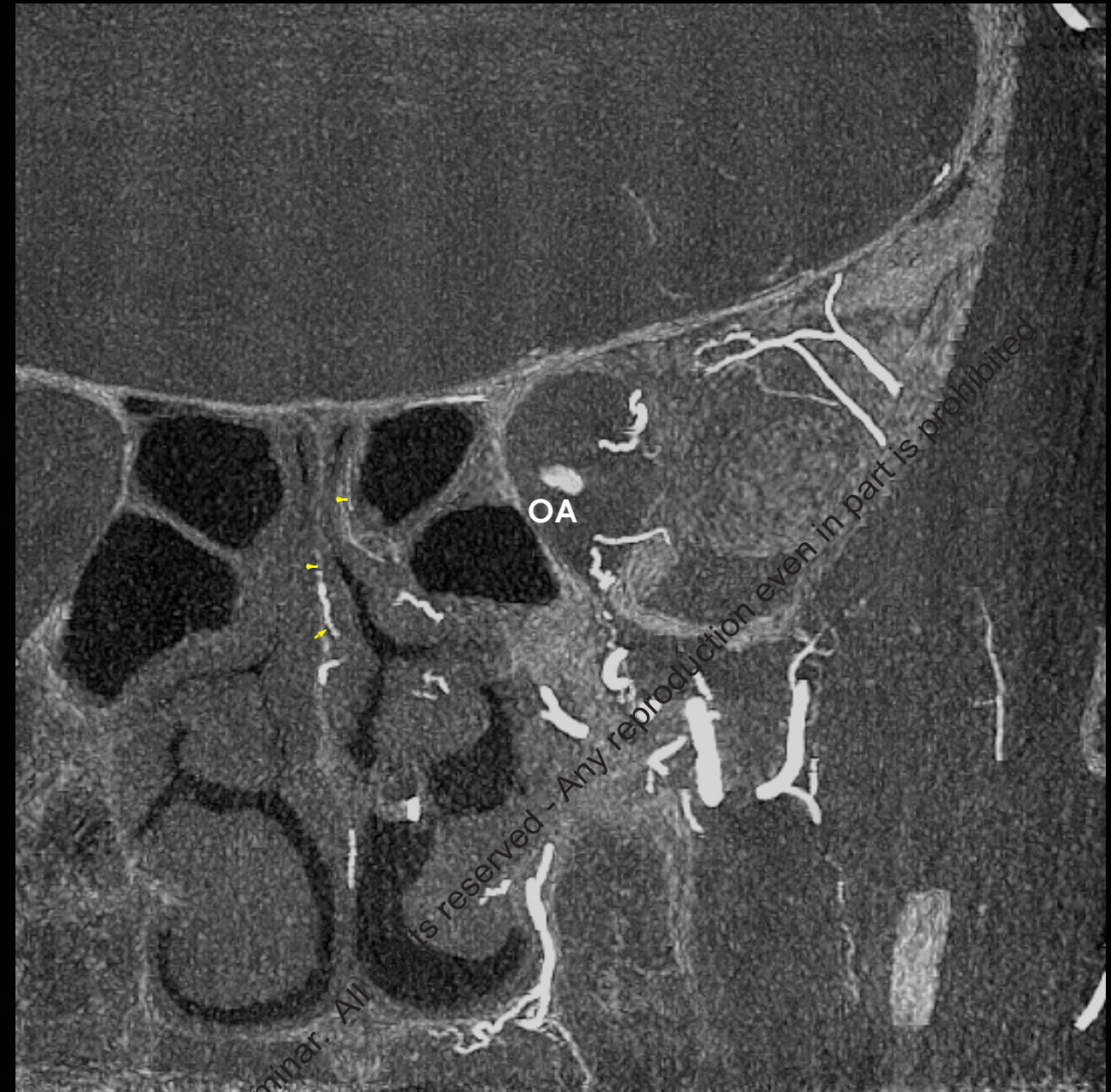Lt.CAG

post. ethmoidal a.

OA

sphenopalatine a.

AP

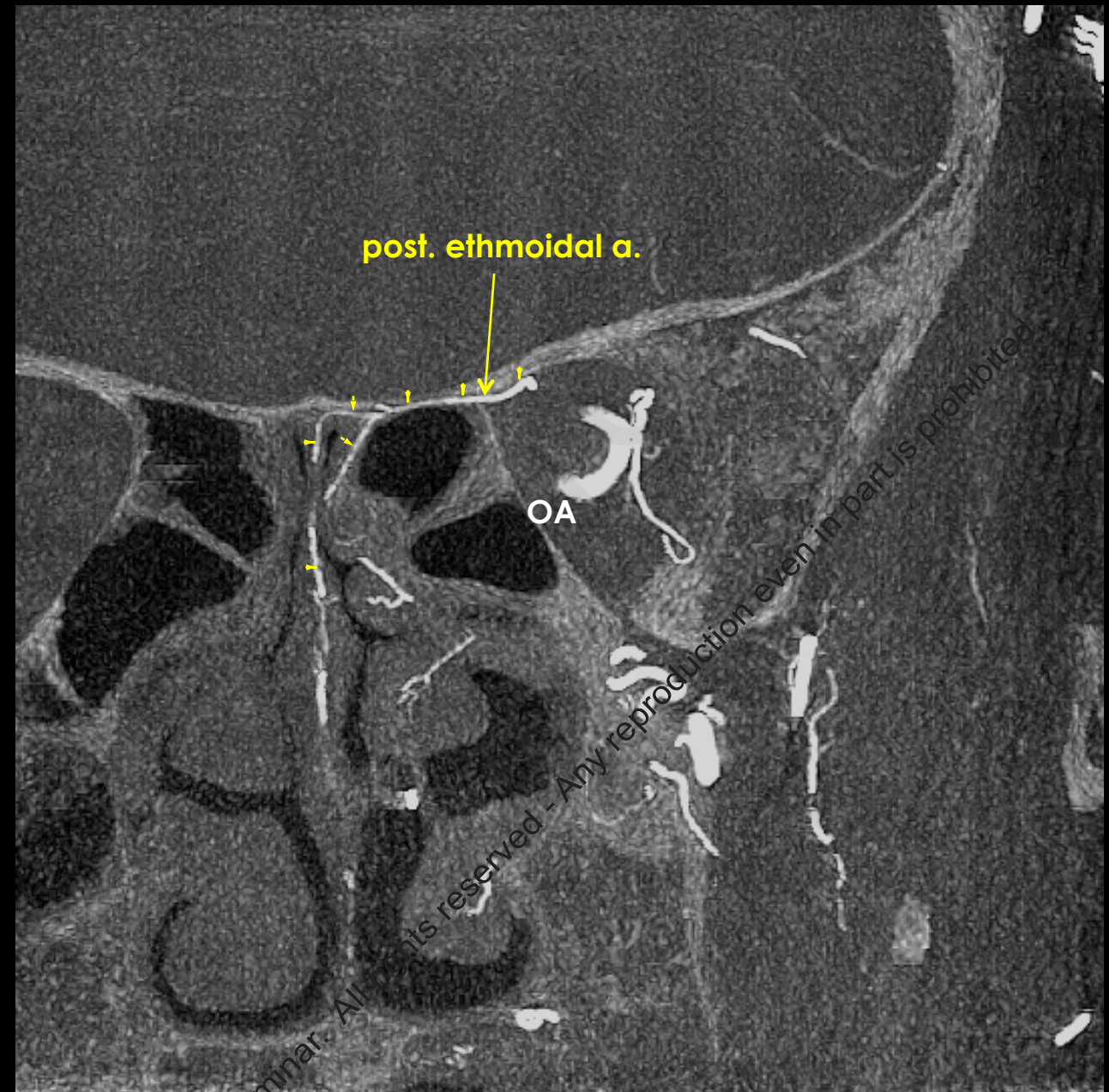
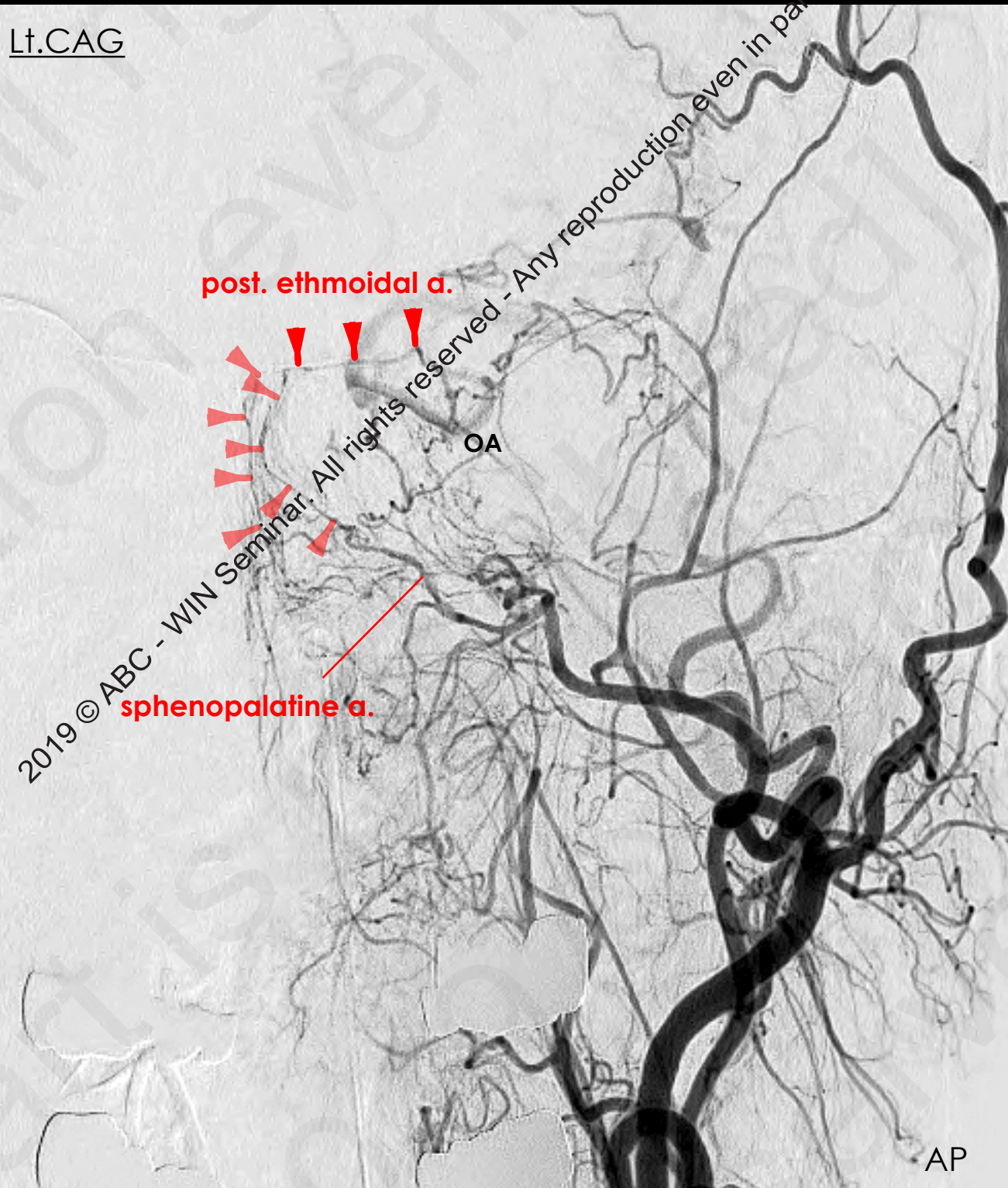


3DRA slab MIP  
coronal



# ant. & post. ethmoidal a. – sphenopalatine a.

Lt.CAG



3DRA slab MIP  
coronal



**ethmoid sinus**

anterior ethmoidal a.      posterior ethmoidal a.

supraorbital a.  
medial frontal a.  
dorsal nasal a.

**SOF (lateral)**

middle meningeal a. (anterior br.)  
recurrent meningeal a.

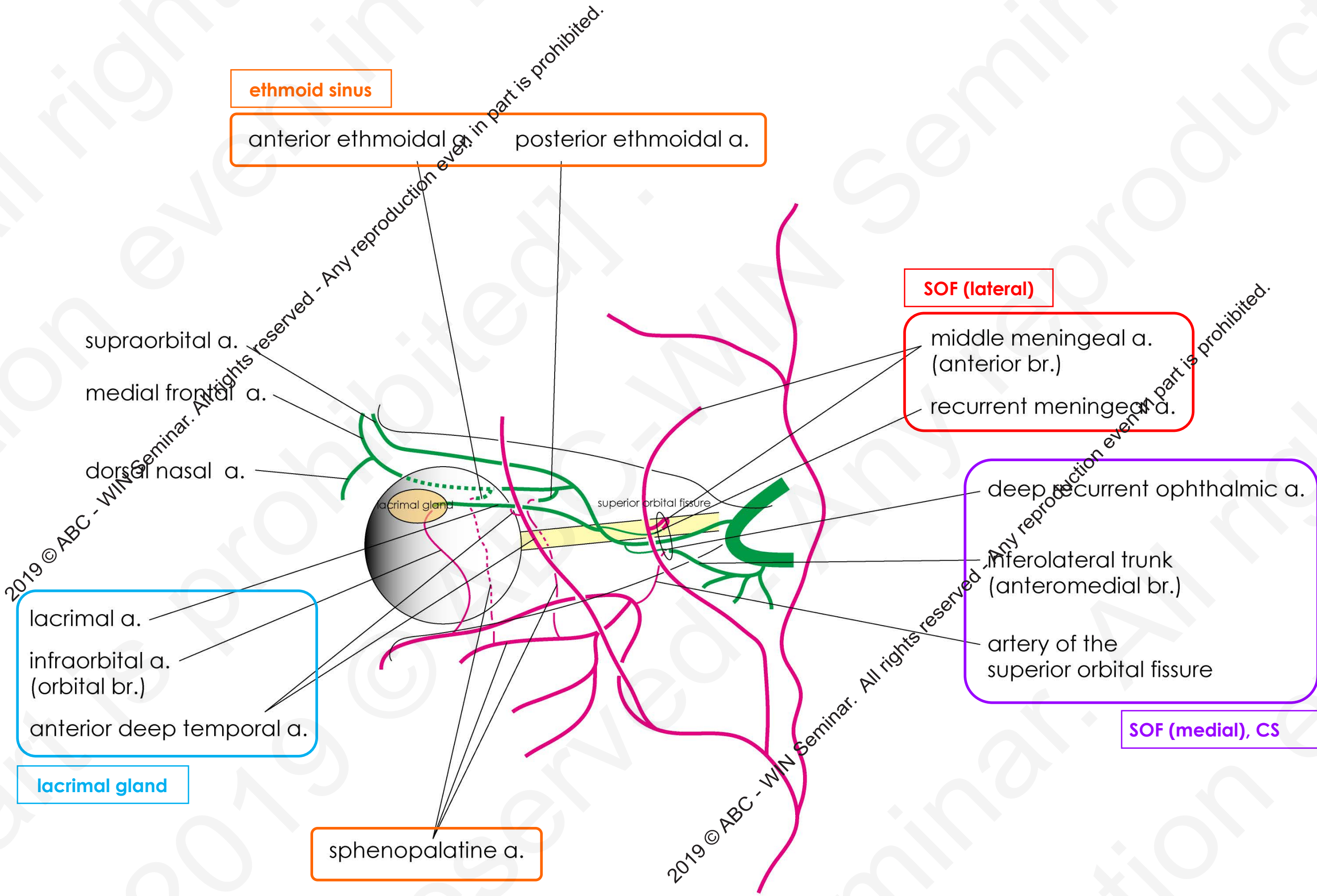
deep recurrent ophthalmic a.  
inferolateral trunk (anteromedial br.)  
artery of the superior orbital fissure

lacrimal a.  
infraorbital a. (orbital br.)  
anterior deep temporal a.

**lacrimal gland**

sphenopalatine a.

**SOF (medial), CS**



2019 © ABC - WIN Seminar. All rights reserved - Any reproduction even in part is prohibited.

2019 © ABC - WIN Seminar. All rights reserved - Any reproduction even in part is prohibited.

**ethmoid sinus**

anterior ethmoidal a.      posterior ethmoidal a.

**peripalpebral**

superficial temporal a.  
(frontal br.)

supraorbital a.

medial frontal a.

dorsal nasal a.

infraorbital a.

lacrimal a.

infraorbital a.  
(orbital br.)

anterior deep temporal a.

**lacrimal gland**

sphenopalatine a.

**SOF (lateral)**

middle meningeal a.  
(anterior br.)

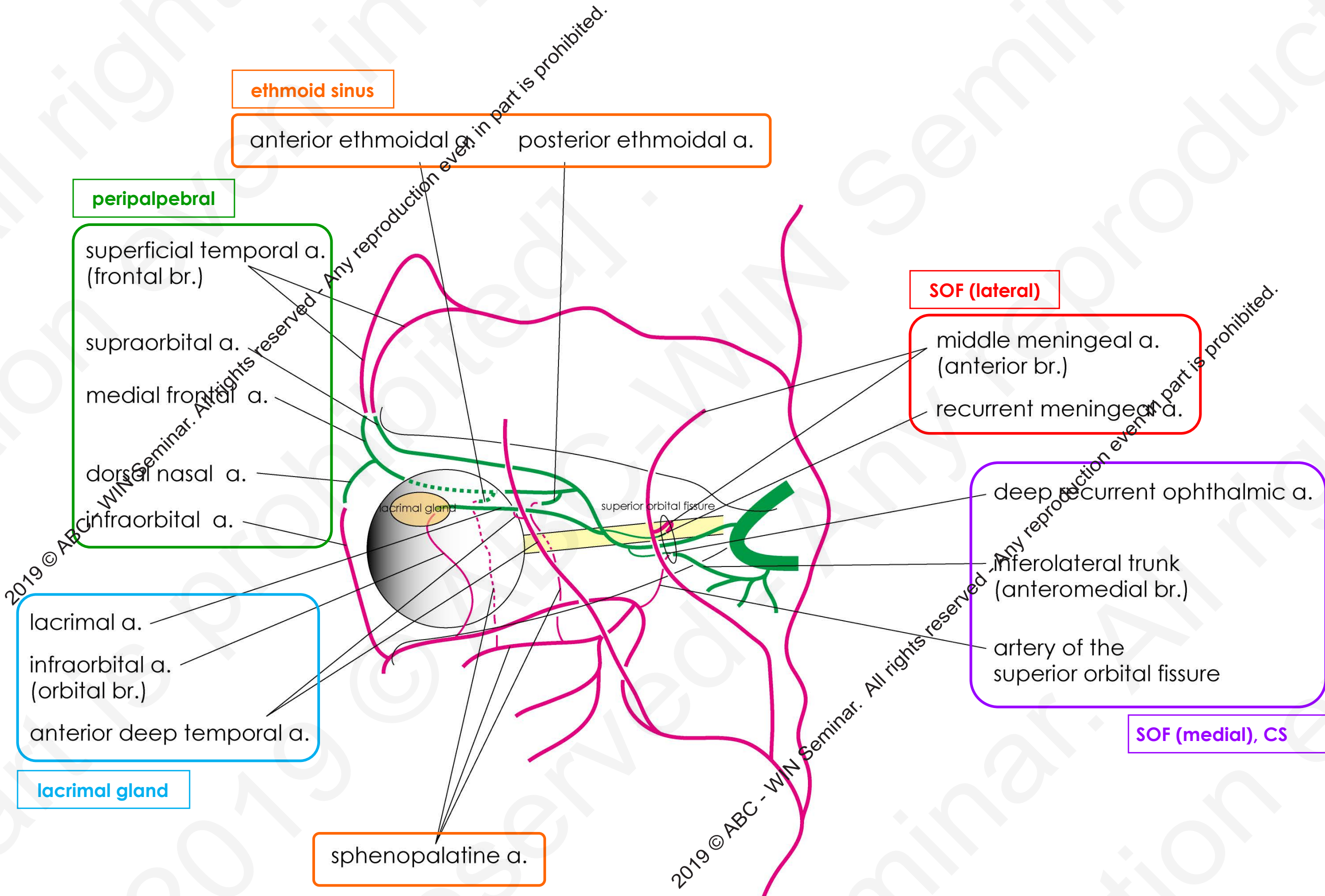
recurrent meningeal a.

deep recurrent ophthalmic a.

inferolateral trunk  
(anteromedial br.)

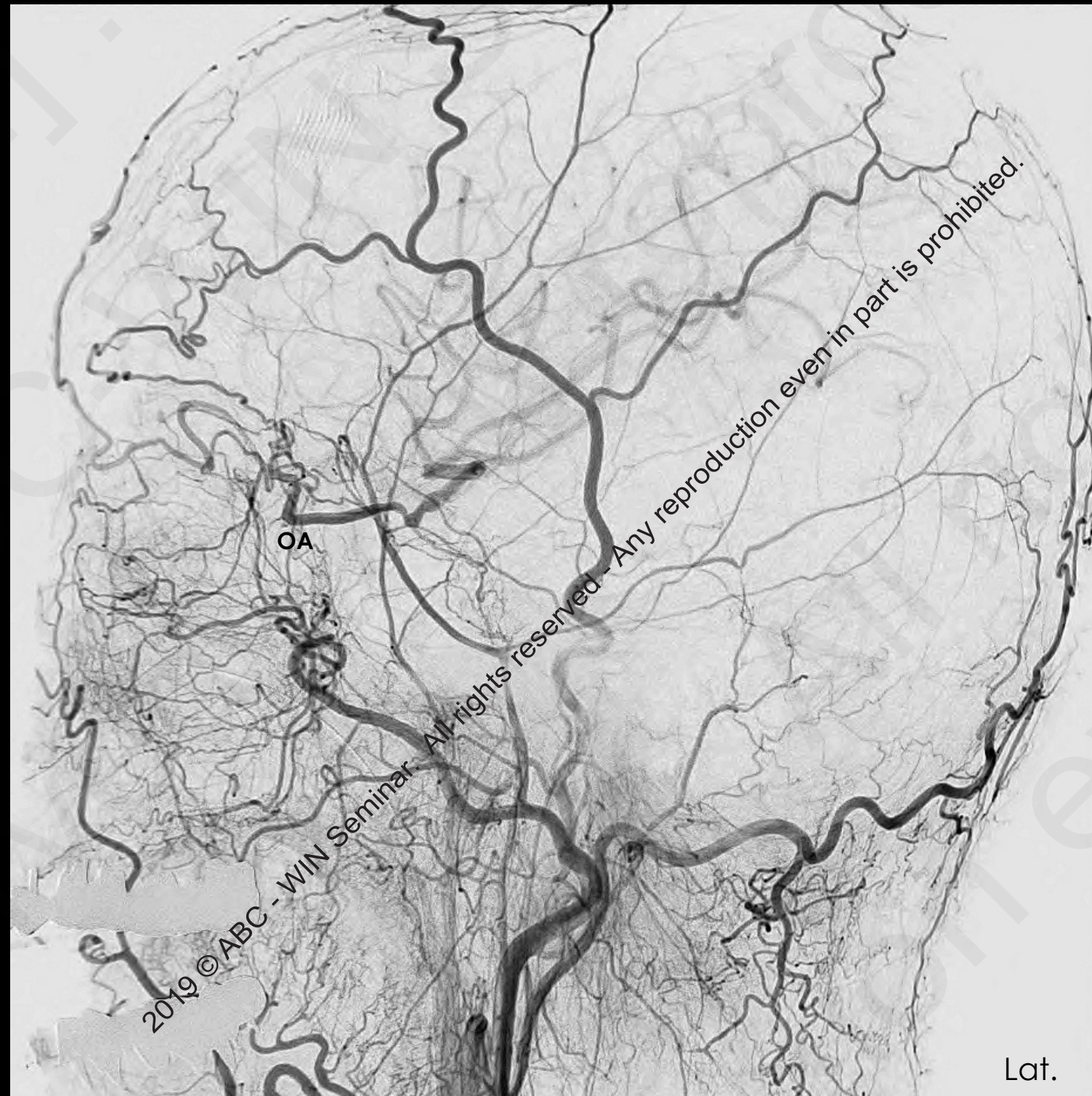
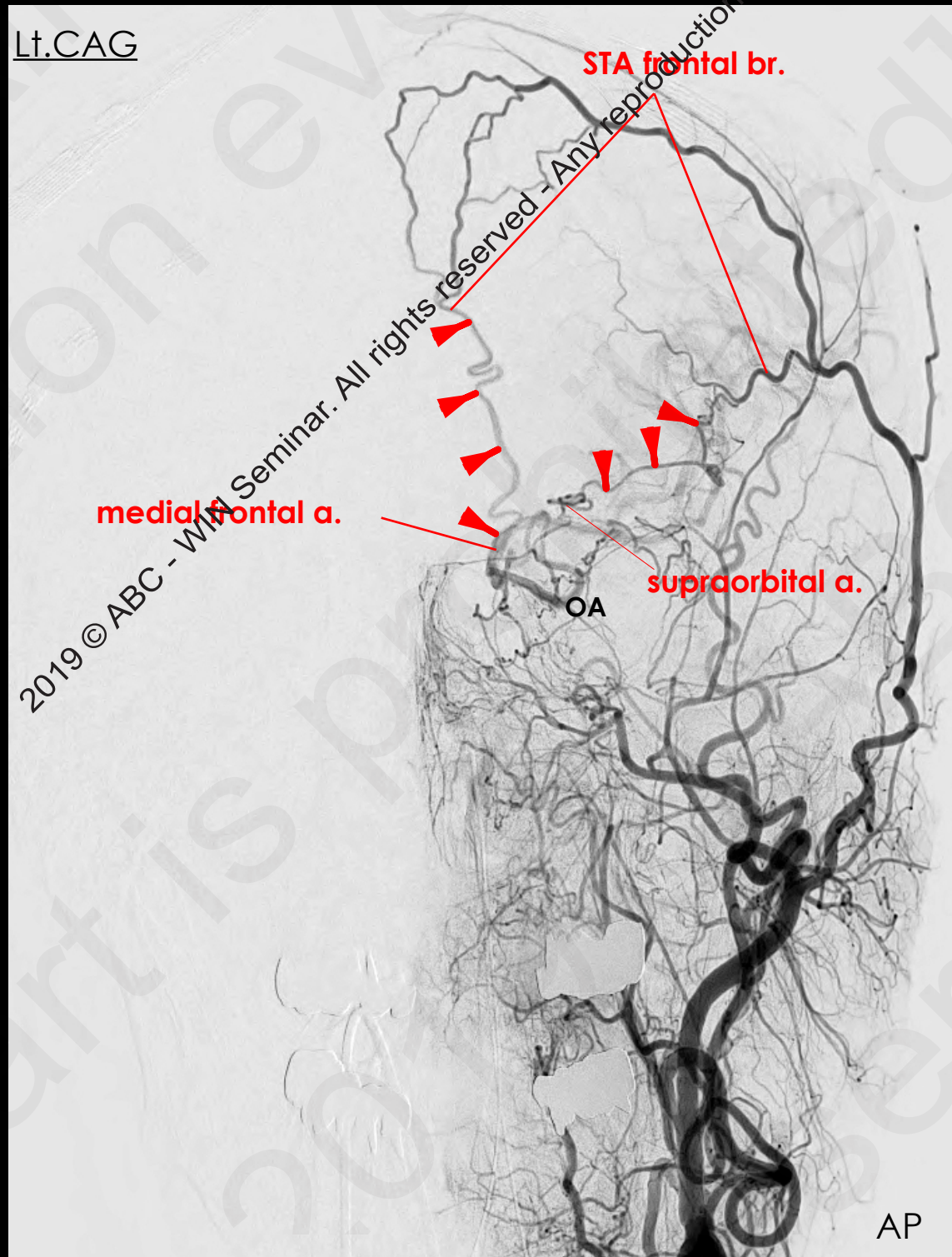
artery of the  
superior orbital fissure

**SOF (medial), CS**



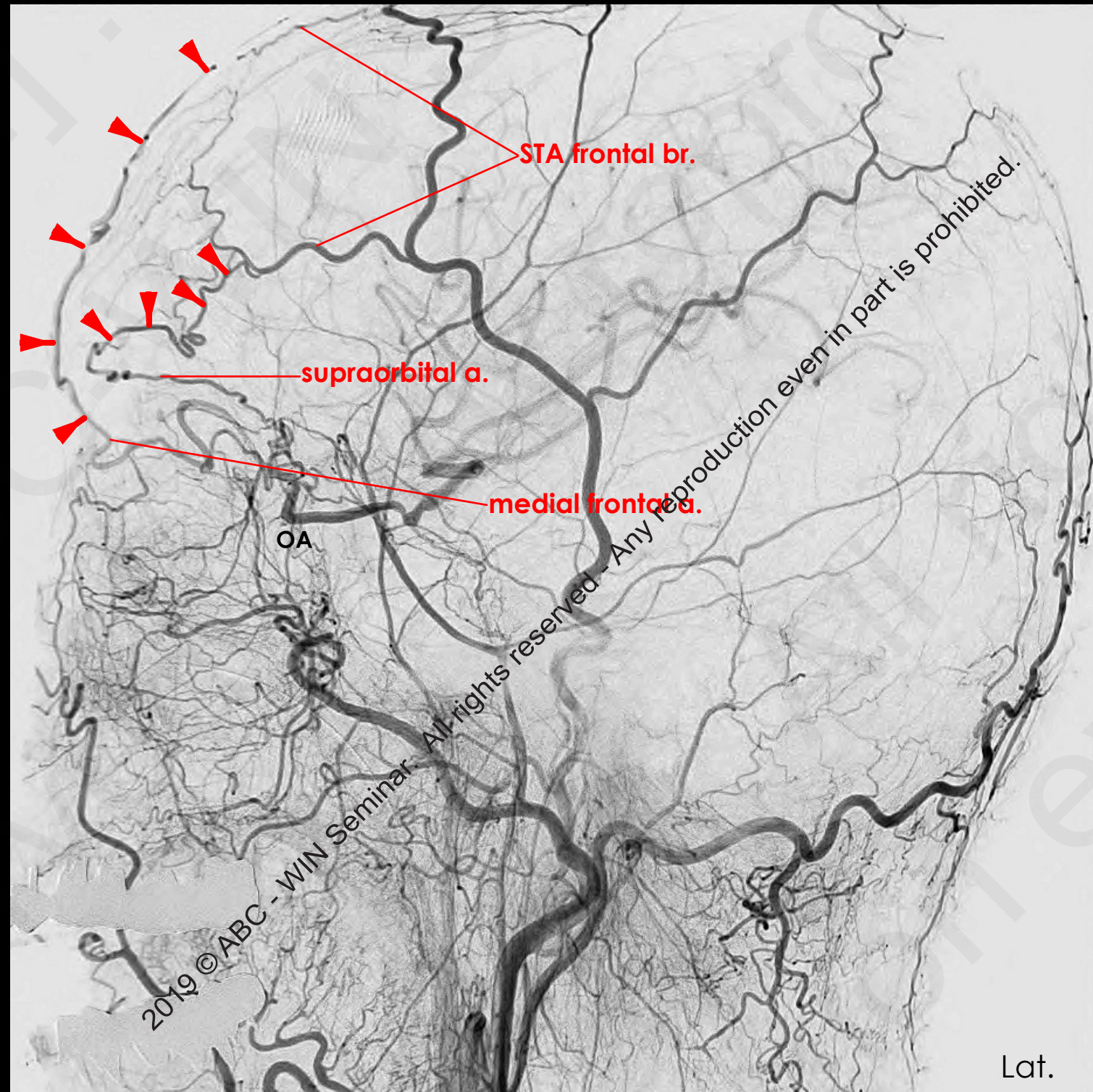
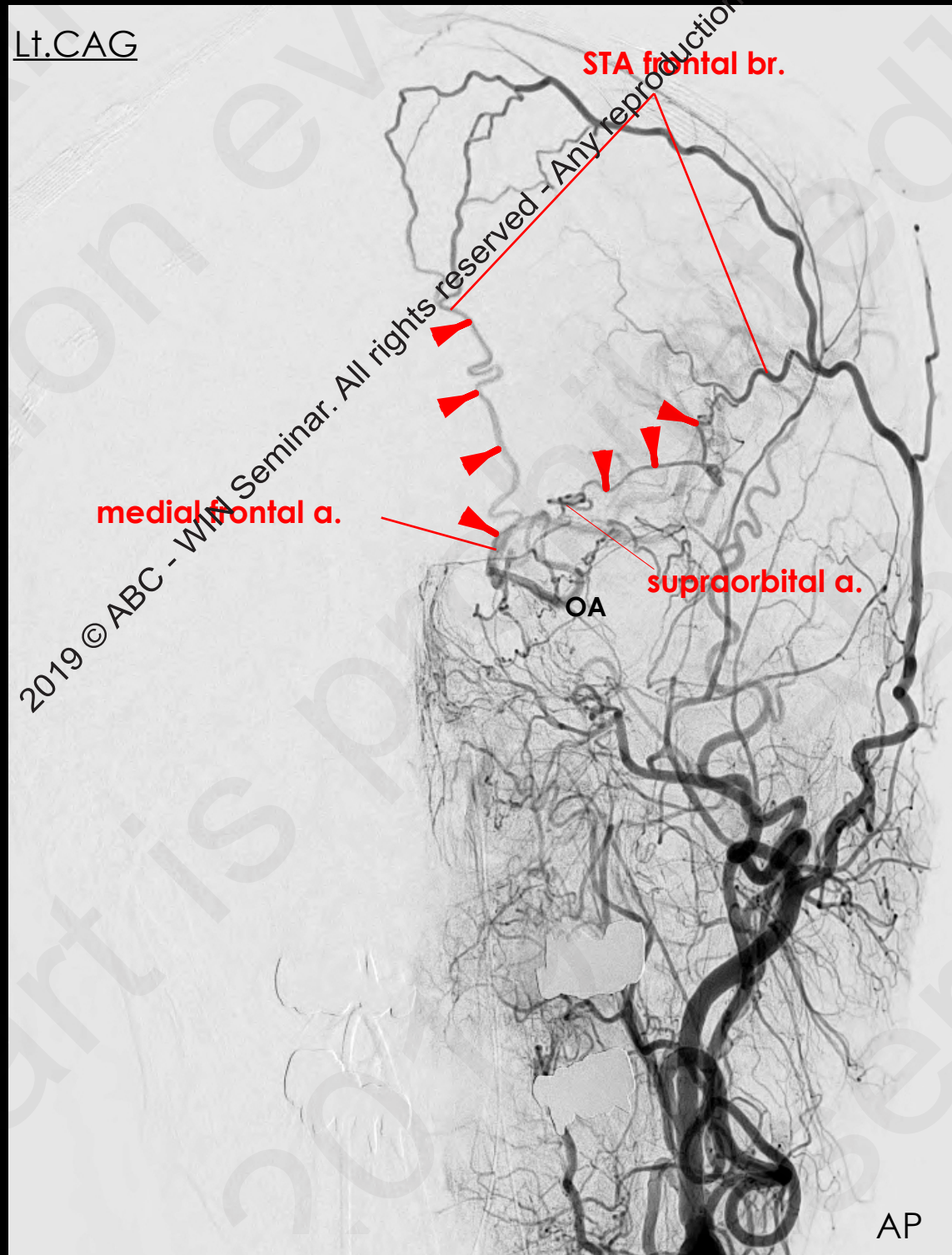


supraorbital a. – STA frontal br.  
medial frontal a. – STA frontal br.



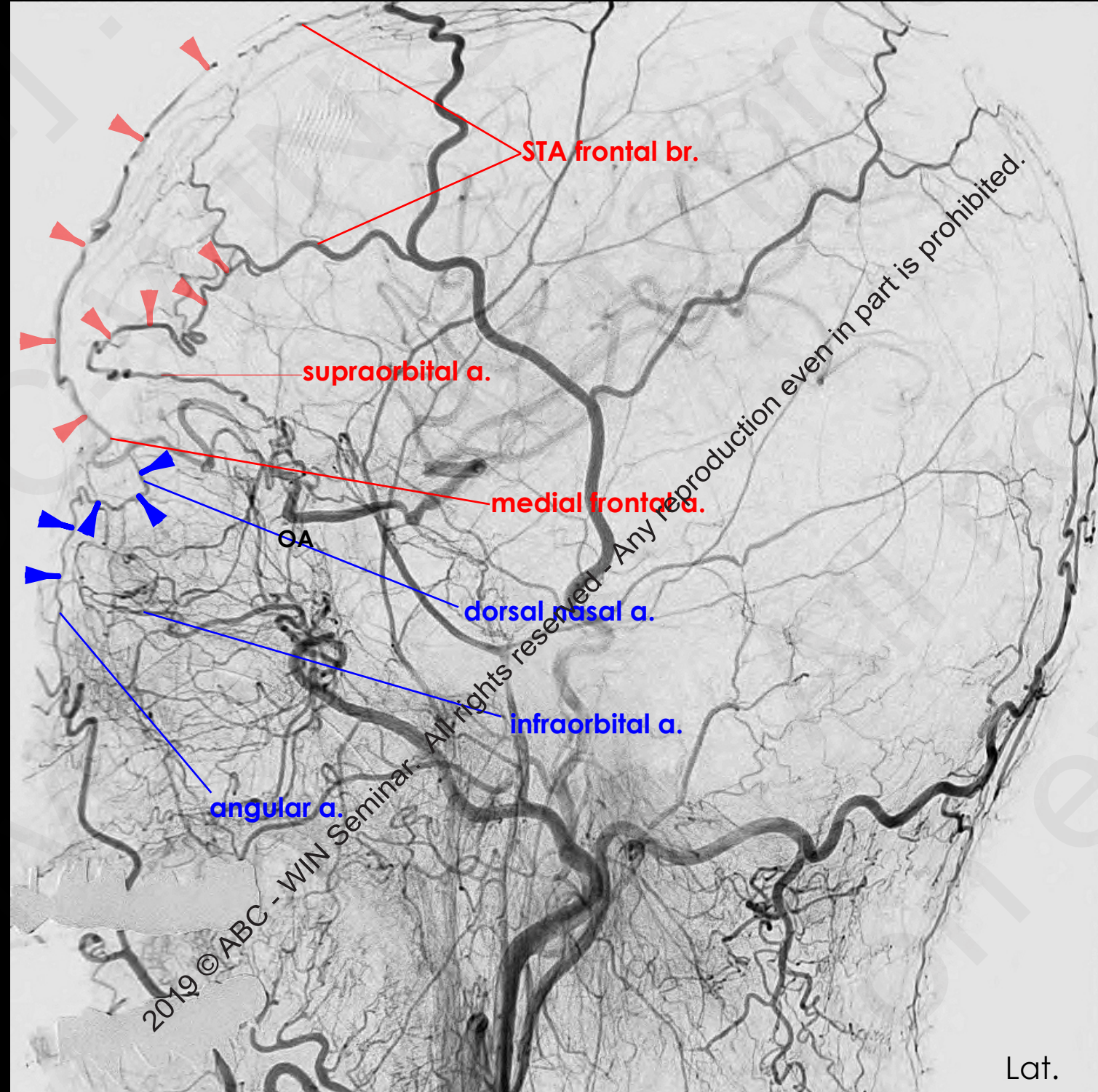
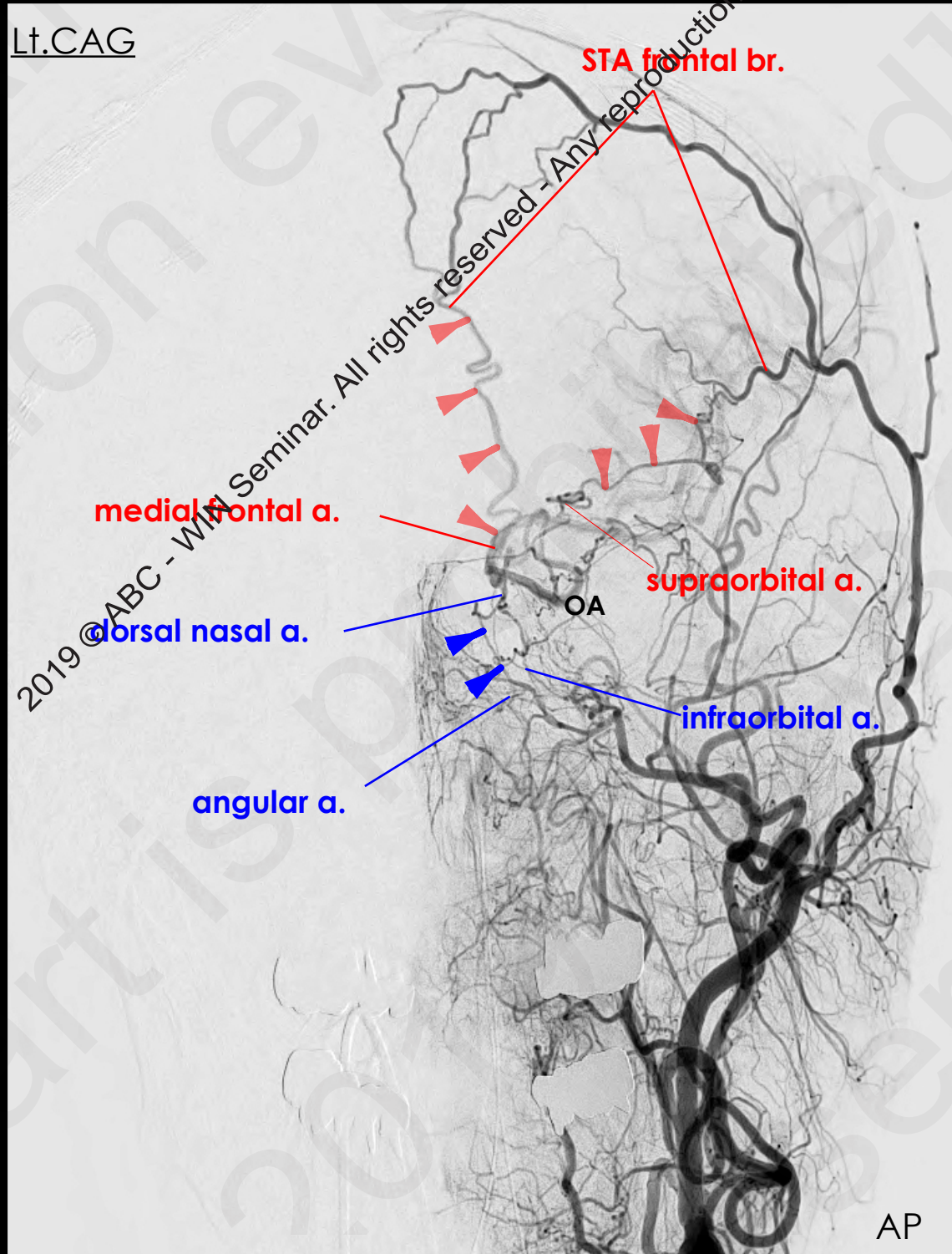


supraorbital a. – STA frontal br.  
medial frontal a. – STA frontal br.



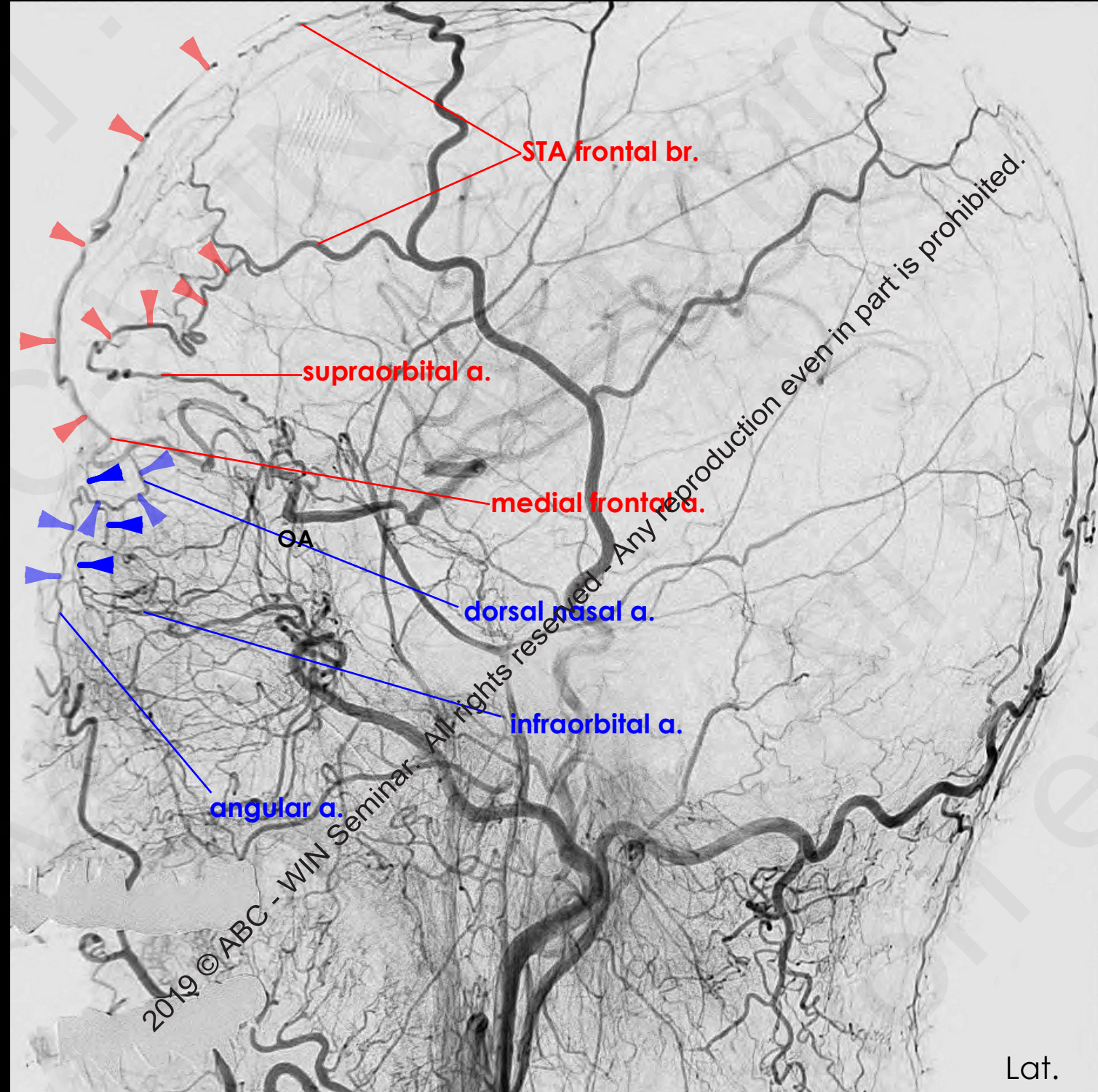
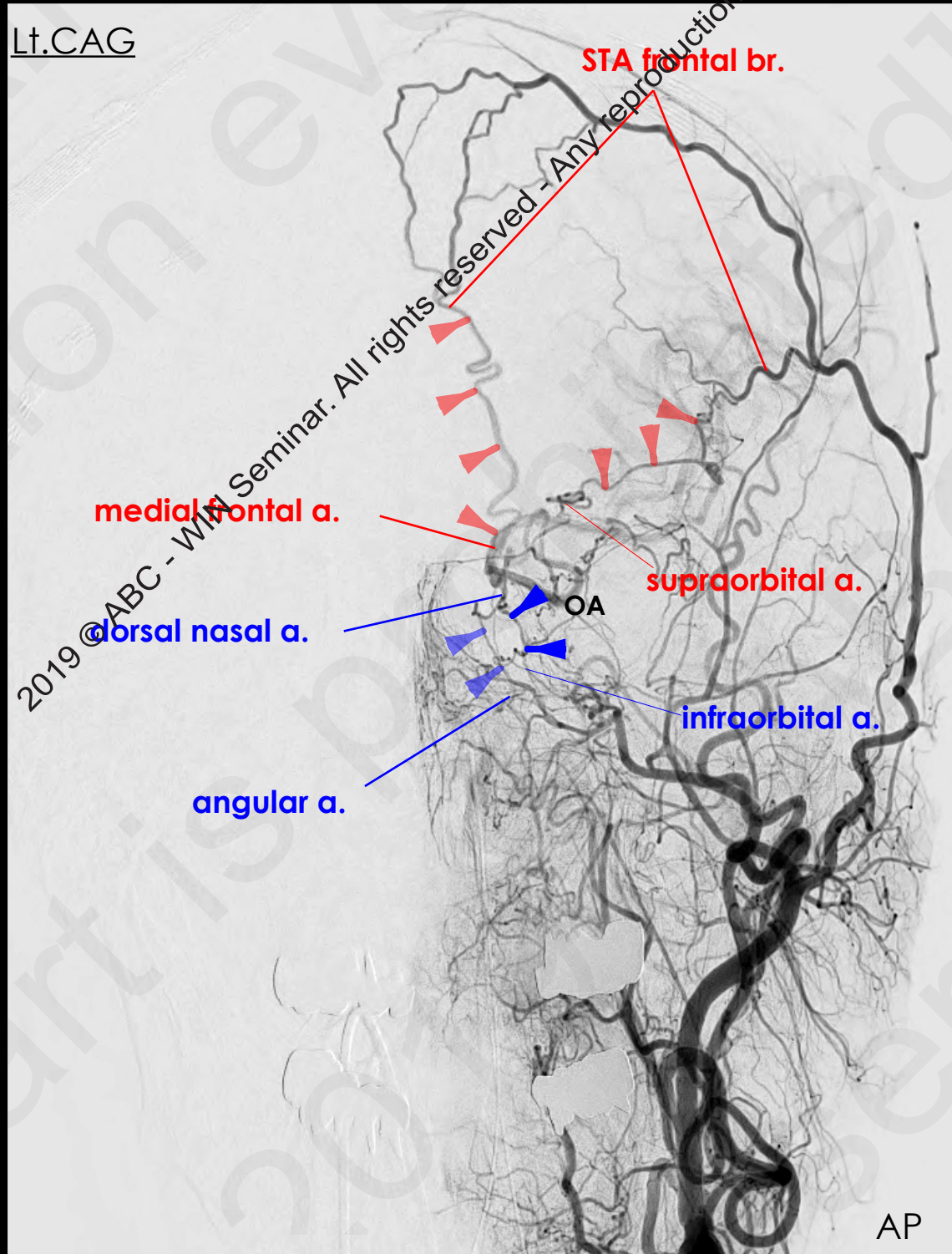


supraorbital a. – STA frontal br.  
 medial frontal a. – STA frontal br.  
 dorsal nasal a. – angular a., infraorbital a.

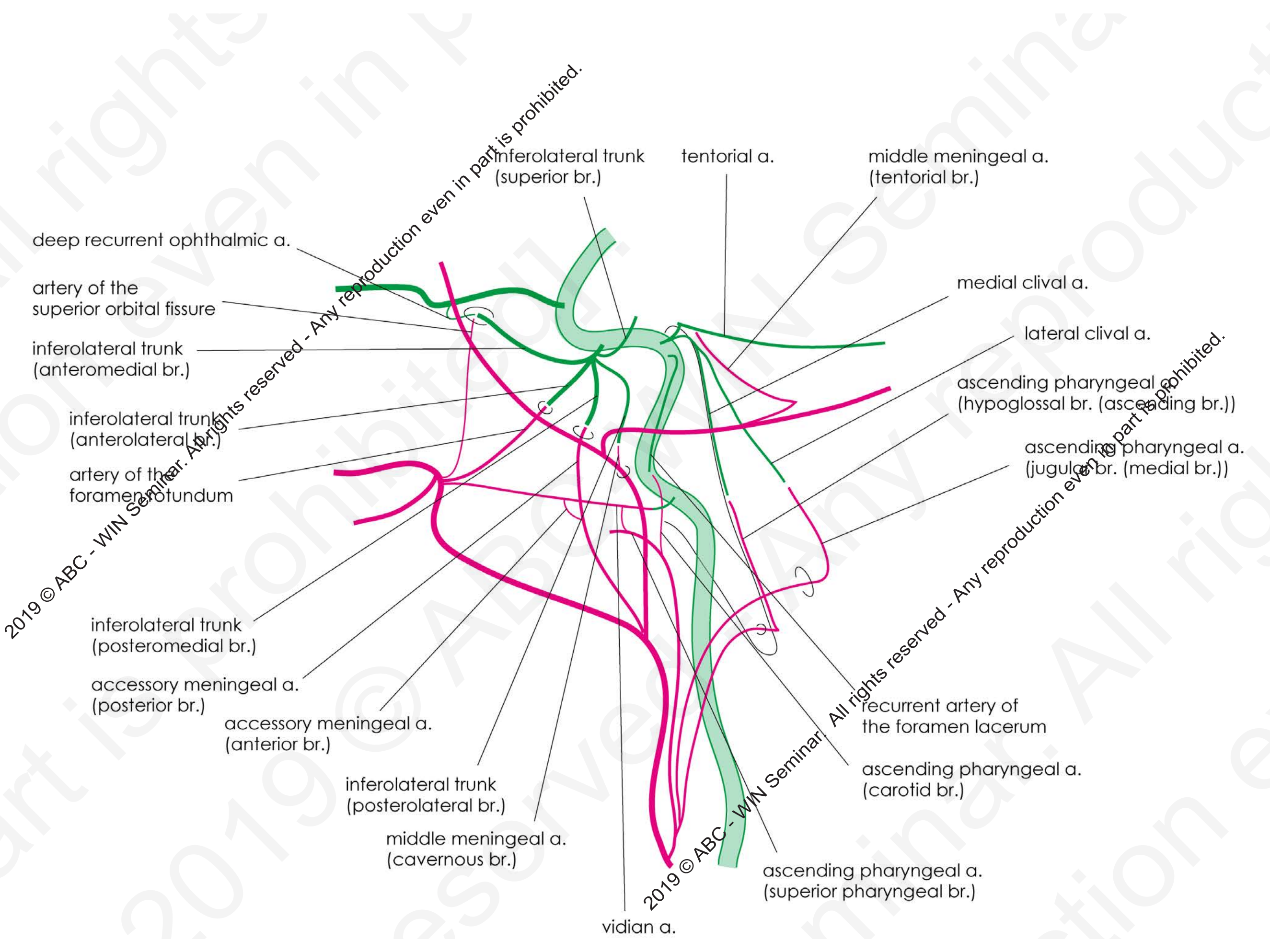




supraorbital a. – STA frontal br.  
 medial frontal a. – STA frontal br.  
 dorsal nasal a. – angular a., infraorbital a.







deep recurrent ophthalmic a.

artery of the superior orbital fissure

inferolateral trunk (anteromedial br.)

inferolateral trunk (anterolateral br.)

artery of the foramen rotundum

inferolateral trunk (posteromedial br.)

accessory meningeal a. (posterior br.)

accessory meningeal a. (anterior br.)

inferolateral trunk (posterolateral br.)

middle meningeal a. (cavernous br.)

vidian a.

inferolateral trunk (superior br.)

tentorial a.

middle meningeal a. (tentorial br.)

medial clival a.

lateral clival a.

ascending pharyngeal a. (hypoglossal br. (ascending br.))

ascending pharyngeal a. (jugular br. (medial br.))

recurrent artery of the foramen lacerum

ascending pharyngeal a. (carotid br.)

ascending pharyngeal a. (superior pharyngeal br.)

2019 © ABC - WIN Seminar. All rights reserved - Any reproduction even in part is prohibited.

2019 © ABC - WIN Seminar. All rights reserved - Any reproduction even in part is prohibited.

2019 © ABC - WIN Seminar. All rights reserved - Any reproduction even in part is prohibited.

deep recurrent ophthalmic a.

inferolateral trunk  
(anteromedial br.)

inferolateral trunk  
(anterolateral br.)

inferolateral trunk  
(posteromedial br.)

inferolateral trunk  
(posterolateral br.)

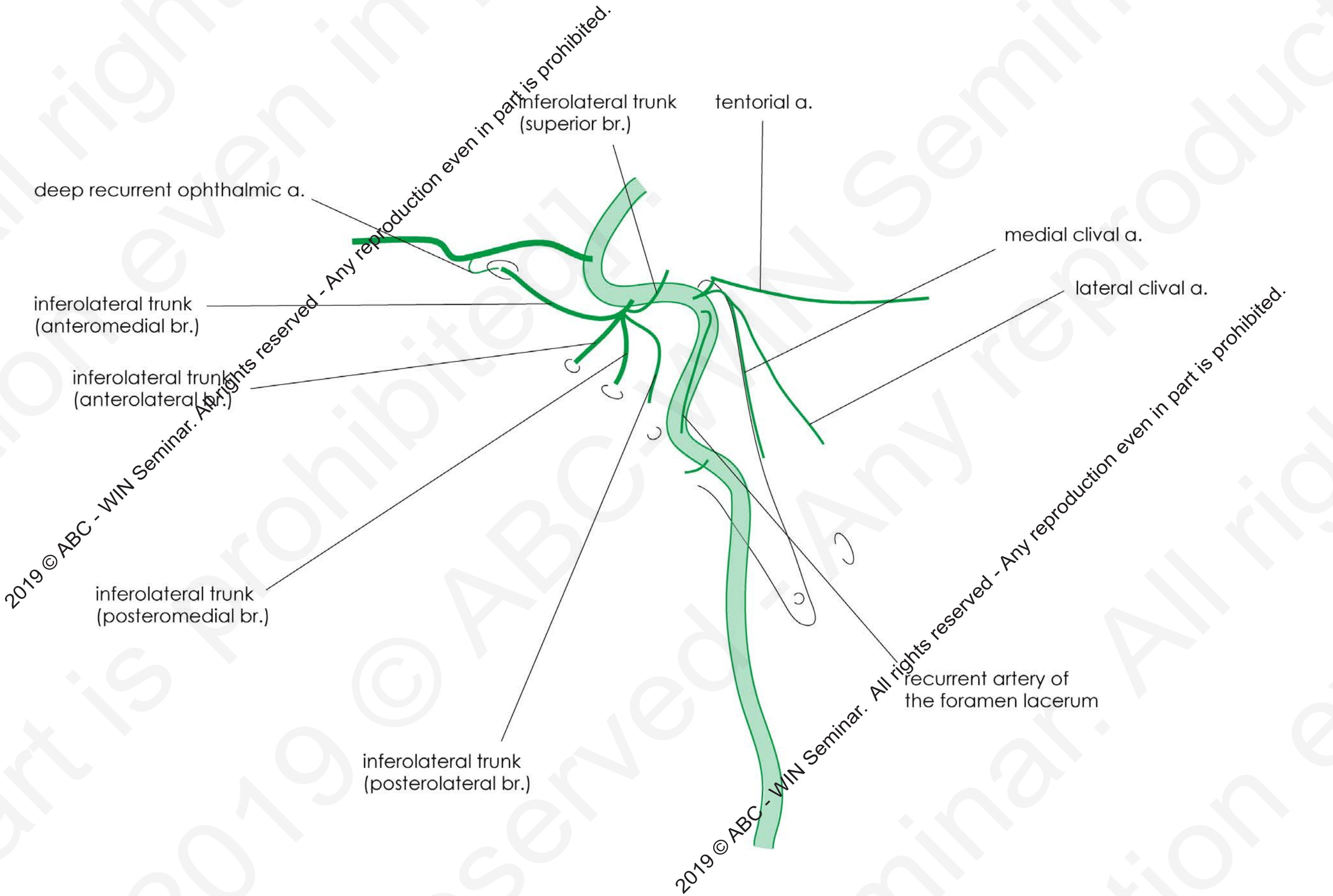
inferolateral trunk  
(superior br.)

tentorial a.

medial clival a.

lateral clival a.

recurrent artery of  
the foramen lacerum





deep recurrent ophthalmic a.

inferolateral trunk  
(anteromedial br.)

inferolateral trunk  
(anterolateral br.)

inferolateral trunk  
(posteromedial br.)

inferolateral trunk  
(posterolateral br.)

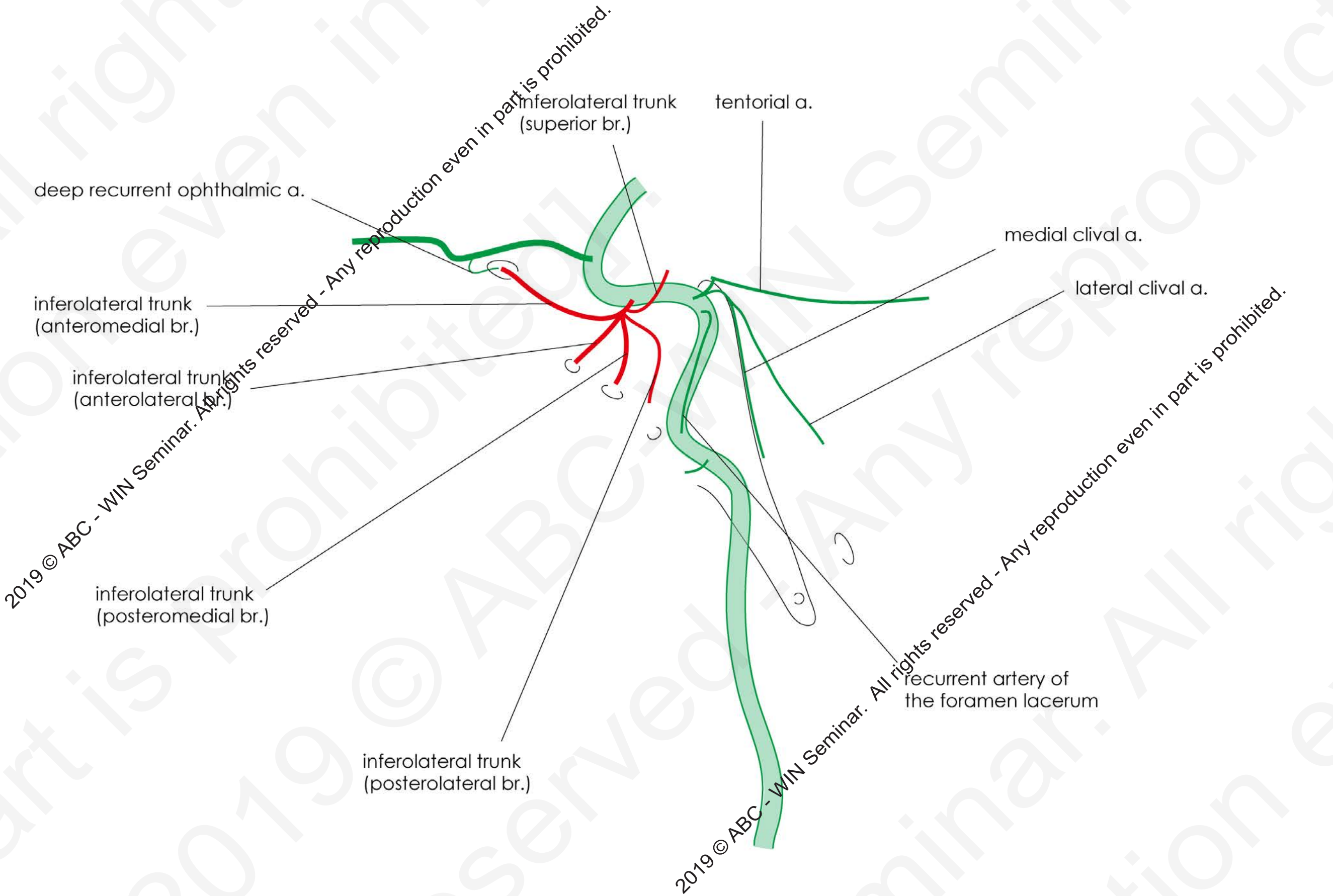
inferolateral trunk  
(superior br.)

tentorial a.

medial clival a.

lateral clival a.

recurrent artery of  
the foramen lacerum

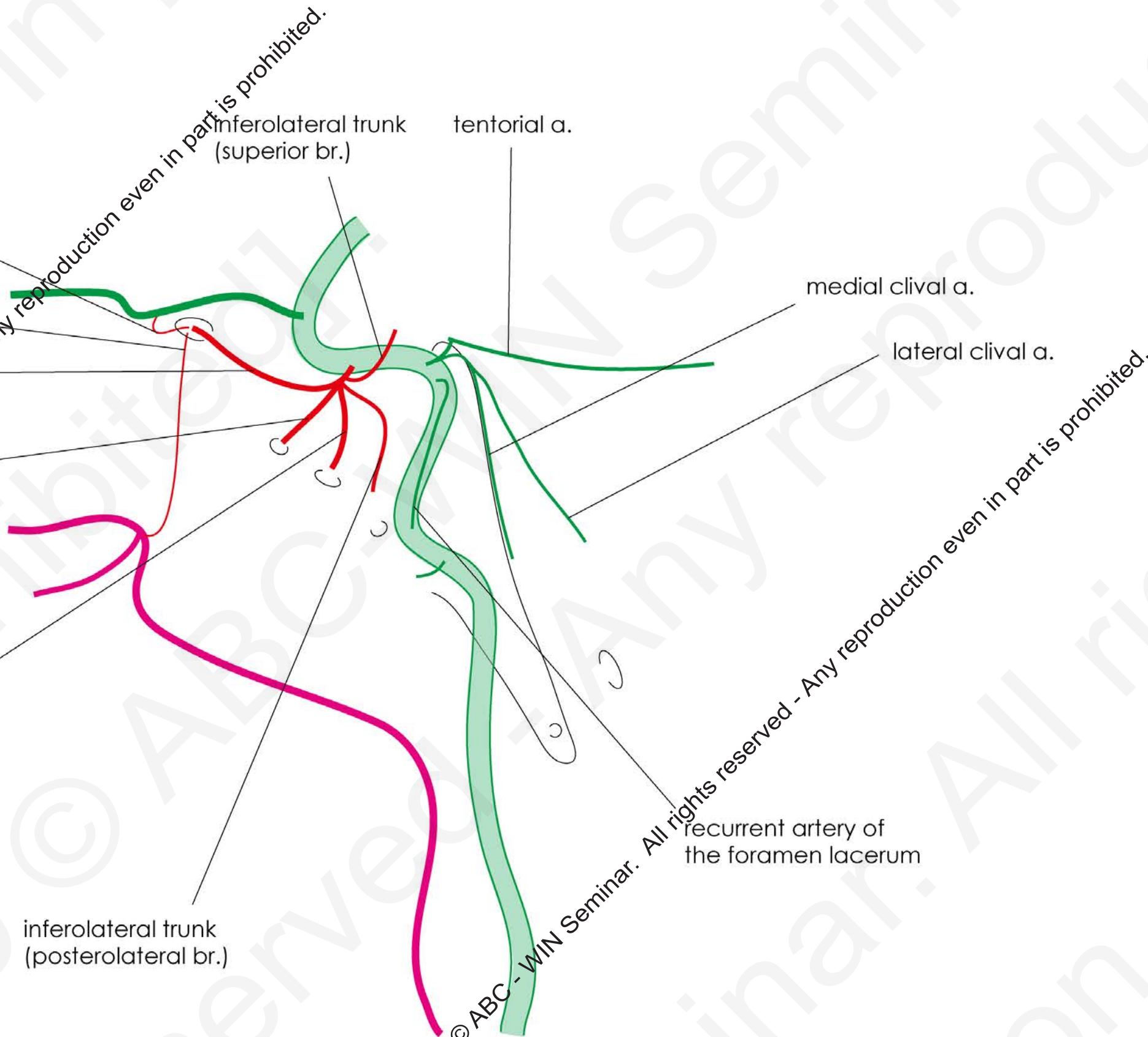


2019 © ABC - WIN Seminar. All rights reserved - Any reproduction even in part is prohibited.

2019 © ABC - WIN Seminar. All rights reserved - Any reproduction even in part is prohibited.

2019 © ABC - WIN Seminar. All rights reserved - Any reproduction even in part is prohibited.

deep recurrent ophthalmic a.  
artery of the superior orbital fissure  
inferolateral trunk (anteromedial br.)



inferolateral trunk (anterolateral br.)  
inferolateral trunk (posteromedial br.)  
inferolateral trunk (posterolateral br.)

tentorial a.  
medial clival a.  
lateral clival a.  
recurrent artery of the foramen lacerum

2019 © ABC - WIN Seminar. All rights reserved - Any reproduction even in part is prohibited.



deep recurrent ophthalmic a.  
artery of the superior orbital fissure  
inferolateral trunk (anteromedial br.)

inferolateral trunk (anterolateral br.)  
artery of the foramen rotundum

inferolateral trunk (posteromedial br.)

inferolateral trunk (posterolateral br.)

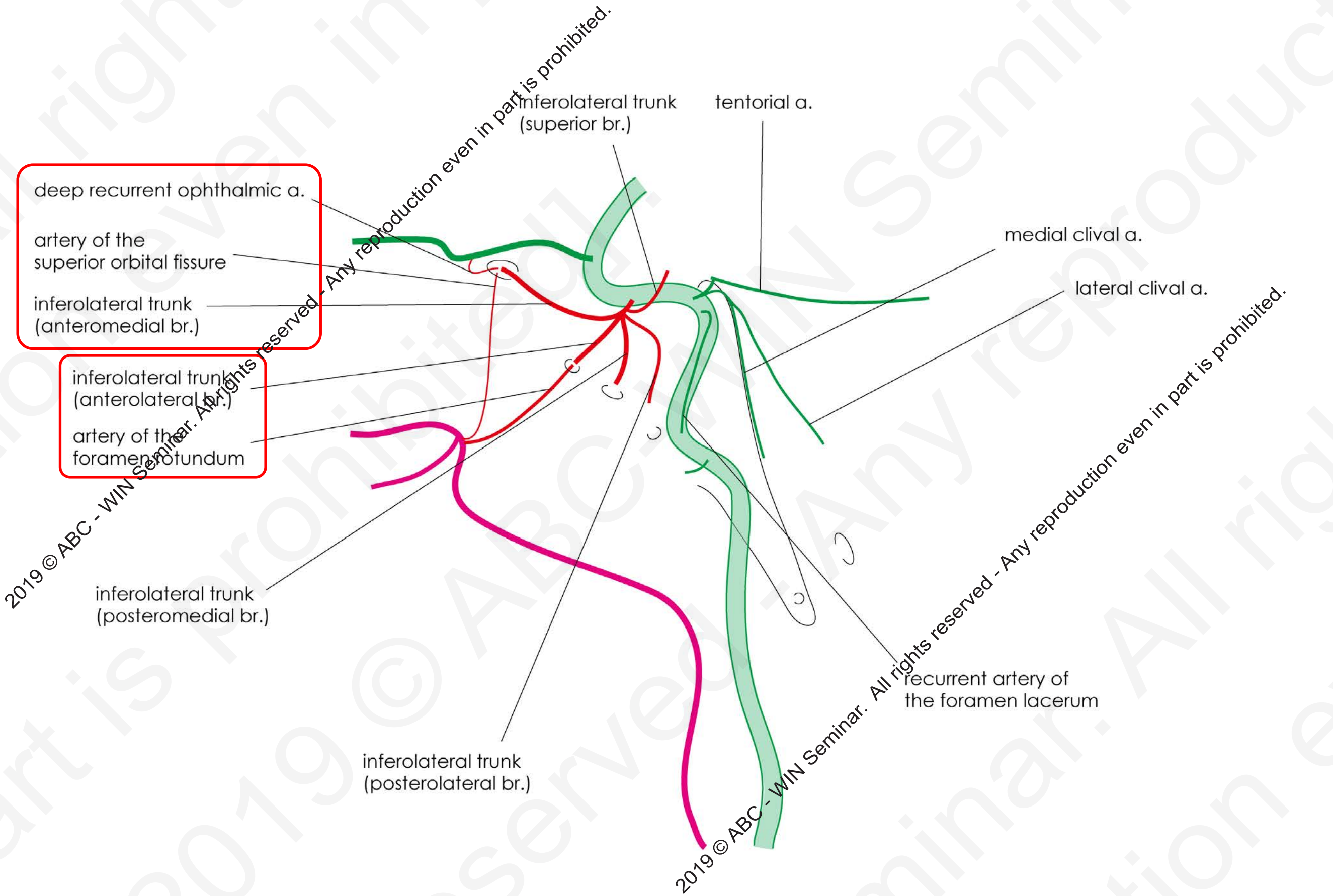
inferolateral trunk (superior br.)

tentorial a.

medial clival a.

lateral clival a.

recurrent artery of the foramen lacerum



deep recurrent ophthalmic a.  
artery of the superior orbital fissure  
inferolateral trunk (anteromedial br.)

inferolateral trunk (anterolateral br.)  
artery of the foramen rotundum

inferolateral trunk (posteromedial br.)  
accessory meningeal a. (posterior br.)

inferolateral trunk (posterolateral br.)

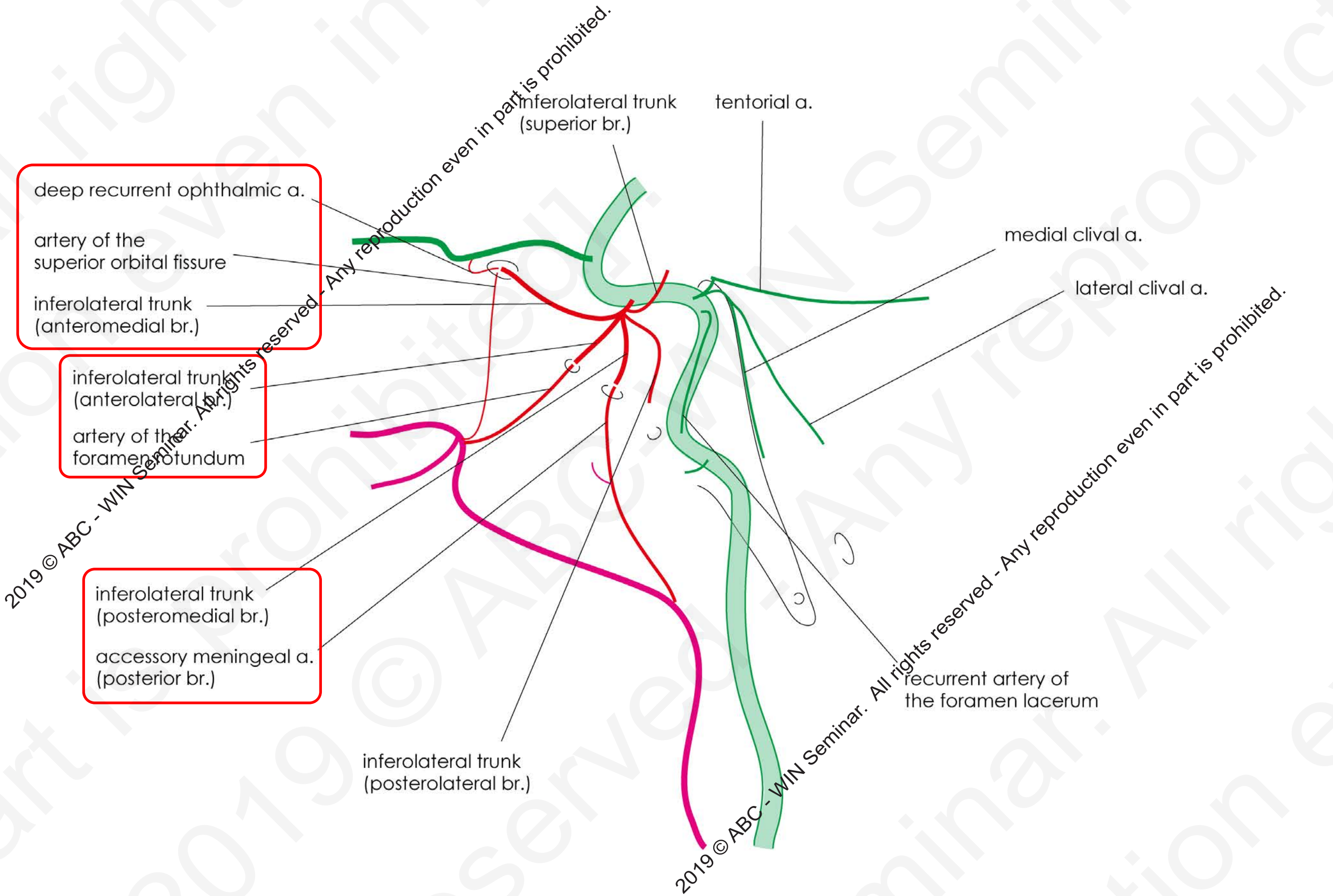
inferolateral trunk (superior br.)

tentorial a.

medial clival a.

lateral clival a.

recurrent artery of the foramen lacerum





deep recurrent ophthalmic a.  
artery of the superior orbital fissure  
inferolateral trunk (anteromedial br.)

inferolateral trunk (anterolateral br.)  
artery of the foramen rotundum

inferolateral trunk (posteromedial br.)  
accessory meningeal a. (posterior br.)

inferolateral trunk (posterolateral br.)  
middle meningeal a. (cavernous br.)

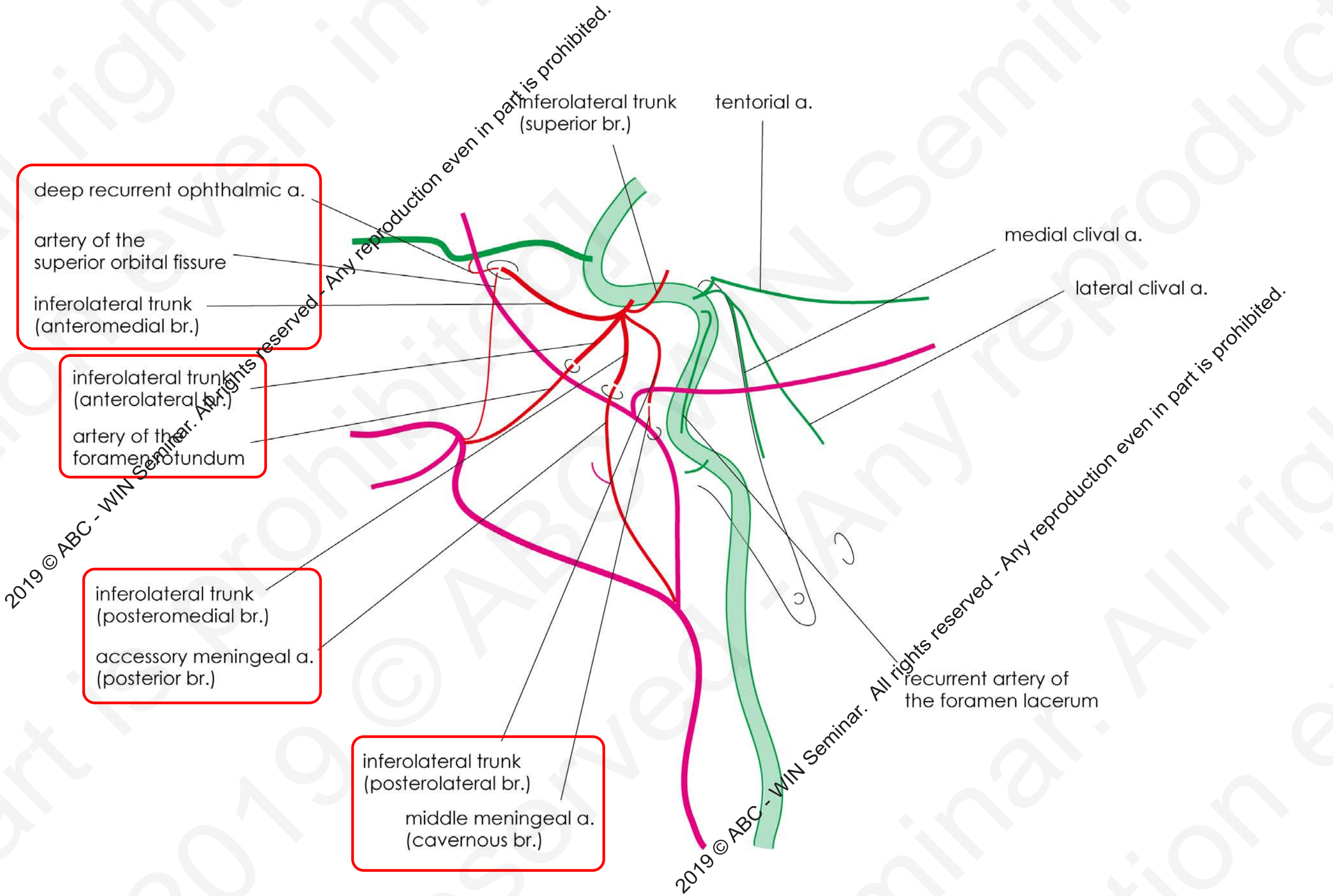
inferolateral trunk (superior br.)

tentorial a.

medial clival a.

lateral clival a.

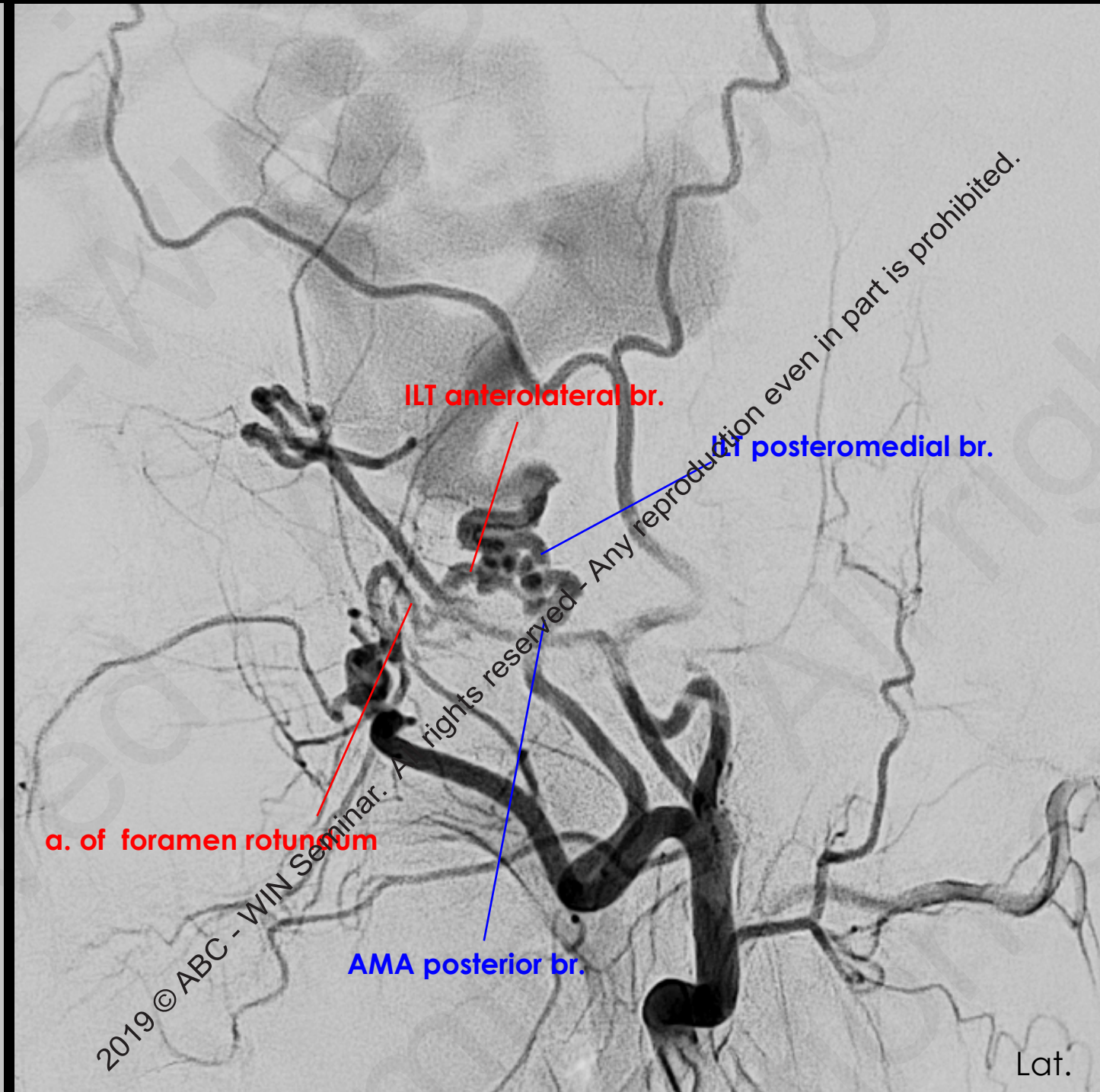
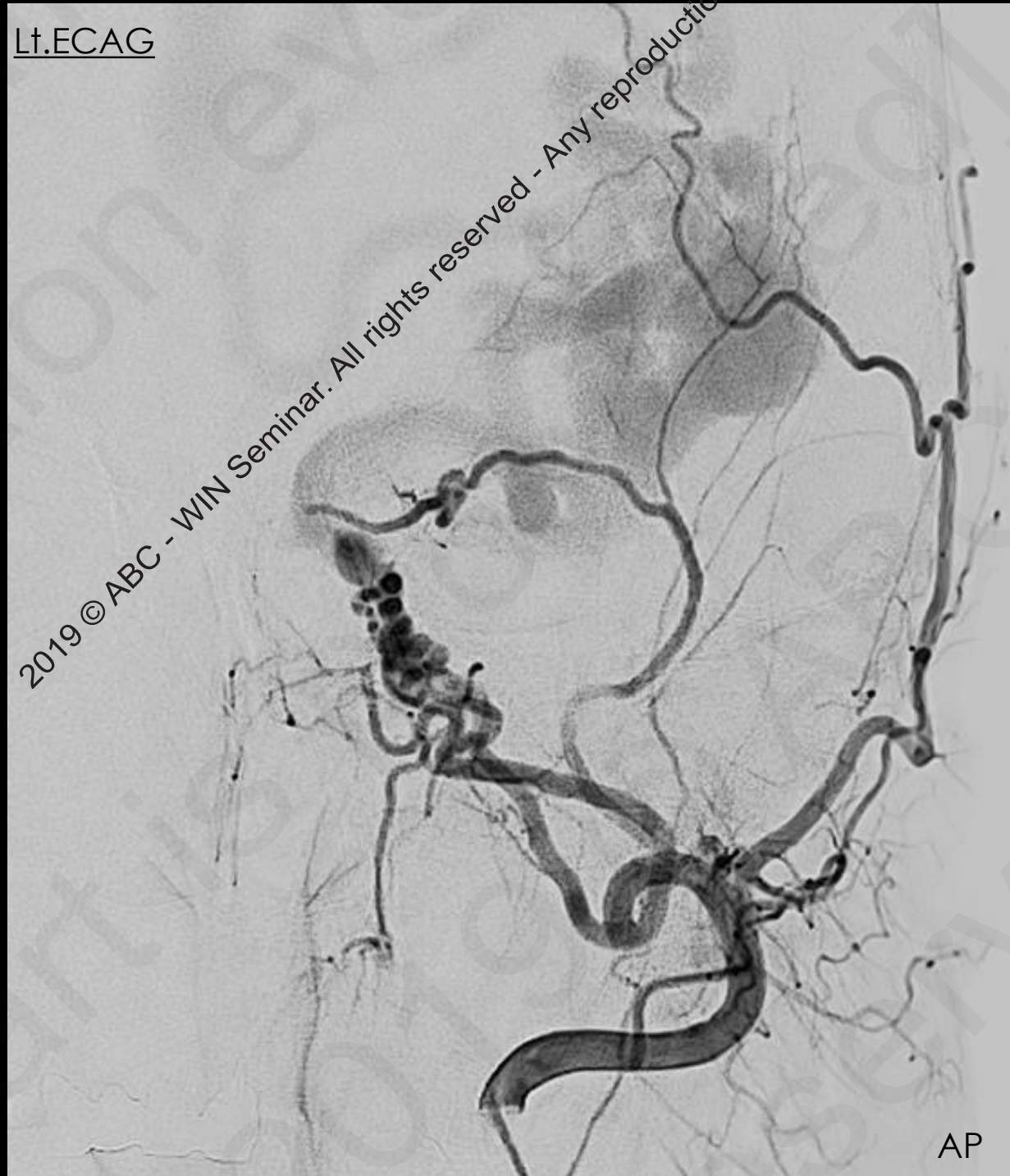recurrent artery of the foramen lacerum





**ILT anterolateral br. - artery of foramen rotundum**  
**ILT posteromedial br. - AMA posterior br.**

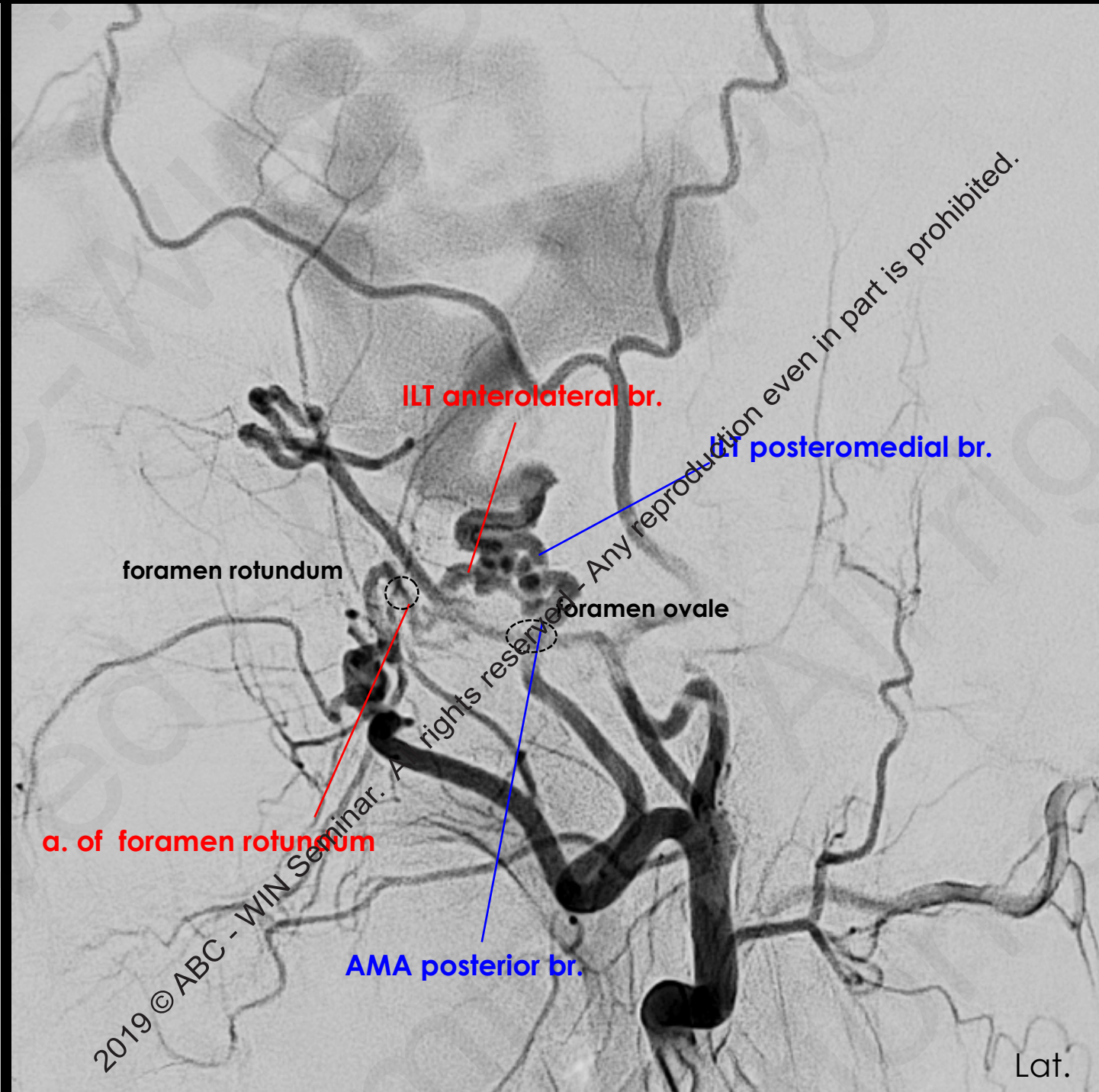
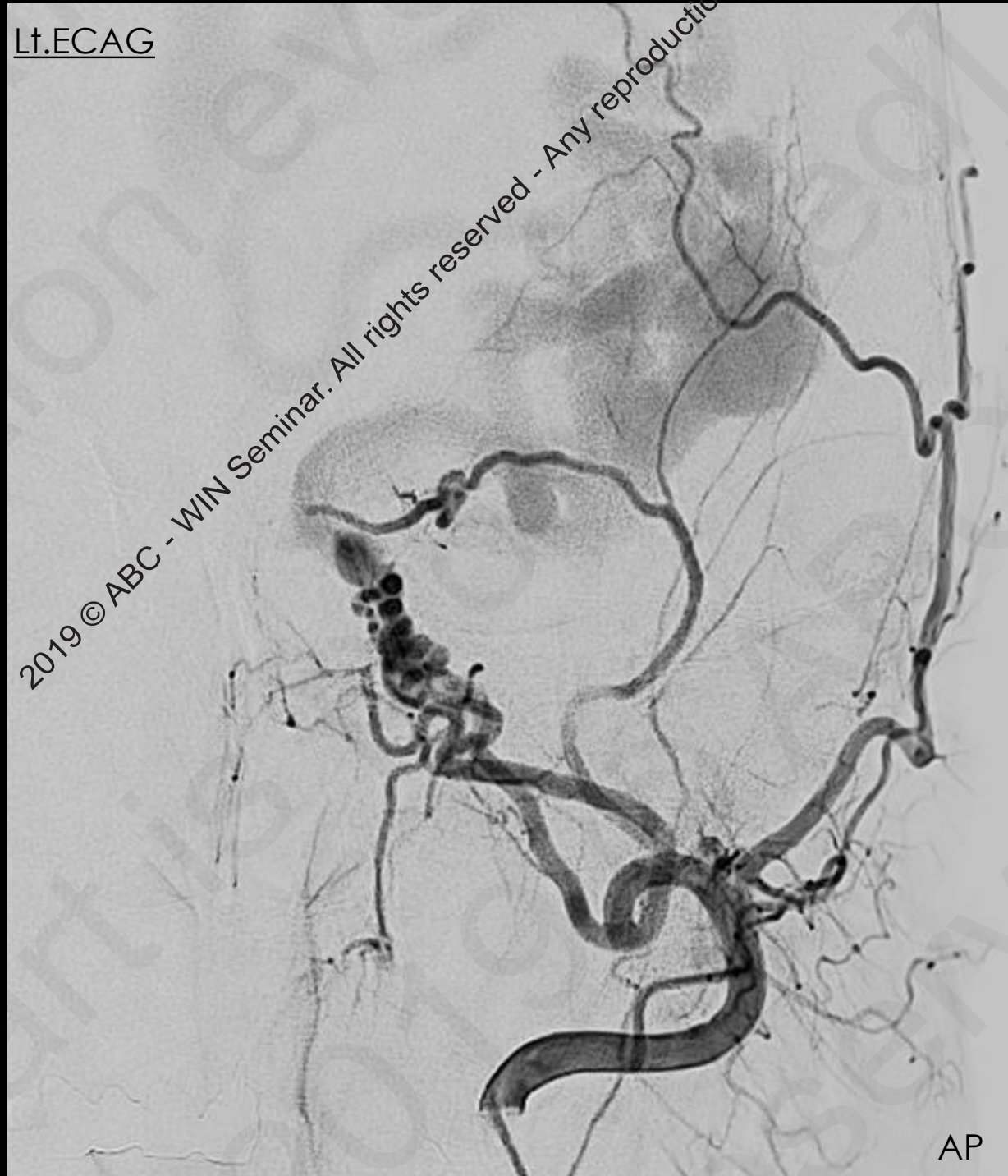
Lt.ECAG





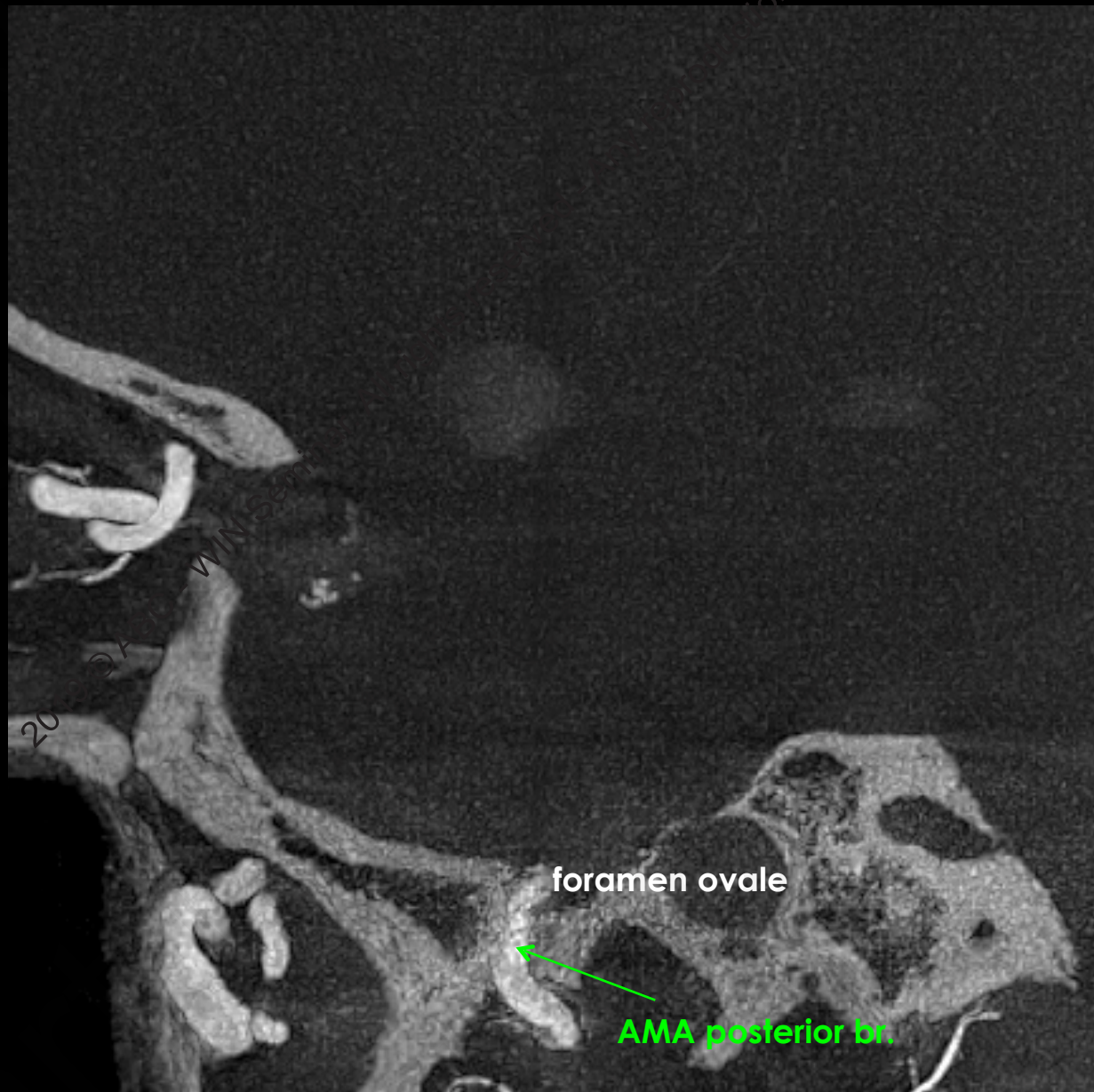# ILT anterolateral br. - artery of foramen rotundum ILT posteromedial br. - AMA posterior br.

Lt.ECAG



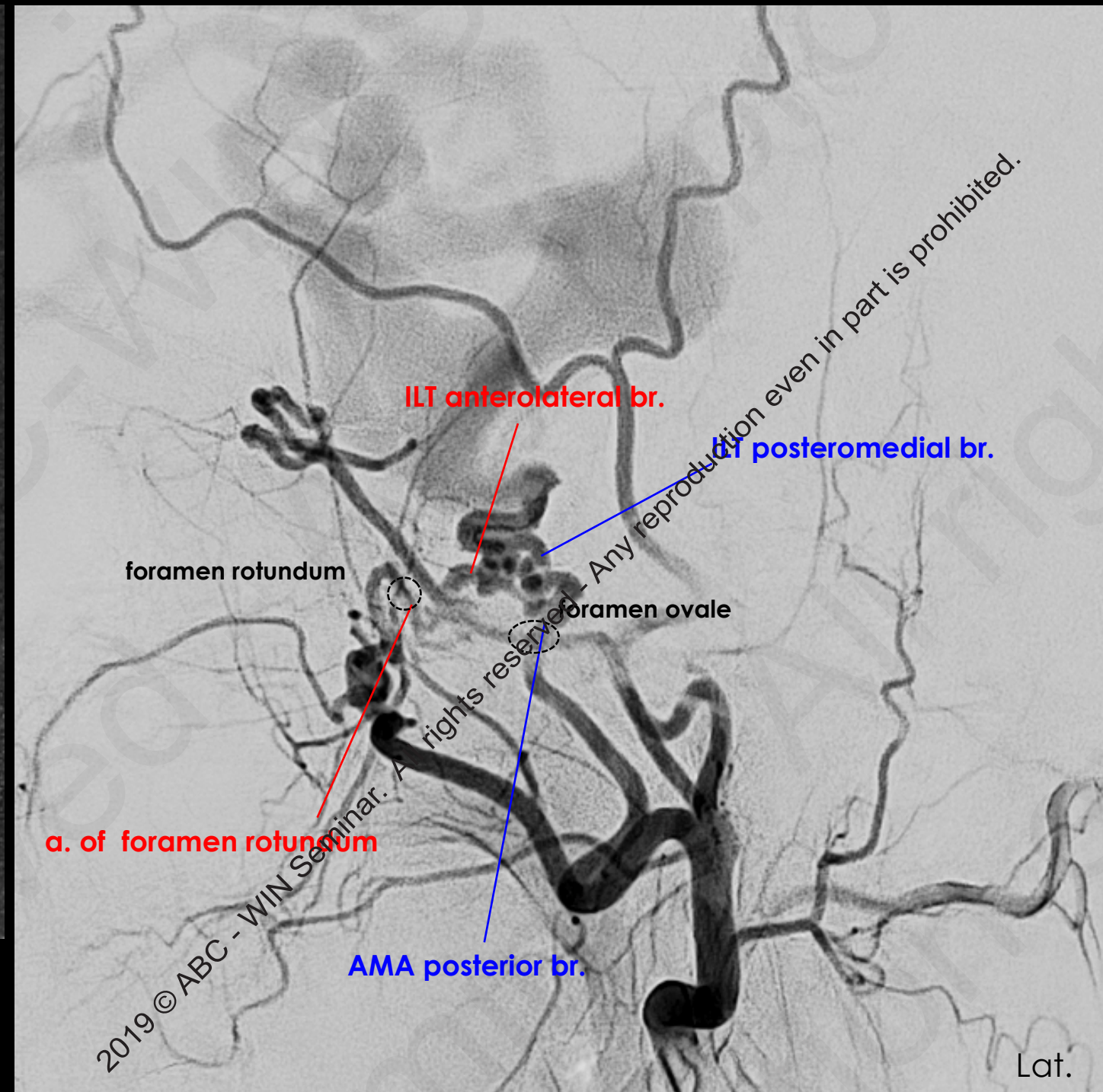


**ILT anterolateral br. - artery of foramen rotundum**  
**ILT posteromedial br. - AMA posterior br.**



foramen ovale  
AMA posterior br.

cone beam CT  
sagittal



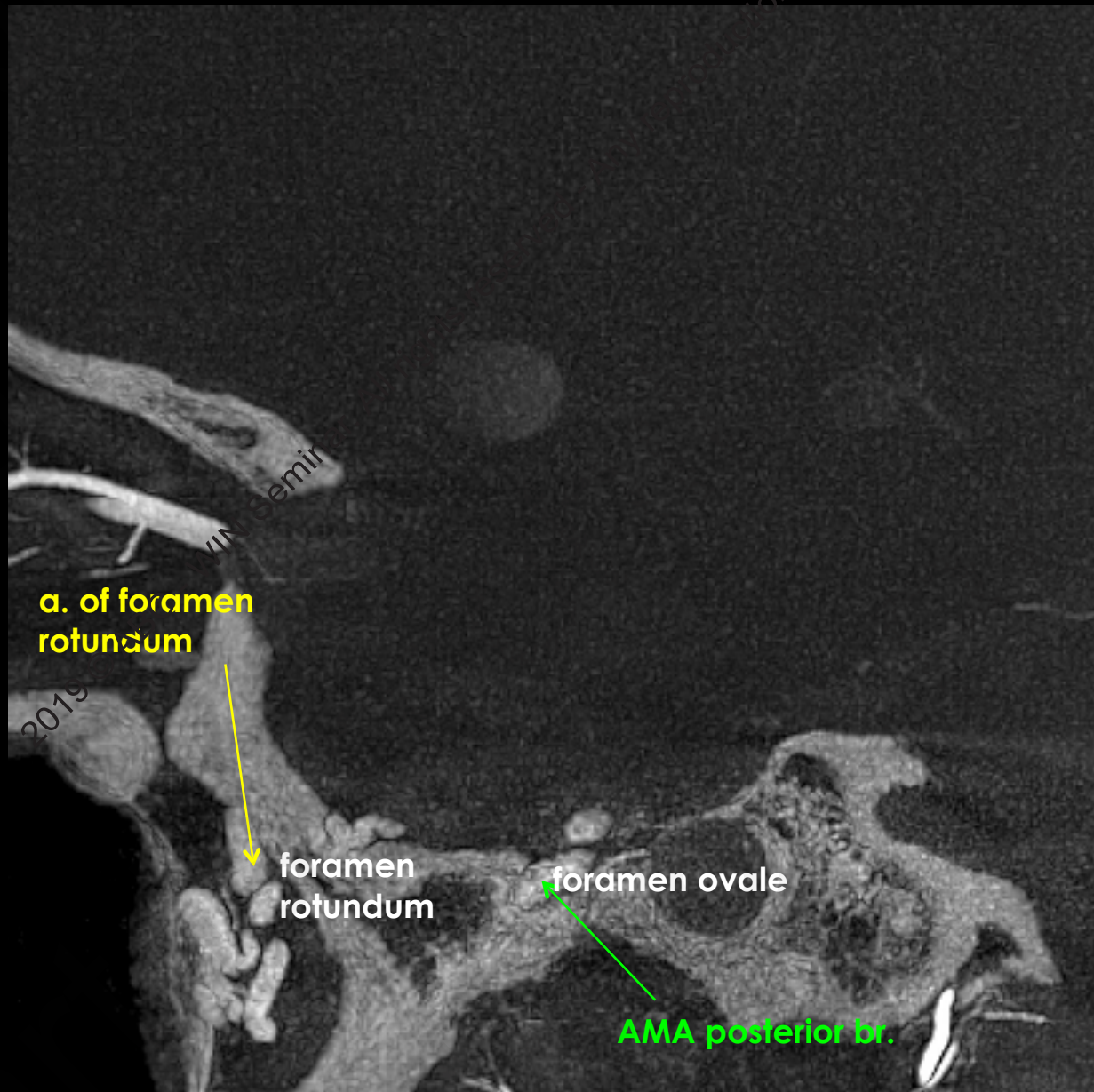
ILT anterolateral br.  
ILT posteromedial br.  
foramen rotundum  
foramen ovale  
a. of foramen rotundum  
AMA posterior br.

2019 © ABC - WIN Seminar. All rights reserved. Any reproduction even in part is prohibited.

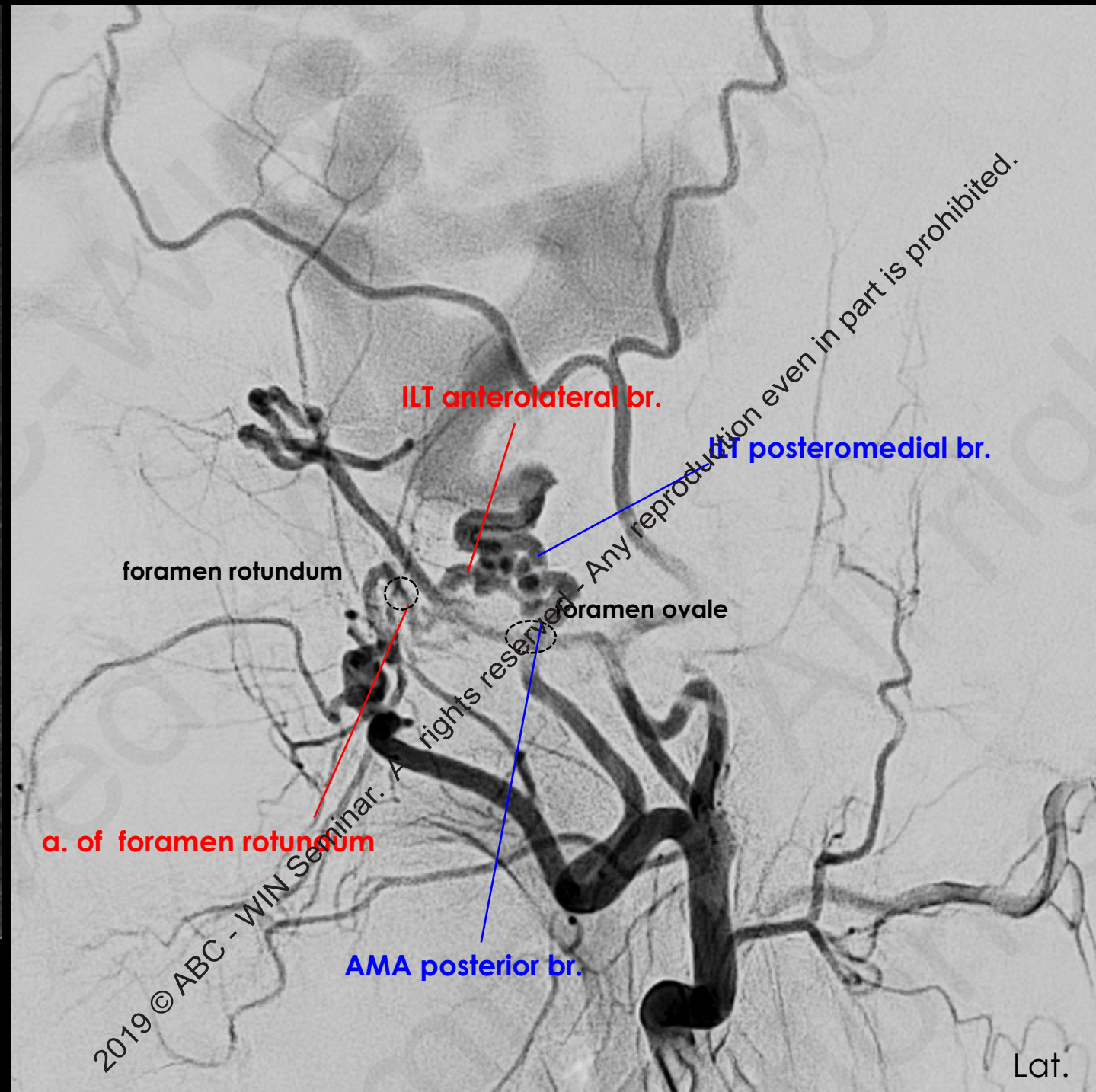
Lat.



**ILT anterolateral br. - artery of foramen rotundum**  
**ILT posteromedial br. - AMA posterior br.**



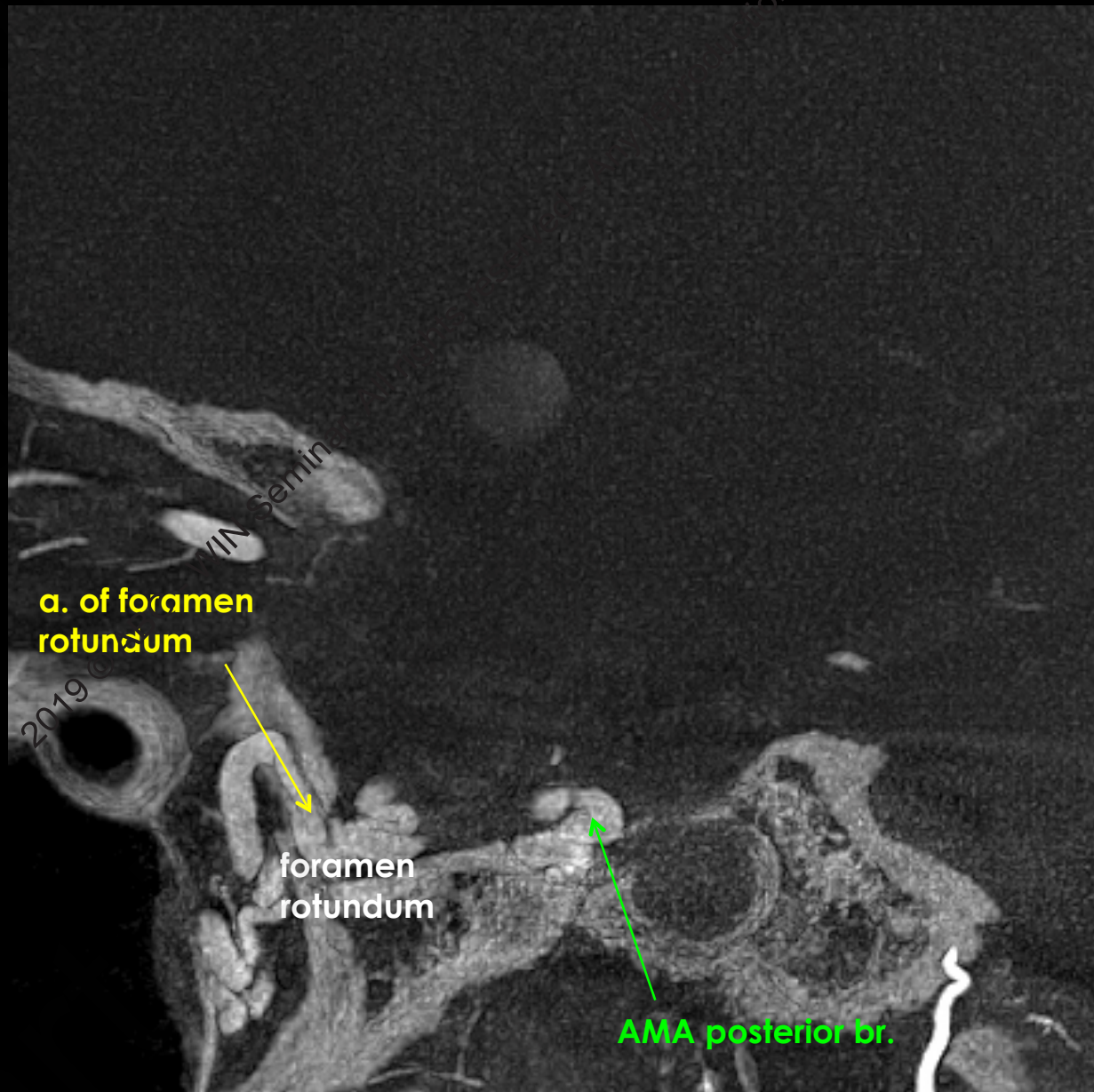
cone beam CT  
sagittal



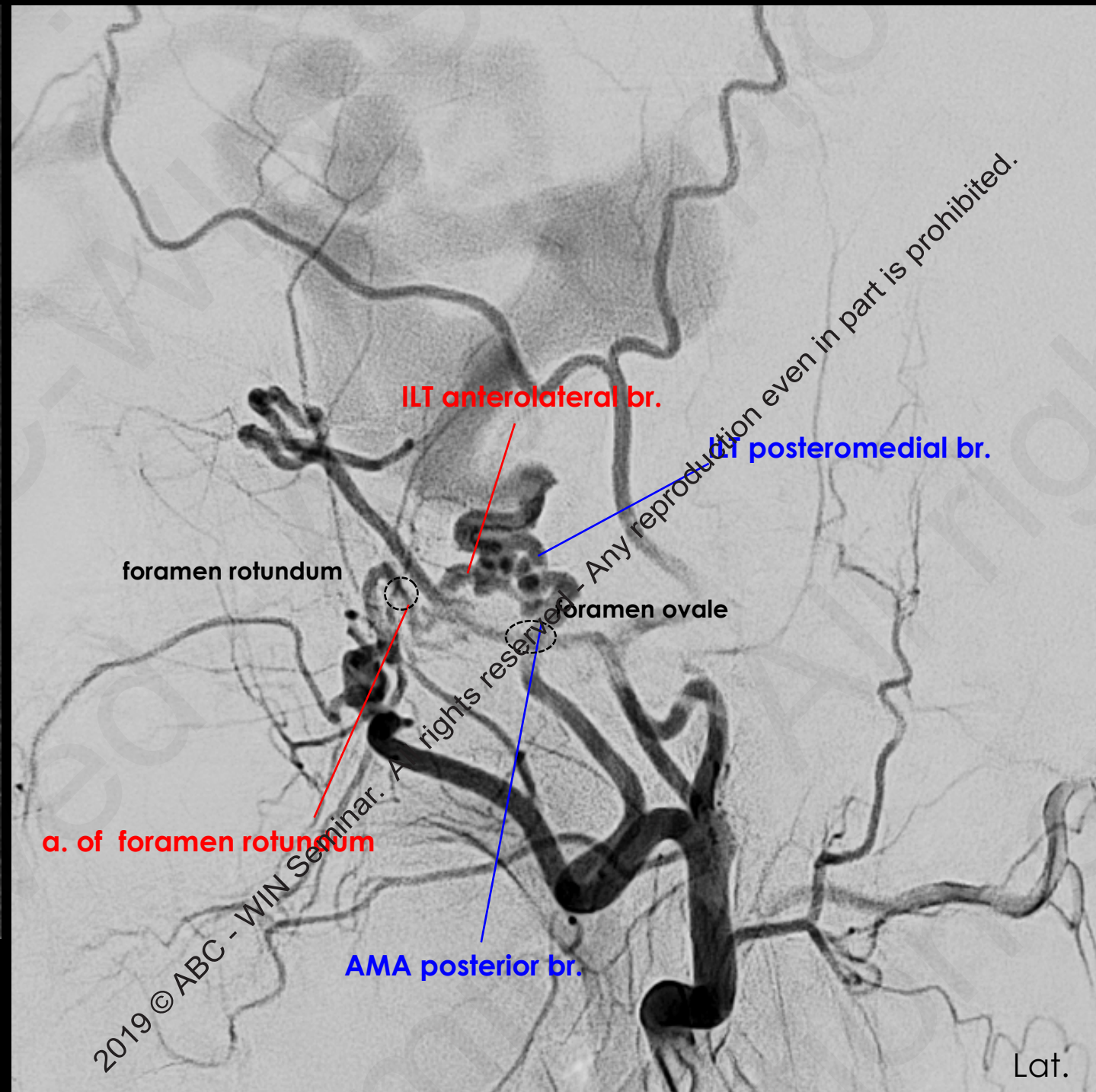
Lat.



**ILT anterolateral br. - artery of foramen rotundum**  
**ILT posteromedial br. - AMA posterior br.**



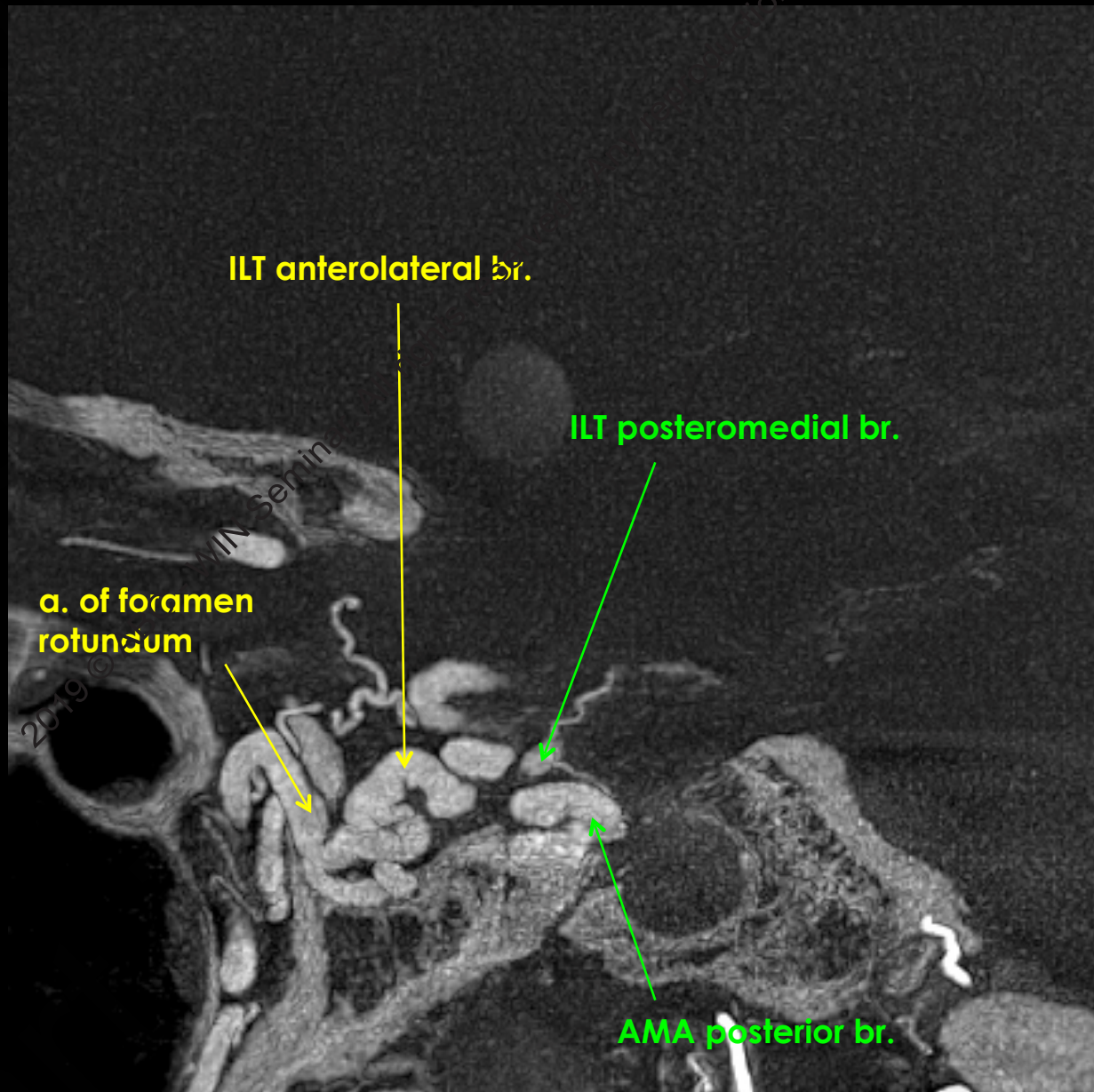
cone beam CT  
sagittal



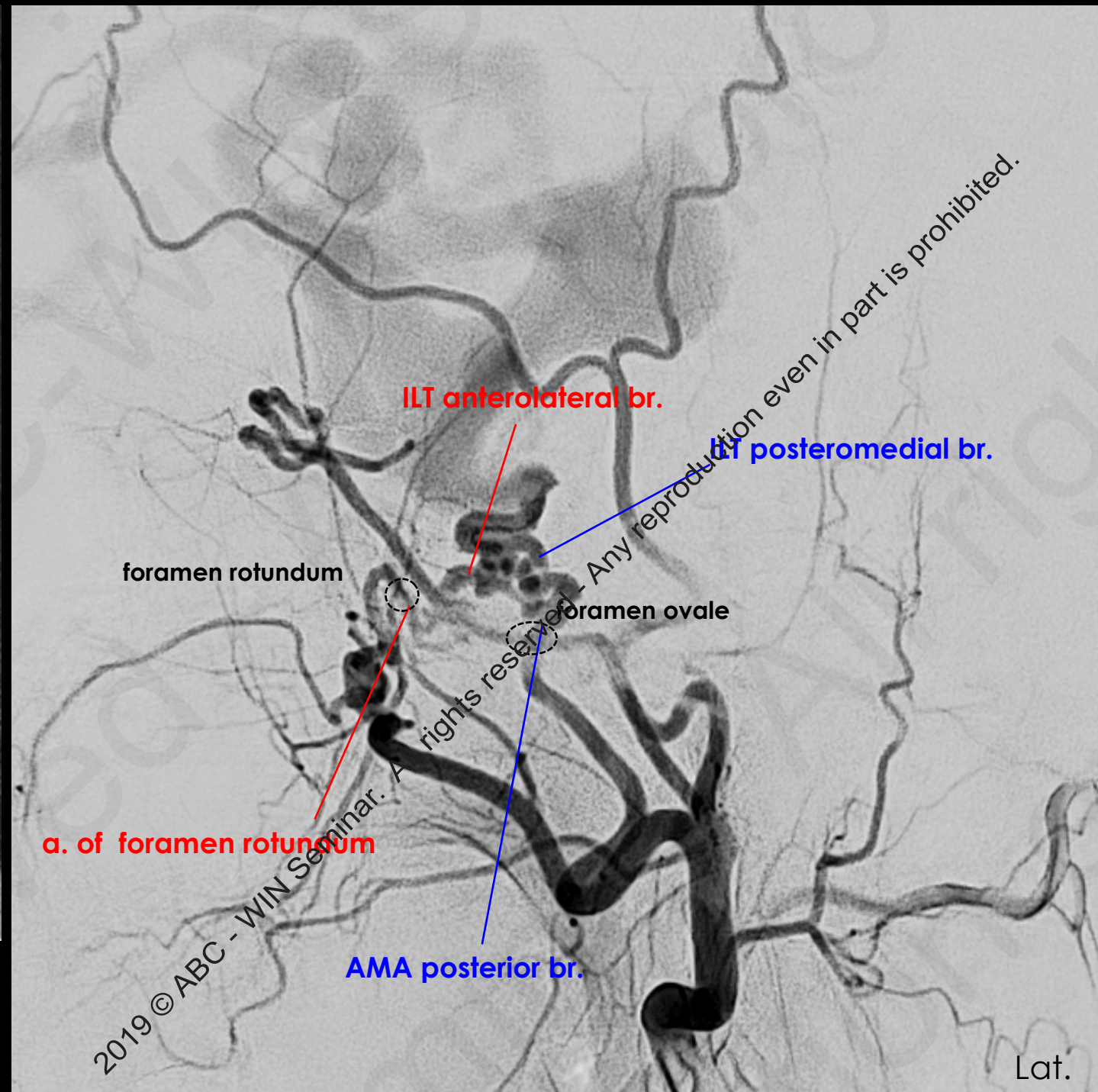
Lat.



**ILT anterolateral br. - artery of foramen rotundum**  
**ILT posteromedial br. - AMA posterior br.**



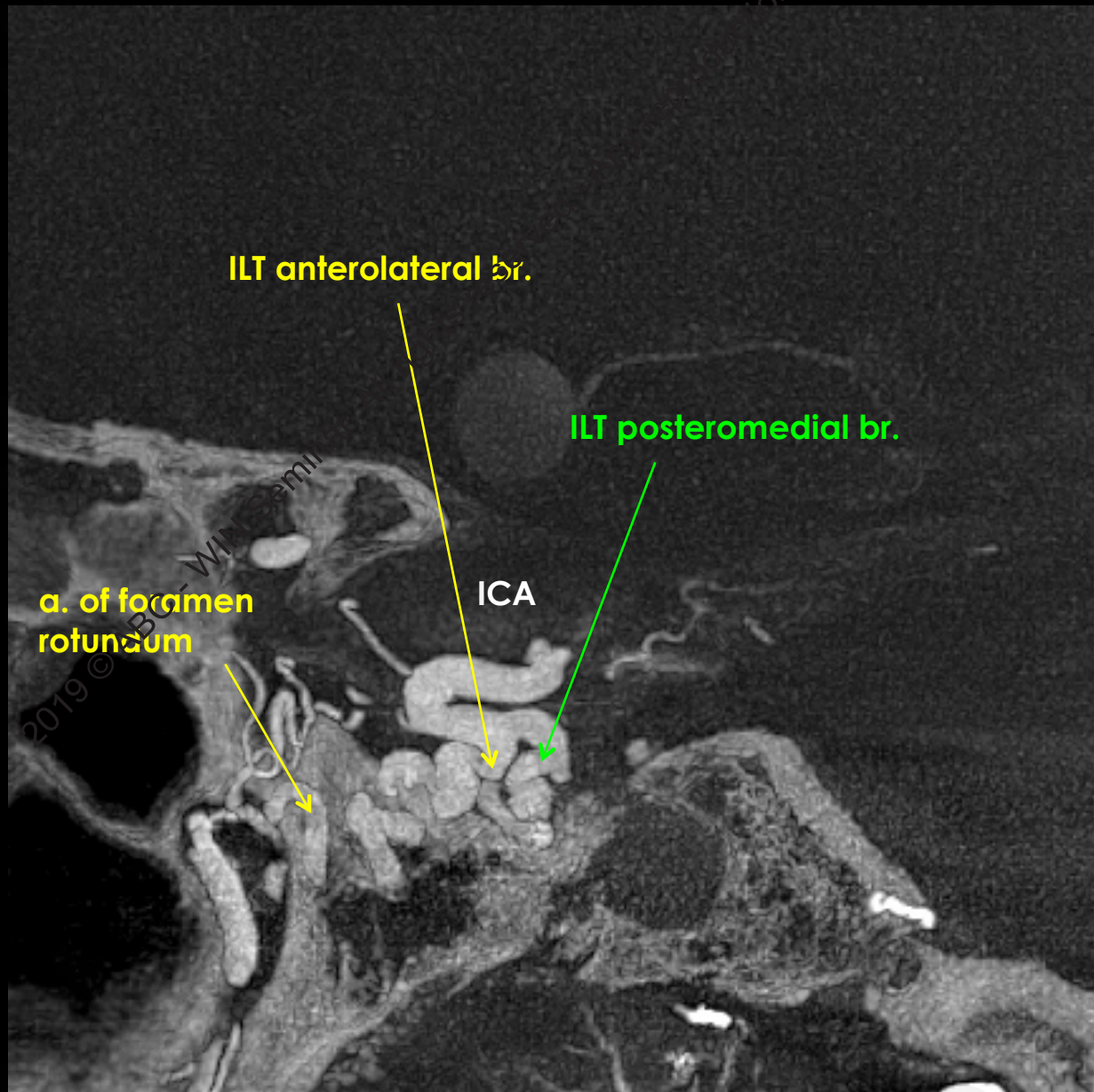
cone beam CT  
sagittal



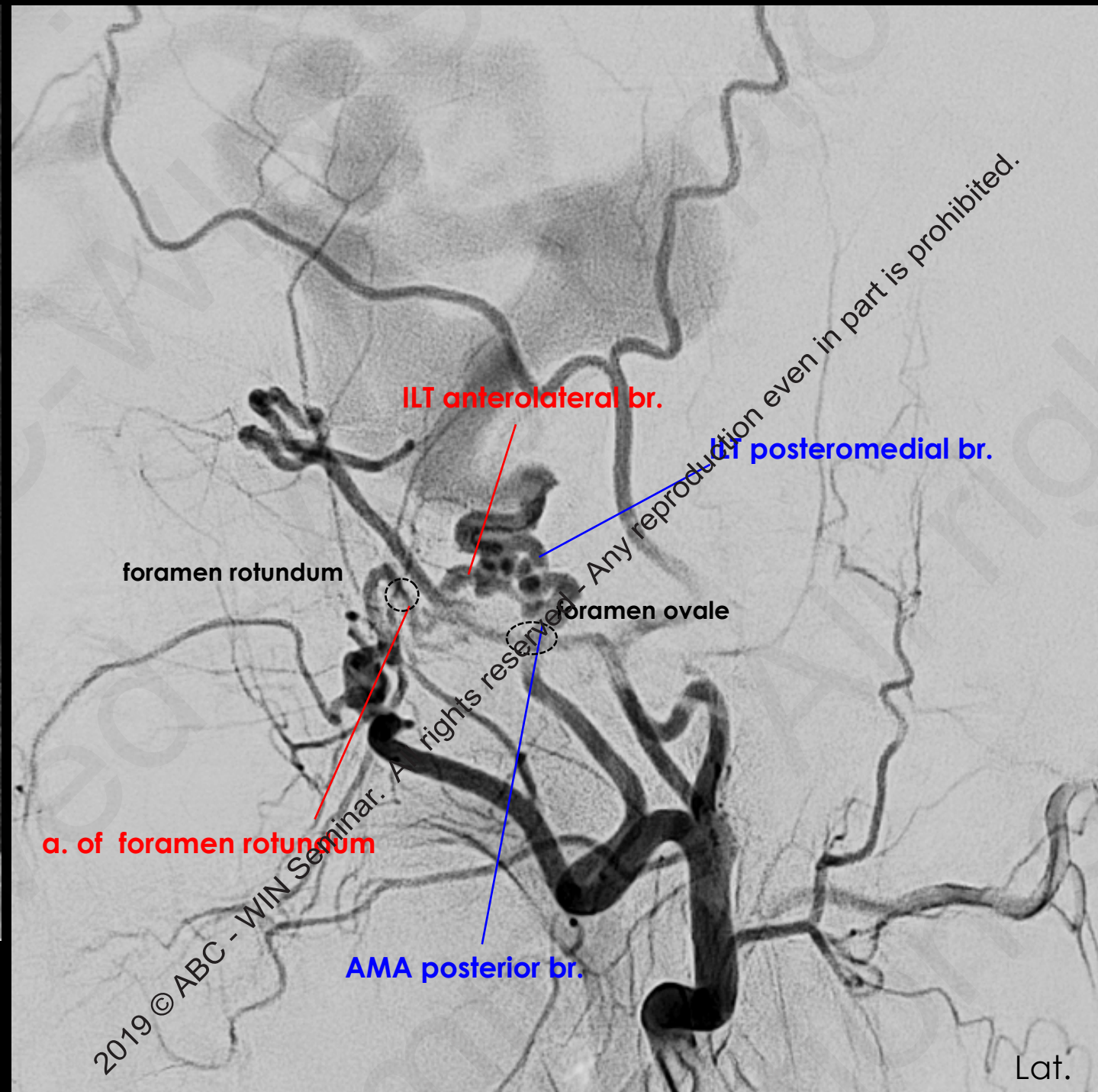
Lat.



**ILT anterolateral br. - artery of foramen rotundum**  
**ILT posteromedial br. - AMA posterior br.**

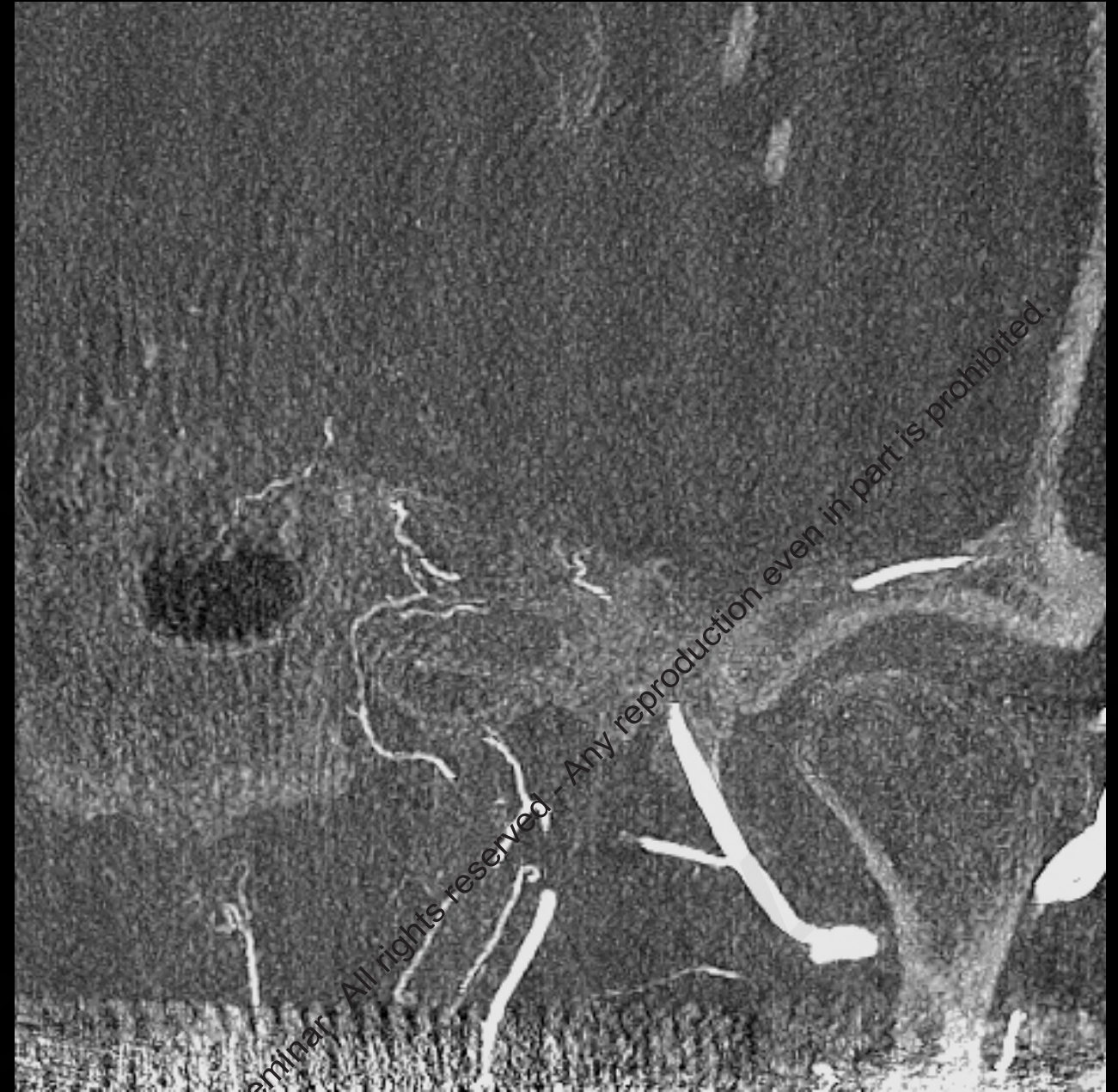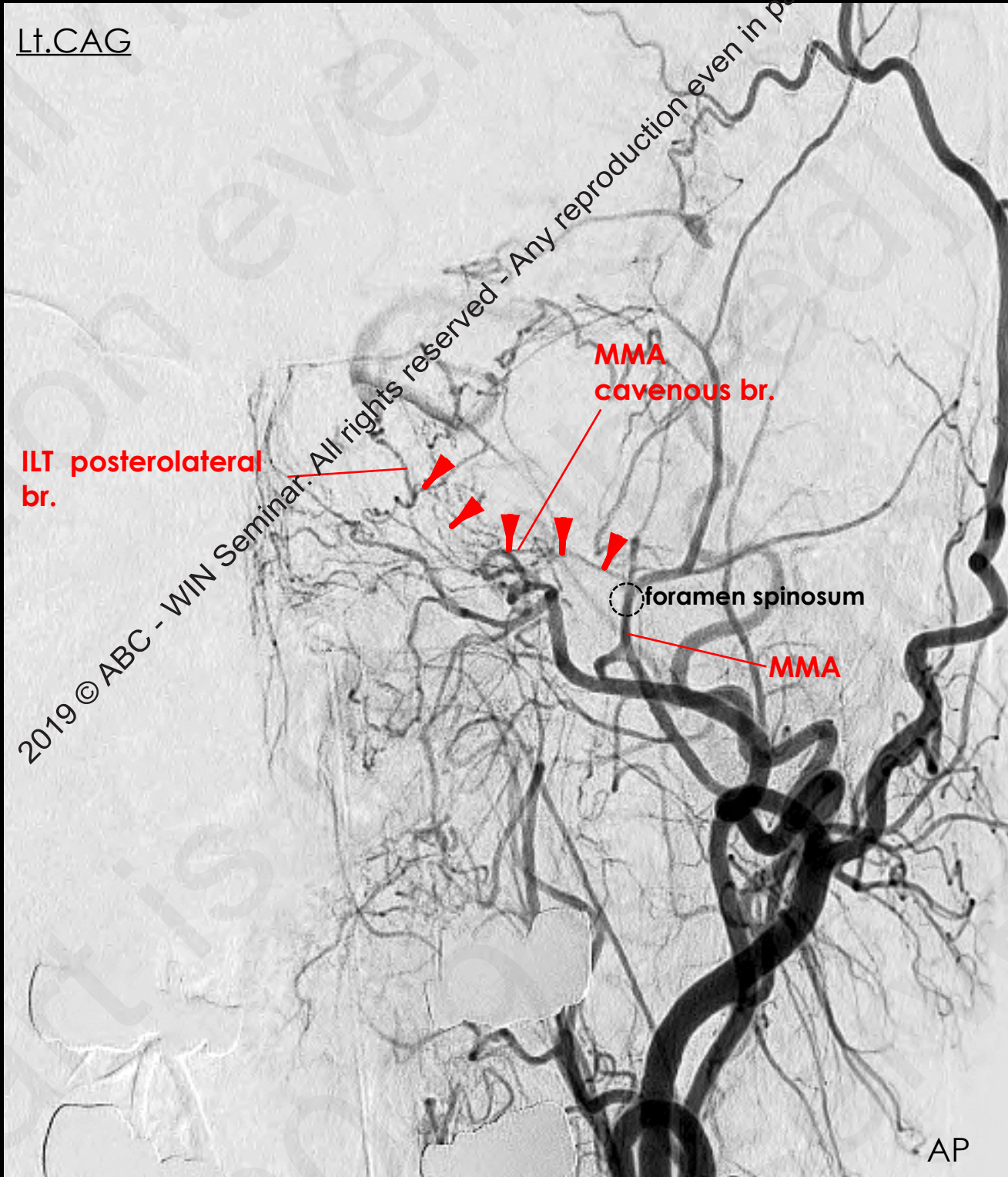


cone beam CT  
sagittal



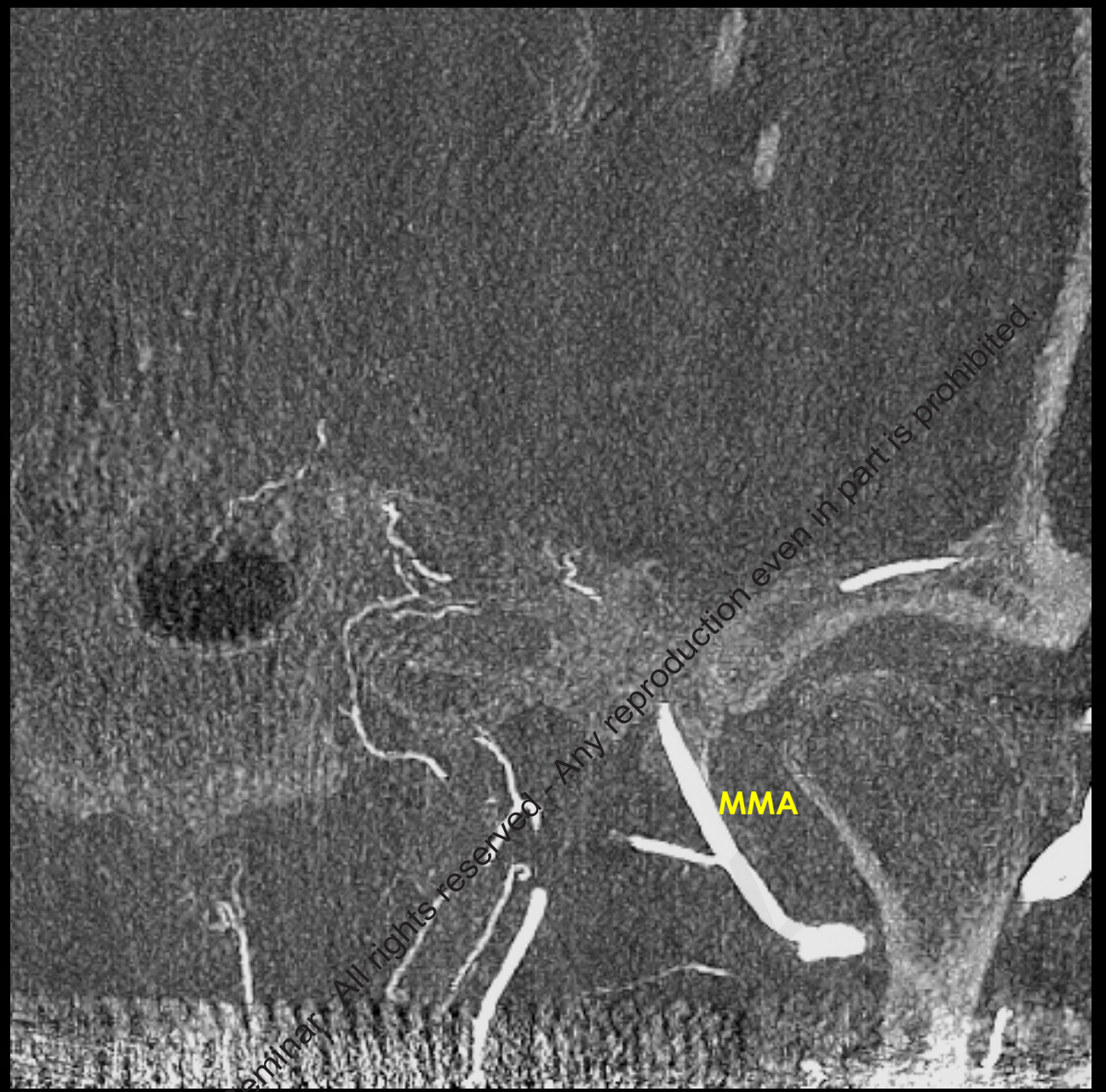
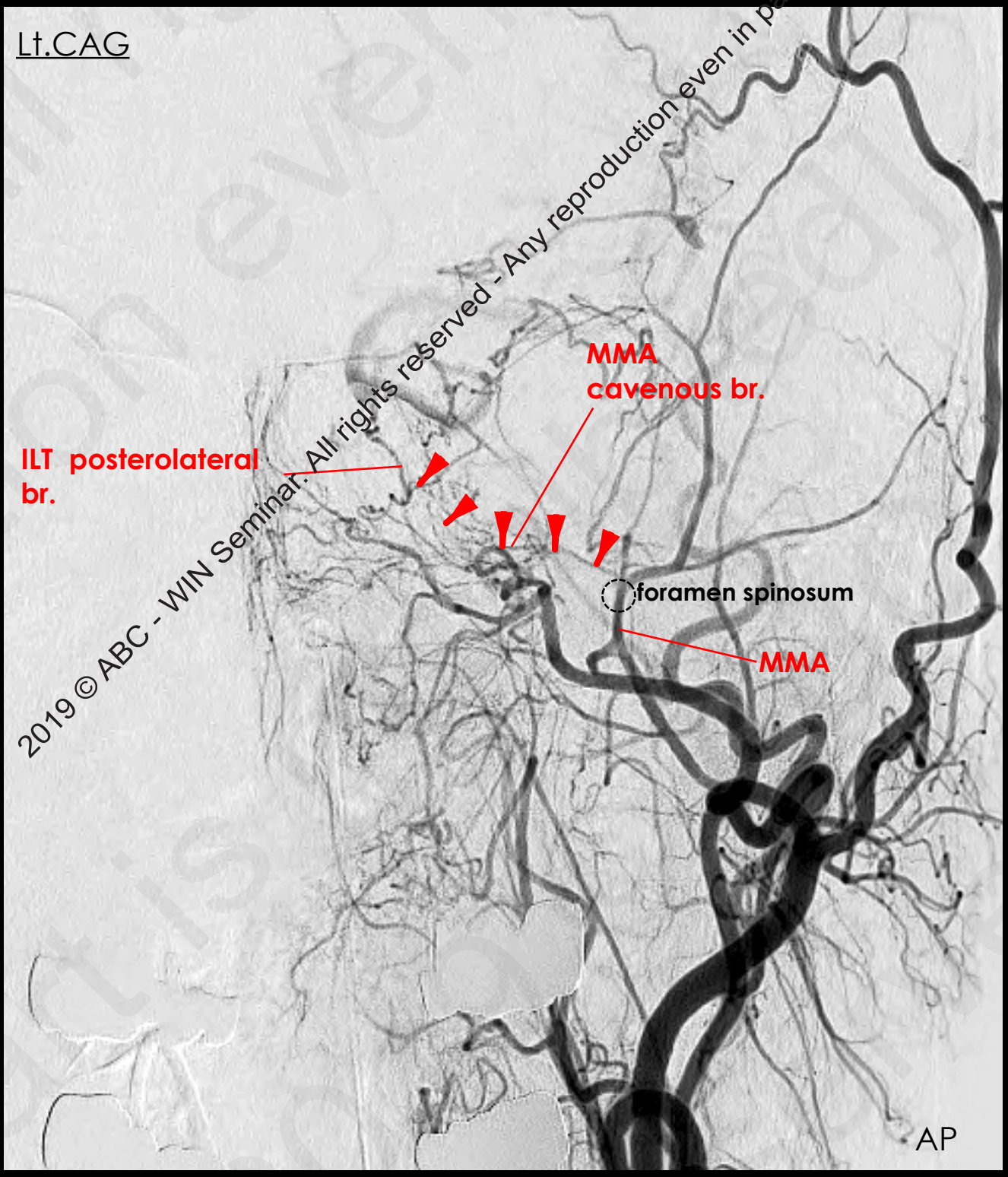


# ILT posterolateral br. – MMA cavernous br.





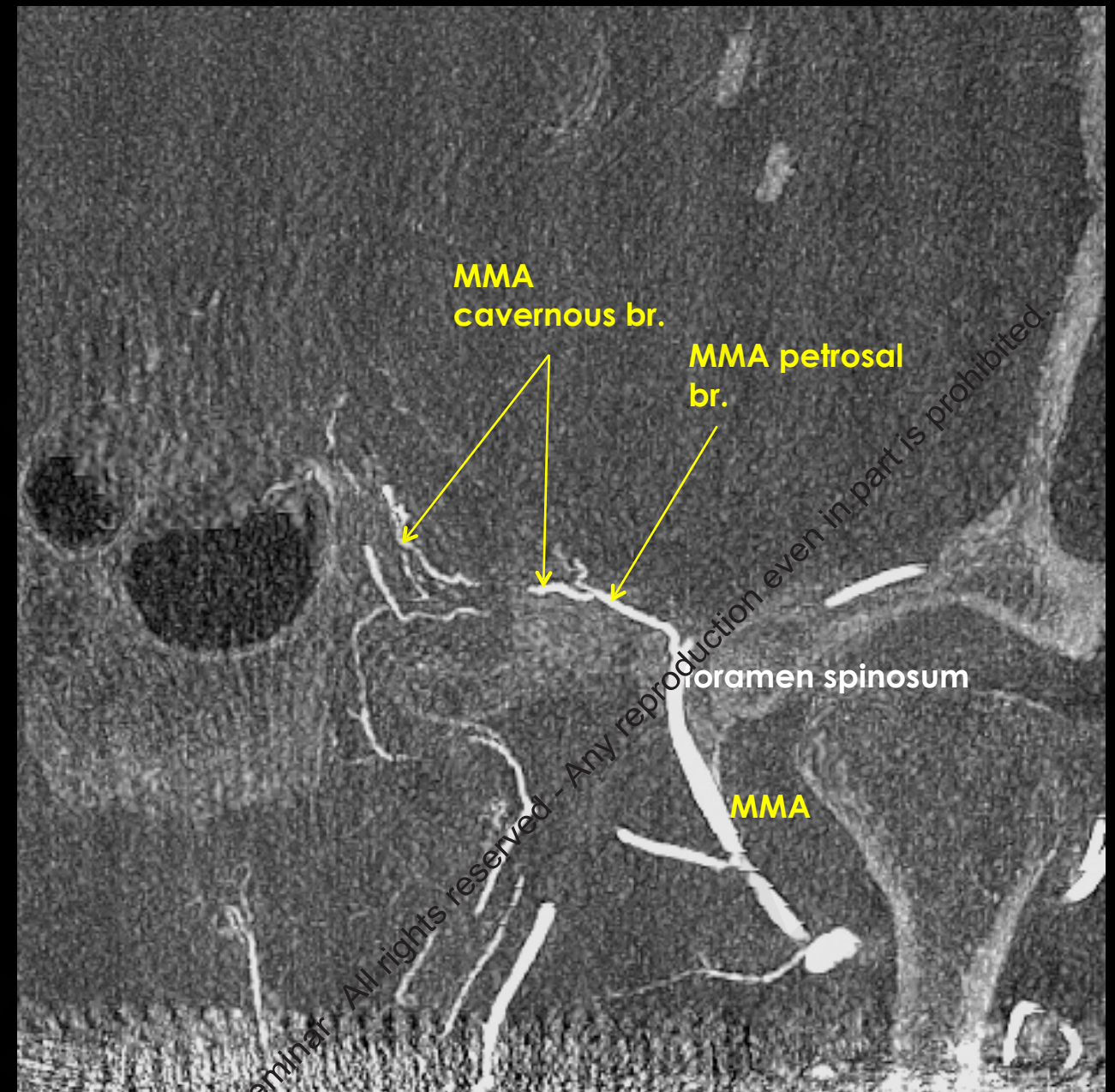
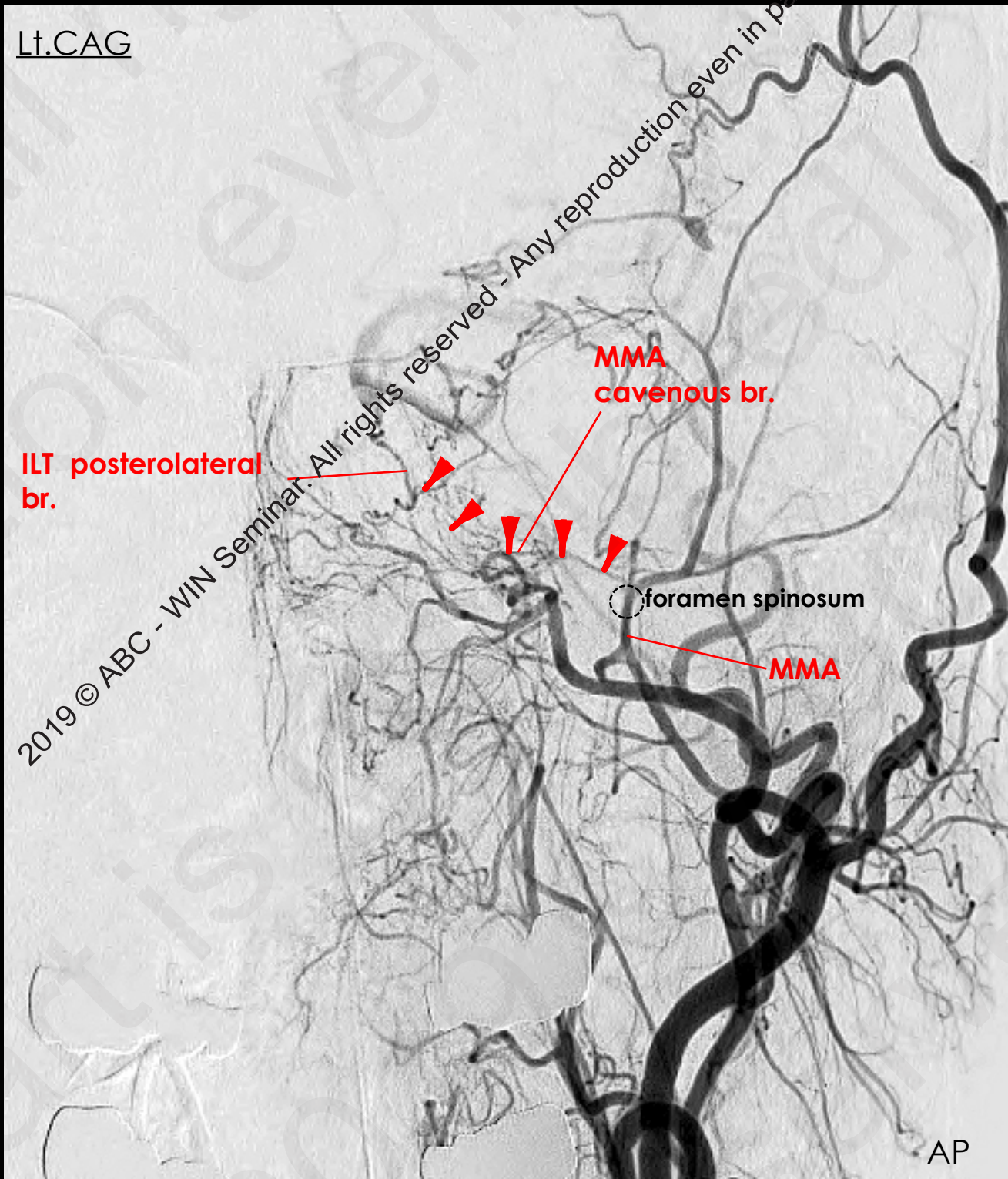
# ILT posterolateral br. – MMA cavernous br.



3DRA slab MIP  
coronal

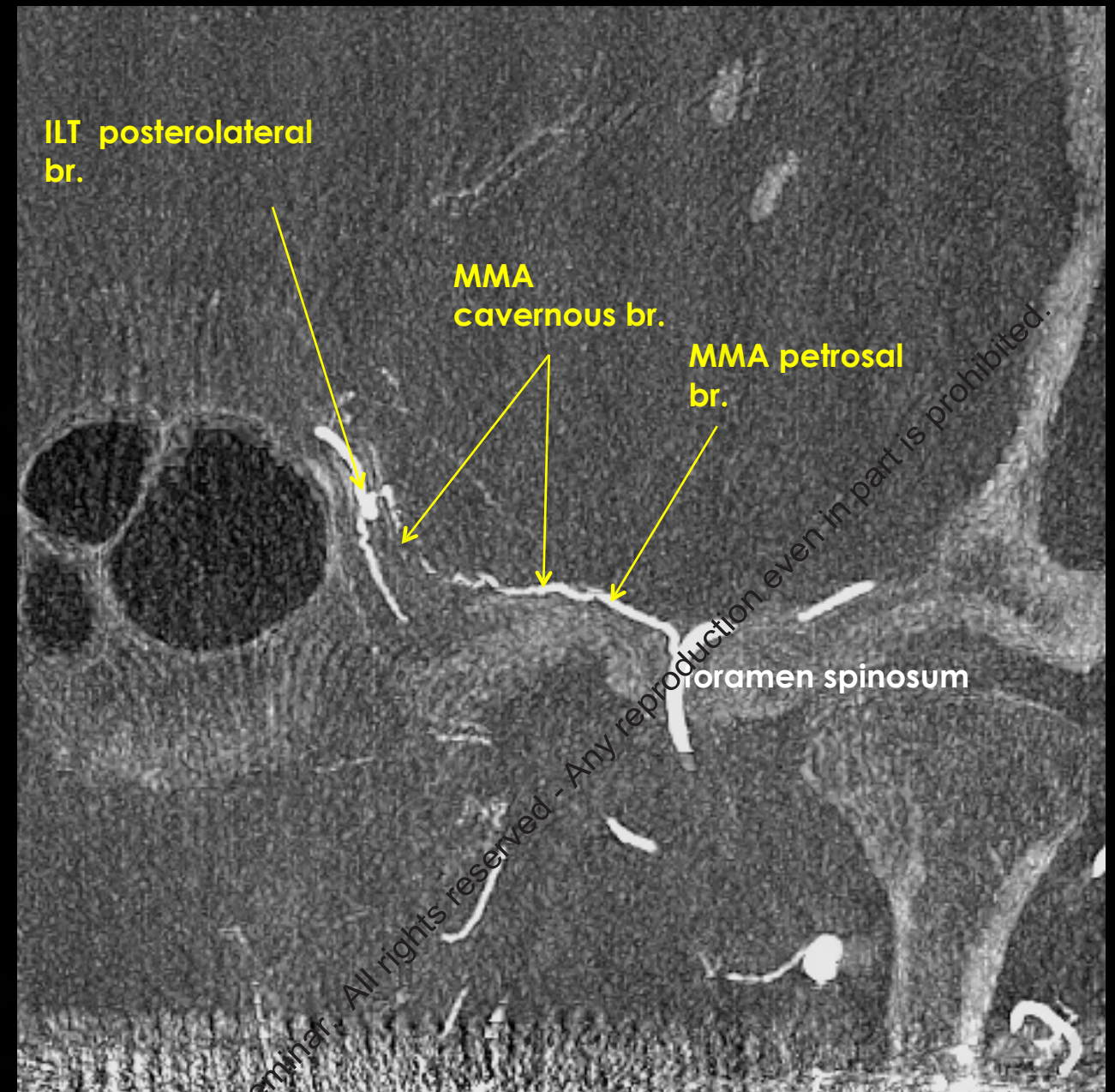
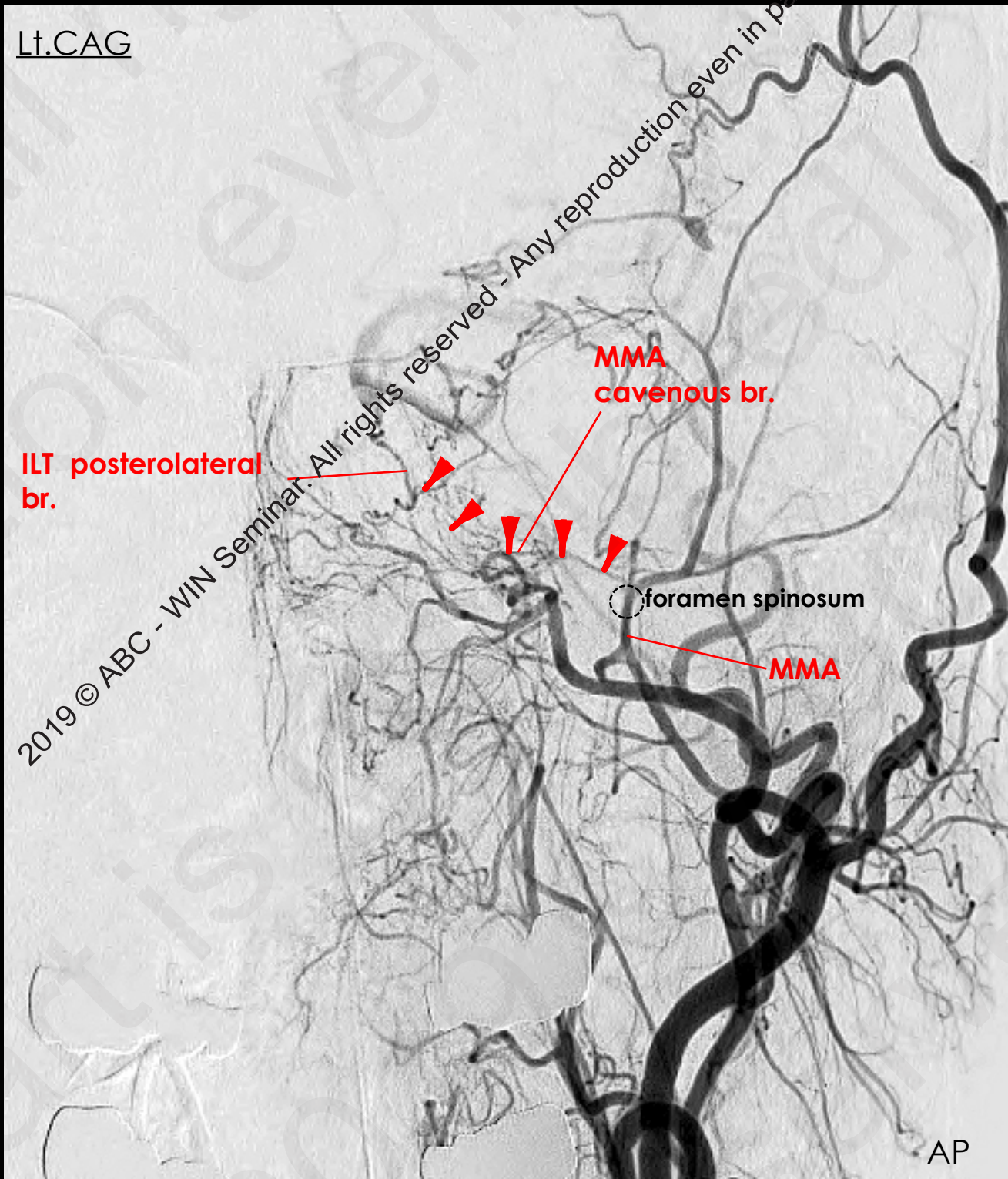


# ILT posterolateral br. – MMA cavernous br.





# ILT posterolateral br. – MMA cavernous br.





# Conclusions

---

1. Eye is composed of the tissues for vision, eye movement and gland.
2. Primitive ophthalmic artery is composed of ventral and dorsal ophthalmic arteries solely for vision.
3. Superior branch of stapedia artery works for eye movement and lacrimal gland.
4. Anatomical variations are results of complex embryological processes.
5. Embryological knowledge helps to understand the anatomical variations and contributes to safer intervention.